International Journal of Science and Research (IJSR)
ISSN (Online): 2319-7064
Index Copernicus Value (2013): 6.14 | Impact Factor (2015): 6.391

# Role of MR Spectroscopy in Evaluation of Various Ring Enhancing Lesions in Brain

**Dr. Jernail Singh Bava[1], Dr. Ashwini Sankhe[2], Dr. Swapnil Patil[3]**

[1]Professor, Department of Radiology, LTMMC and GH – Sion, Mumbai, Maharashtra, India

[2]Assistant professor, Department of Radiology, LTMMC and GH – Sion, Mumbai, Maharashtra, India

[3]Resident, Department of Radiology, LTMMC and GH – Sion, Maharashtra, India

**Abstract:** ***A wide range of etiologies may present as multiple ring-enhancing lesions in brain, including infectious, neoplastic, vascular or inflammatory etiology. MR spectroscopy is a potential tool which images at the molecular level analyzing the chemical composition of tissue metabolites like NAA, creatine, choline and lipid etc. Another advantage of MR spectroscopy is that, it can be added as a sequence to routine MRI sequences. We present a case study of 50 patients, presenting with ring enhancing lesions in brain, differentiating them based on various metabolites using MR spectroscopy as an adjuvant to conventional MRI.***

**Keywords:** Spectroscopy, ring enhancing lesions, metabolites, peaks, neuroimaging

## 1. Introduction

Ring enhancing lesions are one of the most common neuroimaging abnormalities encountered by the radiologists. Various imaging modalities, like computed tomography (CT) and magnetic resonance imaging (MRI) are used to detect these lesions. A wide range of etiologies may present as cerebral multiple ring-enhancing lesion [1]. Clinically, they present as visual impairment, focal neurological deficit, recurrent seizures, and raised intracranial pressure (severe headache, vomiting and papilledema). If vasogenic edema is severe,patients may develop loss of sensorium and posturing of limbs because of transtentorial brain herniation. Intractable headache, focal neurological deficits and vision loss are the long-term sequelae [2].

Diseases causing multiple ring-enhancing lesions of the brain can be infectious, neoplastic, vascular or inflammatory in etiology. Many types of primary and secondary brain neoplasms, such as low-grade and high grade gliomas, lymphomas and brain metastases can also present as multiple ring-enhancing lesions. Many non-neoplastic neurological disorders canmimic brain neoplasms on neuroimaging. These diseases include cysticercosis, tuberculosis, pyogenic abscess, toxoplasmosis, demyelinating disorders, fungal infections, neurosyphilis, sarcoidosis, radiation encephalopathy, Behcet disease, cerebral venous thrombosis as well as several other vasculitic disorders. The differential diagnosis of multiple ring-enhancing lesions depends on the age and the immune status of the patient. In the immunocompetent host, malignancies (both primary and metastatic) and pyogenic abscesses remain the most likely diagnoses in patients with large-sized lesions. Abscesses caused by atypical microorganisms and demyelinating disease should also be considered in the differential diagnosis of multiple enhancing lesions of the brain. In tropical countries, cysticercus granuloma frequently needs to be differentiated from intracranial tuberculoma. Magnetic resonance spectroscopy (MRS) is a non invasive physiological imaging that measures absolute and relative levels of various brain tissue metabolites.

## 2. Material and Methods

This study was a prospective observational study. The study included 50 patients referred to the department of Radiodiagnosis in LTMMC and GH – Sion, Mumbai with clinically suspected ring enhancing lesions or those detected on contrast enhanced CT scan in the period of 3yrs. MRI was done on Philips achieva series 3T machine using phase array brain coil. Contrast study was done (by intravenously injecting gadolinium based contrast agent) according to body weight (0.1mmol / kg). Routine sequences like T1, T2, FLAIR, DWI were taken along with 2D PRESS with TE of 35 and 144. Various ring enhancing lesions were classified according their etiology, metabolites like lipid, lactate, choline, amino acids, alanine, acetate, myo-inositol and reduced NAA.

## 3. Results

Fifty patients were evaluated, whose age group ranged from 2 to 75 years. The highest incidence of these ring enhancing lesions were found in 11 – 20 years age group accounting for 28% of cases and least was seen in age group of > 61 years constituting 2%.

**Table 1:** Sex wise distribution of various ring enhancing lesions.

| Sex | Number of cases | Percentage |
|---|---|---|
| Male | 27 | 54 % |
| Female | 23 | 46 % |

Fifty patients were evaluated of which 27 (54%) were males and 23 (46%) were females


Licensed Under Creative Commons Attribution CC BY

**Table 2:** Sexwise Incidence of Ring Enhancing lesions

| Lesions | Male | Female | Total |
|---|---|---|---|
| Neurocysticercosis | 12 | 5 | 17 |
| Tuberculoma | 9 | 9 | 18 |
| Abscess | 2 | 4 | 6 |
| Metastasis | 2 | 1 | 3 |
| Primary brain tumour | 2 | 3 | 5 |
| Toxoplasma | 0 | 1 | 1 |

Out of the 50 patients that we evaluated, tuberculomas (36%) was the most common pathology followed by NCC (34 %), Abscesses (12%), primary brain tumour (10%) metastasis (6%), and toxoplasma infection (2%). (Table 3)

**Table 3:** Incidence of Various Ring Enhancing lesion

| Lesions | No. of cases | Percentage |
|---|---|---|
| Neurocysticercosis | 17 | 34 % |
| Tuberculoma | 18 | 36 % |
| Abscess | 6 | 12 % |
| Metastasis | 3 | 6 % |
| Primary brain tumour | 5 | 10 % |
| Toxoplasma | 1 | 2 % |

Out of the fifty patients that were evaluated spectroscopy was done in all the cases. The spectroscopy finding revealed - Lipid peak was observed in 25 cases, Choline in 24 cases, Lactate in 14 cases, reduced NAA peak was noted in 15 cases. Other peaks were amino acids peak in 3 cases, alanine peak in 6 cases, acetate peak in 1 case and myo-inositol peak in 1 case. (Table 4)

**Table 4:** Various Metabolite Peaks Noted in Various Ring Enhancing Lesions

| Metabolic peaks | No. of cases | Percentage |
|---|---|---|
| Lipid | 25 | 50 % |
| Lactate | 15 | 30 % |
| Choline | 24 | 48 % |
| Amino Acids | 3 | 6 % |
| Alanine | 5 | 10 % |
| Acetate | 1 | 2 % |
| Myo-inositol | 1 | 2 % |
| Reduced NAA | 15 | 30 % |

## 4. Discussion

Magnetic resonance imaging is a highly accurate, noninvasive, multiplanar method with better inherent contrast for demonstrating any abnormal lesion accurately. MRI along with MRS provides an accurate and early assessment of brain changes in various ring enhancing lesions, thus leading to accurate diagnosis and introduction of early treatment. Animesh, Saha, Sajal Kumar Ghosh et al. conducted a study on 72 patients, of which headache was the most common symptom that was documented in patients with ring enhancing lesions (66.7 %) followed by vomiting (54.1 %) [3].

Out of fifty patients evaluated, tuberculomas were seen in 18 (36%) of cases. Among the 18 cases (males = 9 : females = 9). Single lesions were noted in 2 cases. Many of these lesions were seen as conglomerate lesions which were hypointense on T1 and hypointense or hyperintense on T2. The lesions showed a nodular or irregular ring like enhancement. MRS showed a Lipid peak in 17 (94.1%) cases and it plays an important role in identification of tuberculomas from other infective granulomas[4]. Lactate peak was also seen in 8 cases (44.4%).

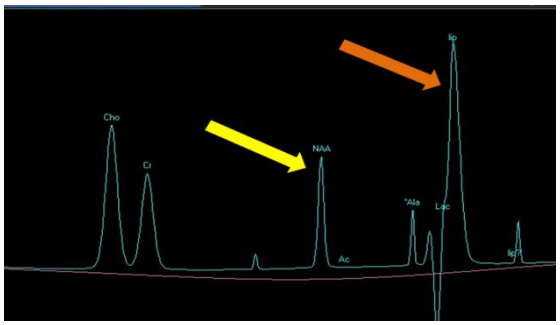


**Figure 1:** Lipid peak in tuberculoma (orange arrow) with reduced NAA (yellow arrow)

Seizure was the most common presenting symptom which was seen in all the cases of Neurocysticercosis (NCC). Scolex was identified in 8 cases which appeared as a hypointense focus on T2WI. Moderate to intense and regular ring enhancement with surrounding perilesional edema was seen in most of the cases. Alanine peak was noted in 5 cases (29.4 %), amino acid peak was seen in 3 cases (17.6%), whereas one case showed an acetate peak. MRS findings of cysticercosis include a combination of elevated levels of lactate, alanine, succinate and choline and reduced levels of NAA and creatine [5].

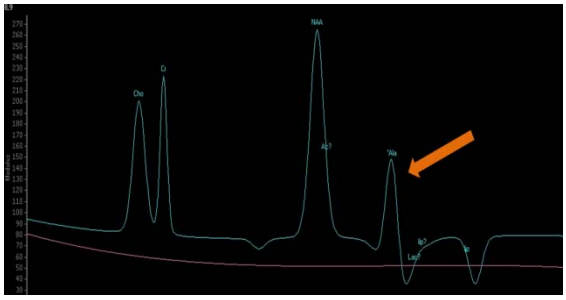


**Figure 2:** MRS showing alanine peaks in NCC

Abscesses appeared hypointense on T1 weighted images with a hyperintense rim in 4 patients (66.67 %), whereas all of them appeared hyperintense on T2WI showing complete or partial diffusion restriction and MRS showed Lactate peak in all 6 cases suggesting anaerobic glycolysis with 5 (83%) of the cases showing lipid peak. MR spectroscopy may shed light on which organism is responsible for the abscess, because the presence of anaerobic bacteria tends to cause elevated acetate and succinate peaks, whereas absence of acetate and succinate signals are more likely with obligate aerobes or facultative anaerobes [6,7].


Licensed Under Creative Commons Attribution CC BY

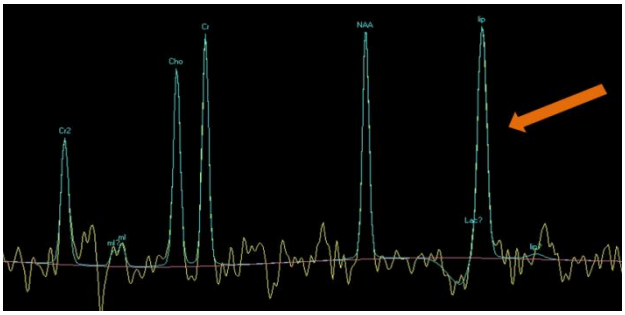


**Figure 3:** Lip peak in Abscess

Metastatic lesions showed high Cho / Cr and Cho / NAA levels with absent NAA peak. 5 were found out to have primary brain tumor of which 1 case turned out to be a low grade glioma showing a myo-inositol peak in addition to reduced NAA and raised Cho peak. These findings were similar to a study conducted by LIA Metwally, SE El-din, O Abdelaziz et al, where they concluded that Mi/Cr ratio and Mi is an important predictor for grading of gliomas, wherein the low grade glioma have a high Mi peak as compared to anaplastic glioma and GBM [8].

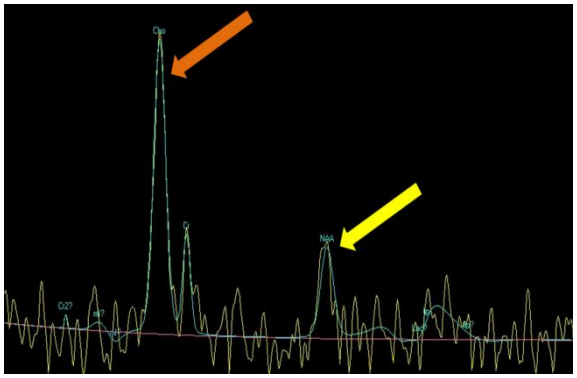


**Figure 4:** Cho peak in metastasis (orange arrow) with reduced NAA (yellow arrow)

One of the ring enhancing lesions out of 50 came out to be toxoplasmosis showing lactate peak.

## 5. Conclusion

MRI along with MRS has emerged as the most sensitive modality in the characterization of intracranial ring enhancing lesions. MRI being non invasive and non-radiating is an ideal imaging modality. Multiplanar capability of MRI was helpful in identifying precise anatomical location and the exact extent of lesions. MRS helps in differentiation and characterization of various ring enhancing lesions based on various metabolites leading to accurate diagnosis.

## References

[1] Omuro AM, Leite CC, Mokhtari K, Delattre JY. Pitfalls in the diagnosis of brain tumours. The Lancet Neurology. 2006; 5(11):937-48.
[2] Garg RK, Sinha MK. Multiple ring-enhancing lesions of the brain. Journal of postgraduate medicine. 2010; 56(4):307-16.
[3] Saha A, Ghosh SK, Roy C, Choudhury KB, Chakrabarty B, Sarkar R. Demographic and clinical profile of patients with brain metastases: a retrospective study. Asian journal of neurosurgery. 2013; 8(3):157.
[4] Jayasundar R, Singh V, Raghunathan P, Jain K, Banerji A. Inflammatory granulomas: evaluation with proton MRS. NMR in Biomedicine. 1999; 12(3):139-44.
[5] Pandit S, Lin A, Gahbauer H, Libertin CR, Erdogan B. MR spectroscopy in neurocysticercosis. Journal of computer assisted tomography. 2001; 25(6):950-2.
[6] Garg M, Gupta RK, Husain M, Chawla S, Chawla J, Kumar R, et al. Brain Abscesses: Etiologic Categorization with in Vivo Proton MR Spectroscopy 1. Radiology. 2004; 230(2):519-27.
[7] Lai PH, Li KT, Hsu SS, Hsiao CC, Yip CW, Ding S, et al. Pyogenic brain abscess: findings from in vivo 1.5-T and 11.7-T in vitro proton MR spectroscopy. American journal of neuroradiology. 2005; 26(2):279-88.
[8] Metwally LI, El-din SE, Abdelaziz O, Hamdy IM, Elsamman AK, Abdelalim AM. Predicting grade of cerebral gliomas using Myo-inositol/Creatine ratio. The Egyptian Journal of Radiology and Nuclear Medicine. 2014; 45(1):211-7.


Licensed Under Creative Commons Attribution CC BY