

A Survey on Red Lesion Detection Techniques for Diabetic Retinopathy Screening

Fayiza K T¹, Sherin Jabbar²

¹MEA Engineering College, State Highway 39, Nellikkunnu – Vengoor, Perinthalmanna, Malappuram, Kerala, India

²MEA Engineering College, State Highway 39, Nellikkunnu – Vengoor, Perinthalmanna, Malappuram, Kerala, India

Abstract: Diabetic retinopathy is a complication of diabetes where the retina is damaged due to leakage of blood from vessels into the retina. Unchecked, advanced diabetic retinopathy leads to vision impairment and blindness. It can be tedious and time consuming to identify the features such as microaneurysms, hemorrhages, exudates and cottonwool spots through manual inspection of fundus images. The shape and count of these features are used to indicate the severity level of diabetic retinopathy. A computer aided diagnosis system can help to reduce the burden on the ophthalmologist and rapidly identify the most severe cases. This review discusses the available red lesion detection techniques and automated analysis.

Keywords: Diabetic retinopathy, Microaneurysm, Hemorrhages, Thresholding, Circular Hough Transform, Dynamic shape features, Automatic detection

1. Introduction

Diabetic Retinopathy (DR) is eye disorder caused by long term diabetes. It damages blood vessels in the retina. The DR is an ocular disease that originates from diabetes mellitus. Diabetes mellitus is a disorder characterized by impaired metabolism of glucose caused by insufficient action of insulin. DR will lead to vision impairment and even blindness. It can result in permanent blindness if not treated in time. It can be managed effectively if diagnosed earlier. Since DR is asymptomatic; it does not interfere with sight until late in the disease process, regular eye screening is necessary for the early detection and treatment.

The human retina consists of blood vessels, fovea, macula and optic disc [1] [2].

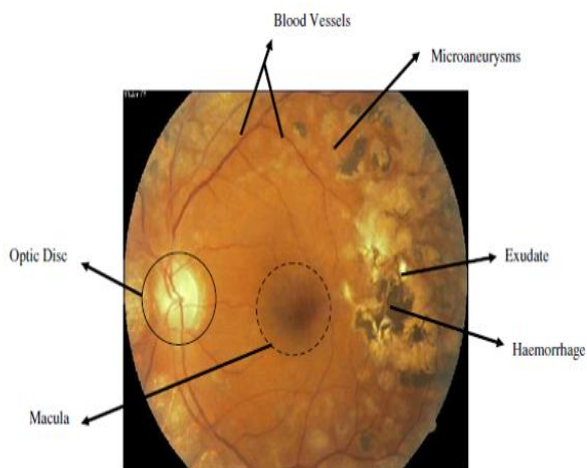


Figure 1: fundus image

Leakage of blood from vessels to the surface of retina can be observed in initial stage of diabetic retinopathy. This leakage leads to the formation of

- Microaneurysms (MA)

- Hemorrhages (HE)
- Exudates
- Cottonwool spots

Microaneurysms are small circular red spots with diameter 10 to 100 μm which are the first sign of DR. It is tiny swelling appears in the retinal capillaries as a small, round, red spot located in the inner nuclear layer of the retina.

Hemorrhages are located in the middle layer of the retina. HEs are in different types.

- Dot
- Blot
- Flame

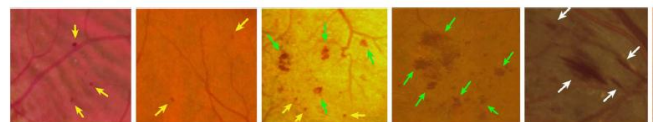


Figure 2 : Portions of fundus images with red lesions

It is difficult to distinguish dot HE from MA on fundus images, thus dot HEs are usually referred to as MAs. A flame HE is blood leaking into the nerve fiber layer. Its shape, more elongated, follows the structure of the nerve fibers. A blot HE is blood leaking deeper in the retinal layer. Blot HE appears larger than a dot HE, and its borders are irregular, leading to various shapes. Figure 2 shows examples of these lesions types [3].

Cotton wool spots are fluffy white patches on the retina which are caused by damage to nerve fibers. Exudates are yellow flecks. They are the lipid residues of serous leakage from damaged capillaries.

Diabetic retinopathy can be classified as proliferative diabetic retinopathy and nonproliferative diabetic retinopathy [4]. NPDR occurs when the blood vessels get damaged inside the retina and leak extra fluid and small

International Journal of Science and Research (IJSR)

www.ijsr.net

Licensed Under Creative Commons Attribution CC BY

amounts of blood onto the retina. With this condition, retina becomes wet and swollen. Three subclasses of NPDR are

- Mild
- Moderate
- Severe

Mild NPDR

Presence of at least one microaneurysm with or without the retinal haemorrhages.

Moderate NPDR

Presence of Numerous microaneurysms and retinal haemorrhages.

Severe NPDR

Numerous haemorrhages and microaneurysms in four quadrants of the retina.

PDR is an advanced stage of diabetic retinopathy. Growth of new abnormal blood vessels in different regions of the retina may lead to total blindness [5].

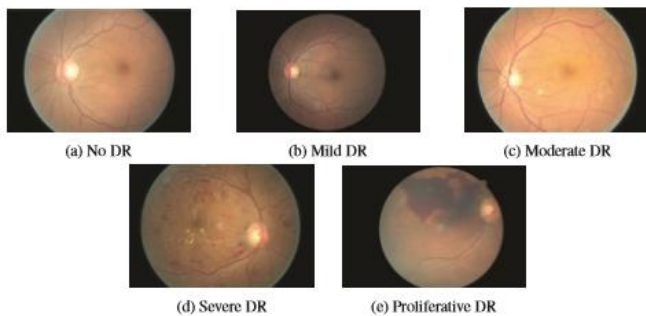


Figure 3: Stages of diabetic retinopathy (DR)

Figure 3 shows different stages of diabetic retinopathy based on increasing severity [6]. The research focuses on the analysis of different red lesion detection techniques used in available automatic telemedicine systems for computer aided screening and grading of DR.

2. Related Works

Diabetic retinopathy screening is a popular research area and a lot of researchers focus on and contribute towards the advancement of study in this area. Automatic detection methods for diabetic retinopathy screening were proposed in order to address the manual screening issues. The goal of automated methods for screening is to identify the needs of referral for further treatment. Different methods have been proposed and used for detecting the red lesions in order to produce an efficient and reliable detection system.

2.1 Threshold based method

Vijay M Mane et al [7] proposed a method for combined MA and HE detection consists in identifying all dark colored structures in the image, mainly through a thresholding and removing the vessels from the resulting set of candidates using matched filtering. Unfortunately, the major limitation to this approach is that most of the false positives at the vessel segmentation step are actually lesions. These lesions are removed along with the detected vessels and cannot be retrieved in subsequent processing.

2.2 Mathematical morphology based method

Sopharak et al [8] proposed a set of optimally adjusted morphological operators for exudate detection. In preprocessing stage the RGB space of the original image is transformed to HSI space and a contrast limited adaptive histogram equalization (CLAHE) is applied. Then a morphological operator such as a closing operator and a local variation operator is used to eliminate the vessels and to detect exudates respectively.

2.3 Circular hough transform

Amiri et al [9] presents an automated method for detecting microaneurysms in the retinal angiographic images by using image processing techniques. In the presented method, retinal images are preprocessed to fade or remove the pseudo images. Then the central points of microaneurysms are identified by circular hough transform. Then by using the region growing technique, the total areas of pixels associated with these lesions are identified. Hough transform is a kind of Brute Force method. Its computational complexity and large memory requirement leads to slowness in performance.

2.4 Curvelet transform

Syed Ayaz et al [10] proposed an automated microaneurysm detection system based on curvelet transform. Blood vessels are removed and a local entropy thresholding technique is used to select the microaneurysm candidates. Image background is estimated using statistical features. The results are allowed to identify the microaneurysm candidates which are also present in the image foreground. A collection of three set of features, namely color based, hessian matrix based and curvelet coefficients based are fed to a rule based classifier to divide the candidate as microaneurysms and non microaneurysms.

2.5 Dynamic shape features

Lama Seoud et al [3] proposed a method for the detection of both MAs and HEs that does not require prior vessel segmentation. A supervised classification scheme is considered to discriminate between lesions and other structures like vessel segments and background noise. After image pre-processing, candidate regions are identified. Features are extracted and used to classify each

candidate. The major contribution is a new set of shape features that do not require precise segmentation of the candidates. Every regional minimum is considered as a candidate. Since the boundaries of the minima do not necessarily correspond to the edges of the structures of interest, propose to extract shape features through the process of morphological image flooding.

2.6 Convolutional neural network

Harry Pratt et al [6] introduce a deep learning based CNN method to diagnosing DR from digital fundus images. A network with CNN architecture and data augmentation is developed to identify the intricate features involved in the classification task. A high end graphics processor unit (GPU) is used to train the network.

2.7 Scale space based method

Ivo soares et al [11] proposed a scale space based method for the microaneurysm detection. The method performs a segmentation of the retinal vasculature. Then defines a global set of microaneurysm candidates using coarser and finer scales. Finer scales are used for analysis. The numbers of false microaneurysm candidates are reduced by using a set of gaussian shaped matched filters.

2.8 Hybrid approach

M Usman Akram et al [12] proposed a system consisting of a novel hybrid classifier for the detection of retinal lesions. In pre-processing the systems eliminates the background pixels and extract the blood vessels. Gabor filter bank is used to extract the candidate lesion detection phases that have any type of lesion. A feature set based on shape, intensity and statistics is formulated and classified using a hybrid classifier which is combination of m-Medoids and Gaussian Mixture model.

3. Discussion

Three measures are used to compare the performance of automated detection of red lesions. Sensitivity, specificity and accuracy.

- Sensitivity : Probability of a positive test given that the patient has disease

$$Sensitivity = \frac{TP}{TP+FN} \times 100\% \quad (1)$$

- Specificity : Probability of a negative test given that the patient has no disease

$$Specificity = \frac{TN}{TN+FP} \times 100\% \quad (2)$$

Table 1: Comparison Results of Methods for Red lesion detection

Author	Methods	Dataset	Performance measure
Vijay M Mane [7]	Thresholding Filtering	DIARETDB1	Sensitivity - 96.42% Specificity - 100% Accuracy - 96.62%
Sopharak [8]	Morphological operators	ROC database	Sensitivity - 80% Specificity - 99.5%
Amiri [9]	Circular hough transform	OWN database	Accuracy - 88.5%
Syed Ayaz [10]	Local thresholding Curvelet transform	ROC database	Sensitivity - 48.21%
Lama Seoud [3]	Dynamic shape features	ROC database	Sensitivity - 93.3% Specificity - 93.3%
Harry Pratt [6]	Convolutional neural network	Kaggle dataset	Sensitivity - 95% Accuracy - 75%
Ivo soares [11]	Coarser and finer scales	ROC database	Sensitivity - 47%
M Usman Akram [12]	Multilayered thresholding Gabor filtering	ROC database	Sensitivity - 97.83% Specificity - 98.36% Accuracy - 98.12%

4. Conclusion

This review presents a detailed survey of methods and results used for the automatic detection of DR stages. The process of analyzing retinal images involves series of steps. Image acquisition, image preprocessing, Candidate feature extraction and classification. All these steps include various techniques or algorithms. Some existing methods are compared to give a complete view of the field.

Most of them use a threshold based method to segment the image and blood vessels are removed. Intensity features are formulated to classify the images. Unfortunately, the major limitation to this approach is that most of the false positives at the vessel segmentation step are actually lesions. These lesions are removed along with the detected vessels and cannot retrieve in subsequent processing.

Hough transform is used to find features of any shape in an image. Regular curves such as lines, circles and ellipses can be detected using this method. Circular hough transform is used to find circles in imperfect image inputs. But its computational complexity and large memory requirement leads to slowness in performance.

Dynamic shape features have proven to be robust features, highly capable of discriminating between lesions and vessel segments. The concept of DSFs could be exploited in other applications, particularly when the objects to be detected do not show clear boundaries and are difficult to segment precisely.

References

- [1] S. S. Rahim, C. Jayne, V. Palade and J. Shuttleworth, "Automatic detection of microaneurysms in colour fundus images for diabetic retinopathy screening," *Neural Computing and Applications*, pp. 1–16, 2015.
- [2] M. U. Akram, S. Khalid, A. Tariq, S. A. Khan and F. Azam, "Detection and classification of retinal lesions for grading of diabetic retinopathy," *Computers in biology and medicine*, vol. 45, pp. 161–171, 2014.
- [3] L. Seoud, T. Hurtut, J. Chelbi, F. Cheriet and J. P. Langlois, "Red lesion detection using dynamic shape features for diabetic retinopathy screening," *IEEE transactions on medical imaging*, vol. 35, no. 4, pp. 1116–1126, 2016.
- [4] M. R. K. Mookiah, U. R. Acharya, C. K. Chua, C. M. Lim, E. Ng and A. Laude, "Computer aided diagnosis of diabetic retinopathy: A review," *Computers in biology and medicine*, vol. 43, no. 12, pp. 2136–2155, 2013.
- [5] O. Faust, R. Acharya, E. Y.-K. Ng, K.-H. Ng and J. S. Suri, "Algorithms for the automated detection of diabetic retinopathy using digital fundus images: a review," *Journal of medical systems*, vol. 36, no. 1, pp. 145–157, 2012.
- [6] H. Pratt, F. Coenen, D. M. Broadbent, S. P. Harding, and Y. Zheng, "Convolutional neural networks for diabetic retinopathy," *Procedia Computer Science*, vol. 90, pp. 200–205, 2016.
- [7] V. M. Mane, R. B. Kawadiwale and D. Jadhav, "Detection of red lesions in diabetic retinopathy affected fundus images," in *Advance Computing Conference (IACC)*, 2015 IEEE International. IEEE, 2015, pp. 56–60.
- [8] A. Sopharak, B. Uyyanonvara, S. Barman and T. H. Williamson, "Automatic detection of diabetic retinopathy exudates from nondilated retinal images using mathematical morphology methods," *Computerized medical imaging and graphics*, vol. 32, no. 8, pp. 720–727, 2008.
- [9] S. A. Amiri, H. Hassanpour, M. Shahiri and R. Ghaderi, "Detection of microaneurysms in retinal angiography images using the circular hough transform," *Journal of Advances in Computer Research*, vol. 3, no. 1, pp. 1–12, 2012.
- [10] S. A. A. Shah, A. Laude, I. Faye and T. B. Tang, "Automated microaneurysm detection in diabetic retinopathy using curvelet transform," *Journal of biomedical optics*, vol. 21, no. 10, pp. 101 404–101 404, 2016.

[11] I. Soares, M. Castelo-Branco, and A. M. Pinheiro, "Microaneurysms detection using a novel neighborhood analysis," 2014.

[12] Akram, M. Usman, Shehzad Khalid, Anam Tariq, Shoab A. Khan, and Farooque Azam. "Detection and classification of retinal lesions for grading of diabetic retinopathy." *Computers in biology and medicine* 45 (2014): 161-171.

Author Profile



Fayiza K T received her B.Tech degree in computer science and engineering from the MES College of Engineering, Kuttippuram, Kerala, in 2014. Right now she is pursuing her M. Tech degree in computer science and engineering at MEA Engineering College, Kerala from 2015 to 2017. Her research interests lies in Image Processing.



Sherin Jabbar is a post graduate in Computer Science and Engineering from MES College of Engineering, Kuttippuram. She graduated from Govt. Engineering College, Sreekrishnapuram, Palakkad. She is currently working as Assistant Professor in MEA Engineering College, Kerala. Her research interest lies in Image Processing.