

A Case Presentation on Schwannoma

Vemula Indira Priyadarshini¹, Pavan Kumar Yalamanchali², Srikanth Mandapati³

¹3rd Year Surgery Post-Graduate, Department of Surgery & Guntur Medical College, Guntur, Andhra Pradesh, India

²2nd Year Surgery Post-Graduate, Department of Surgery & Guntur Medical College, Guntur, Andhra Pradesh, India

³1st Year Surgery Post-Graduate, Department of Surgery & Guntur Medical College, Guntur, Andhra Pradesh, India

Abstract: Schwannomas are derived from Schwann cells of neuroectoderm. Their function is to form the myelin sheath of nerves in the peripheral nervous system, which insulates the nerve and facilitates the transmission of an impulse. Schwannoma is a benign encapsulated slow growing tumor [9,10]. Schwannomas are the most common peripheral nerve sheath tumors (1%) Schwannomas most commonly occur in adults between 20 and 50 years of age. We report a case of sciatic schwannoma in this article.

Keywords: Schwannoma, tumor, neuroectoderm.

1. Introduction

1.1 Case Report

A 38-year-old man was admitted to our General surgery Department with a slow-growing, painful swelling in his left posterior thigh. The swelling had been present for more than 1 year. Tinel sign was positive on the posterior aspect of the left thigh. On physical examination, a painful isolated soft-tissue mass was detected in the posterior aspect of the left thigh. No motor deficit was detected on neurological examination. MRI showed a well-defined soft-tissue mass associated with the sciatic nerve at the posterior aspect of the mid-to-distal thigh. The mass showed intermediate T1 signal intensity and heterogeneously high T2 signal intensity, with multiple internal low-signal foci (figure 1). The patient underwent a linear midline skin incision on the posterior surface of the thigh. The schwannoma was seen in relation to the sciatic nerve. The tumor had originated from the main sciatic nerve

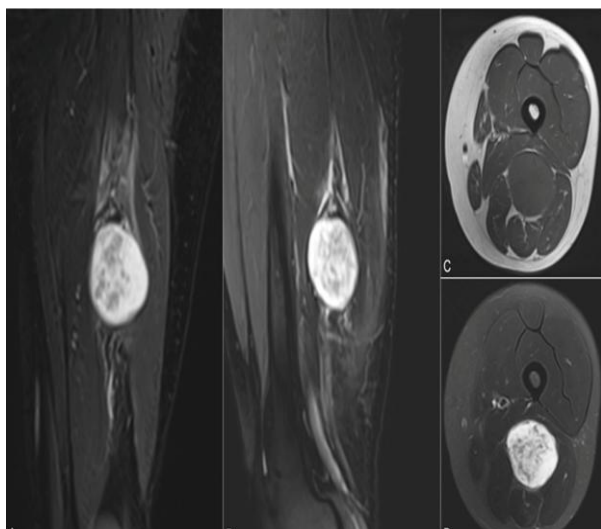


Figure 1: MRI image

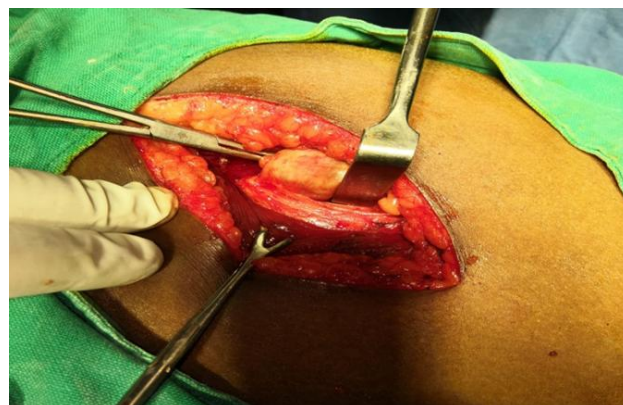


Figure: Intra-operative image of well encapsulated schwannoma

Complete excision of the tumor was performed. Macroscopically, the tumor was characterized by an encapsulated nodule 6 cm in length with a firm greyish cut surface. There was no neurological deficit in the postoperative period. Microscopically, the tumor was composed of spindle cells showing short fascicular arrangement in a collagenous stroma. The neoplastic cells had wavy vesicular nuclei and eosinophilic cytoplasm (Figure 3). No mitotic activity or necrosis was found. Perivascular hyalinization and intra-tumoral scattered mast cells were seen.

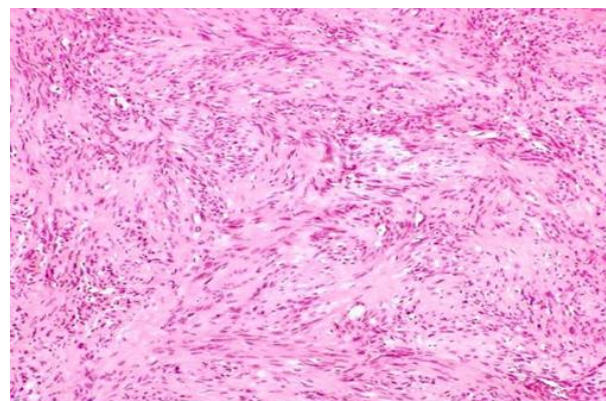


Figure 3: Histopathology slide showing wavy vesicular nuclei with eosinophilic cytoplasm

2. Discussion

Peripheral nerve tumors are rare conditions. Frequent locations for schwannomas are the head, neck and main nerve trunk (1, 6). Schwannomas in the sciatic nerve are rare and usually present as a mass or pain in the thigh. Sciatic schwannoma frequency is less than 1% (3, 4, 5). Schwannomas occur in any age group; there is no sex predilection. The posterior tibial nerve at the tarsal sinus is the most frequently involved nerve of the lower limb. The most common clinical presentation of sciatic nerve schwannoma consists of a painful palpable mass (7, 9, 11). Schwannomas most commonly occur in adults between 20 and 50 years of age. Schwannomas are usually homogeneous on both T1- and T2-weighted images but a neurofibroma is usually heterogeneous. Sciatic schwannoma has a good prognosis and a low incidence of recurrence and malignant transformation. The risk of malignant transformation is approximately 18% in neurofibromatosis type 1 and 5% in schwannomas. Patients with von Recklinghausen disease carry a worse prognosis (2, 8, 10, 12)

Macroscopic appearance:

Schwannomas are benign encapsulated neoplasms of Schwann cells (WHO grade I). They arise eccentrically from their parent nerve, with the nerve fibers splayed along their surface (as distinct to neurofibromas which arise within the nerve).

Microscopic appearance:

Conventional schwannomas are composed of spindle cells which demonstrate two growth patterns: Antoni type A and Antoni type B (6, 7).

Antoni type A pattern:

Elongated cells are densely packed and arranged in fascicles. Palisades are sometimes seen; when prominent these form Verocay bodies.

Antoni type B pattern cells:

Less compact and are prone to cystic degeneration.

Variants

Schwannoma variants include (6,8):

- Ancient schwannoma,
- Cellular schwannoma: predominantly composed of Antoni A tissue, no Verocay bodies, most commonly found in a paravertebral location, or trigeminal nerves (CN V)
- Melanotic schwannoma: Contain dense melanin pigment.
- Plexiform schwannoma: usually arise from skin or subcutaneous tissue usually diagnosed at birth or childhood.

3. Conclusion

Schwannoma is rare cause of sciatica. Although rare, schwannoma and neurofibroma of the sciatic nerve should be suspected if persistent pain is reported with no signs of radicular compression at imaging.

References

- [1] Dudeney S, O'Farrell D, Bouchier-Hayes D, Byrne J: Extraspinal causes of sciatica. A case report. *Spine* 23: 494-496, 1998.
- [2] Gabhane SK, Kotwal MN, Bobhate SK: Morphological spectrum of peripheral nerve sheath tumors: A series of 126 cases. *Indian J Pathology and Microbiology* 52:29-33, 2009
- [3] Ghaly RF: A posterior tibial nerve neurilemoma unrecognized for 10 years: Case report. *Neurosurgery* 48:668-672, 20014.
- [4] Hamdi MF, Aloui I, EnnouriKh: Sciatica secondary to sciatic nerve schwannoma. *Neurol India* 57:685-686, 2009
- [5] Kralick F, Koenigsberg R: Sciatica in a patient with unusual peripheral nerve sheath tumors. *Surg Neurol* 66:634-637, 20067.
- [6] Skolnik AD, Loevner LA, Sampathu DM et-al. Cranial Nerve Schwannomas: Diagnostic Imaging Approach. *Radiographics*. 2016;36 (5): 150199. doi:10.1148/rg.2016150199 - Pubmed citation
- [7] Louis DN, Ohgaki H, Wiestler OD et-al. The 2007 WHO classification of tumours of the central nervous system. *Acta Neuropathol.* 2007;114 (2): 97-109. *Acta Neuropathol.* (full text) - doi:10.1007/s
- [8] 00401-007-0243-4 - Free text at pubmed - Pubmed citation
- [9] Pilavaki M, Chourmouzi D, Kiziridou A, Skordalaki A, Zarampoukas T, Drevlengas A: Imaging of peripheral nerve sheath tumors with pathologic correlation: Pictorial review. *Eur J Radiol* 52:229-239, 2004
- [10] Schultz E, Sapan MR, McHeffey-Atkinson B, Naidich JB, Arlen M. Case report 872. "Ancient" schwannoma (degenerated neurilemmoma). *Skeletal Radiol.* 1994; 23:593-595.
- [11] Stout AP. Tumors of the Peripheral Nervous System. In: *Atlas of Tumor Pathology, Armed Forces Institute of Pathology, Washington DC, Section, 1949, 2.*