

Primary Osteosarcoma of the Skull

Dhawal Kaushal¹, Manisha Joshi²

Abstract: Primary osteosarcomas of the skull account for <2% of all skull tumors. They are aggressive neoplasms composed of spindle cells producing osteoid which tend to have poor outcome. The classic appearance of sunray pattern and Codman's triangle is highly suggestive of osteosarcoma. Early diagnosis and prompt management can help in improving the survival rate. We present a case with typical radiographic appearance of osteosarcoma arising from skull in young male patient.

Keywords: Codman's triangle, osteogenic sarcoma

1. Introduction

Osteosarcoma is the most common primary bone tumor which usually seen in extremities and rarely seen in the cranial vault.[1] The incidence is about 1%-2% of all skull tumors and is less than 10% in tumors of the head and neck region. [2-4] The most common craniofacial sites are the mandible and maxilla, followed by the calvaria and then the skull base.[5] The most common radiological findings of osteosarcoma are ill defined osteolytic lesion with wide zone of transition, cortical bone destruction, an aggressive spiculated periosteal reaction with associated soft tissue mass.

2. Literature Survey: Case Report

We hereby present a case of 14 yr old boy from Madhya Pradesh who was referred to our department for a gradually increasing swelling in the right occipital region. Initially it was a small sized lesion about a size of a pea, one and half years back which over 6 months increased in size and was biopsied which came out as osteosarcoma. Patient was started on chemotherapy and the size remained constant during the 5 cycles for a period of 5 months. Since the size increased constantly over another span of 6 months and considering the significant increase in size patient was not operated upon. The patient presented with a large mass involving the right parieto-temporo-occipital region, bilateral proptosis, bilateral disc edema with no neurological deficits. Patient had a history of fracture in the right femur 6 years back for which plating was done however the exact cause could not be ruled out.

CT scan was carried out which showed presence of large expansile soft tissue density mass involving right parieto-temporo-occipital region of the calvarium involving the both inner and outer tables with evidence of destruction and significant spiculated type of periosteal reaction. (Fig 1 and 2). The soft tissue component is to extend intracranially and cause mass effect noted in the form of compression and displacement of right cerebellar hemisphere towards left side and narrowing of the IVth ventricle. The lesion is seen to abut the right transverse sinus, torcularherophili however these show normal enhancement on post contrast imaging (Fig 3).

The lesion is supplied by the branches of right external carotid artery (namely right superficial temporal arteries, posterior auricular and occipital) and left posterior auricular

from the left side. (Fig 4). 3D Volume reconstruction was also done (Fig 5).

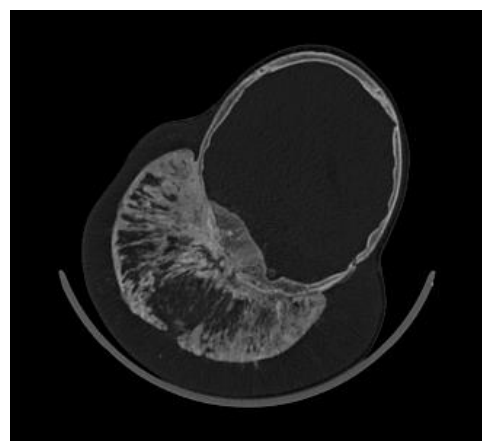


Figure 1

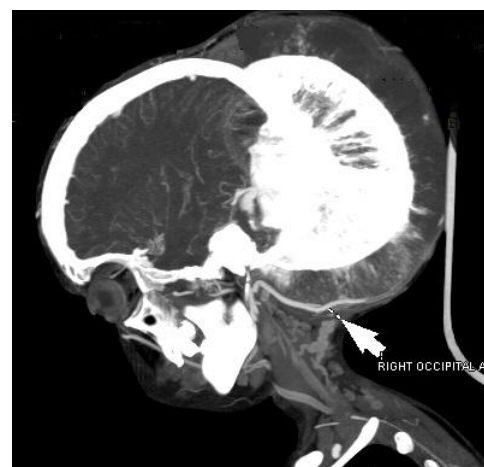


Figure 2

Fig 1 & 2 Axial bone window and sagittal CECT sections showed presence of large expansile soft tissue density mass involving right parieto-temporo-occipital region of the calvarium involving the both inner and outer tables with evidence of destruction and significant spiculated type of periosteal reaction.

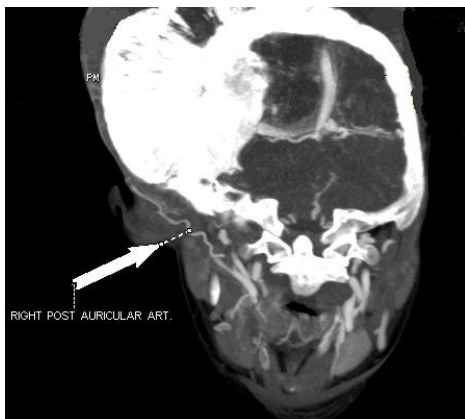


Figure 3

Fig 3 Coronal CECT sections showed soft tissue component is to extend intracranially and cause mass effect noted in the form of compression and displacement of right cerebellar hemisphere towards left side and narrowing of the IV th ventricle. The lesion is seen to abut the right transverse sinus, torcularherophili however these show normal enhancement on post contrast imaging.

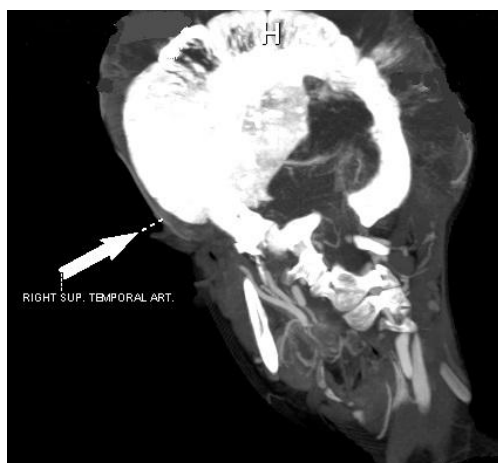

Figure 4

Fig. 4 CECT Coronal image showing lesion is deriving its supply from the branches of right external carotid artery (namely right superficial temporal arteries, posterior auricular and occipital) and left posterior auricular from the left side.

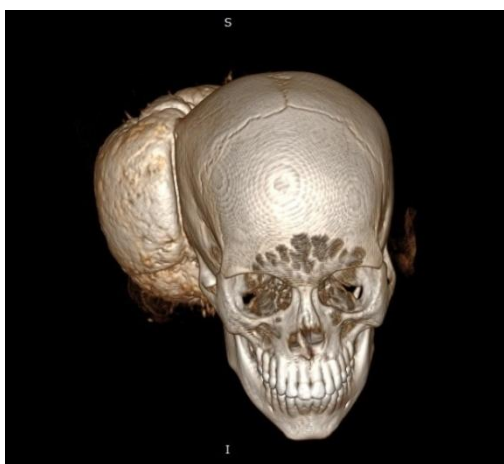


Figure 5

Fig 5.3D Volume reconstruction showing the bony lesion.

3. Results / Discussion

Here, we report a case of primary osteosarcoma of the skull, an extremely rare neoplasm at that location. Osteosarcoma is the most common solid primary malignancy of bone with skull being a rare site. Approximately 150 cases have been reported in the literature since 1945.[6-13]

The lesion usually presents as a slow growing swelling, pain and associated soft tissue mass, which is tender to palpation.[7,8,11,13] Looking at the patient clinically the basic investigation should start from radiography which can be assisted with computed tomography for demonstrating the soft tissue component, aggressive periosteal reaction and bony destruction at the site of the lesion, for evidence of disease dissemination and assisting in surgical planning. Magnetic resonance imaging with contrast can help in evaluating the intra/ extracranial soft tissue / intraosseous component with extension and involvement of the neurovascular structures. Usually On T1-weighted images, the solid, non-mineralized portions of osteosarcoma generally appear as areas of low-to-medium signal intensity. On T2-weighted images, the tumor shows high signal intensity.[1,6] The typical pattern of contrast uptake by the lesion is one of intense heterogeneous impregnation.

The prognosis is worse than is that of osteosarcoma involving the bones of the appendicular skeleton, osteosarcoma of the skull presenting a lower response to aggressive multimodal therapy, with a five-year survival rate below 10%.[14,15]

4. Conclusion

Osteosarcoma is one of the common aggressive malignant tumor of bone which predominantly involves the bones of the extremities and less likely involving the bones of skull and face. The clinician should be well aware of the clinical and typical imaging appearances mass which may assist in early diagnosis and prompt management so as to decrease the mortality considering its poor prognosis.

5. Learning Points

- Osteosarcoma of the skull is a rare entity.
- Aggressive nature of lesion can lead to unexpectedly large sizes.
- Early diagnosis and timely management is important considering poor prognosis.

References

- [1] Anil S, Krishnan AP, Rajendran R. Osteosarcoma of the mandible masquerading as a dental abscess: report of a case. *Case Rep Dent* 2012;2012:635062.
- [2] Bose B. Primary osteogenic sarcoma of the skull. *SurgNeurol* 2002;58:234-9.
- [3] Sofiene B, Asma B, Adnene B, Imed BS, Jalel K, Lassaad A, et al. A case report of osteosarcoma of the skull. *Open J Mod Neurosurg* 2014;4:105-9.

- [4] Yamamoto A, Sakamoto J, Muramatsu T, Hashimoto S, Shibahara T, Shimono M, et al. Osteosarcoma of maxilla with unusual image findings in child. *Bull Tokyo Dent Coll* 2011;52:201-7.
- [5] H Caroline, Gressot Loyola V., Patel Akash J., Wang Lisa L., Flores Ricardo J., Whitehead William E. et al. Osteosarcoma of the cranial vault and skull base in pediatric patients *NeurosurgPediatrics* 13:380–387, 2014 380 *J Neurosurg: Pediatrics / Volume 13 / April 2014 ©AANS, 2014*
- [6] Ashkan K, Pollock J, D'Arrigo C, Kitchen ND (1998) Intracranial osteosarcomas:report of four cases and review of the literature. *J Neurooncol* 40: 87-96.
- [7] Benson JE, Goske M, Han JS, Brodkey JS, Yoon YS (1984) Primary osteogenic sarcoma of the calvaria. *AJNR Am J Neuroradiol* 5: 810-813.
- [8] Gadwal SR, Gannon FH, Fanburg-Smith JC, Becoskie EM, Thompson LD (2001) Primary osteosarcoma of the head and neck in pediatric patients. *Cancer* 91:598-605.
- [9] Gangadhar K, Santhosh D (2012) Radiopathological evaluation of primary malignant skull tumors: a review. *ClinNeurolNeurosurg* 114: 833-839.
- [10] Garland LH (1945) Osteogenic sarcoma of the skull. *Radiology* 45: 45-48.
- [11] Mascarenhas L, Peteiro A, Ribeiro CA, Magalhães Z, Romão H, et al. (2004) Skull osteosarcoma: illustrated review. *ActaNeurochir* 146: 1235-1239.
- [12] Fukunaga M (2005) Low-grade central osteosarcoma of the skull. *Pathol Res Pract* 201: 131-135.
- [13] Chander B, Ralte AM, Dahiya S, Sharma MC (2003) Primary osteosarcoma of the skull. A report of 3 cases. *J NeurosurgSci* 47: 177-181.
- [14] Greenspan A. *Radiologiaortopédica - uma abordagem prática*. 5ª ed. Rio de Janeiro: Guanabara Koogan; 2012.
- [15] Salvati M, Ciappetta P, Raco A. Osteosarcomas of the skull. Clinical remarks on 19 cases. *Cancer*. 1993;71:2210–2216.

Author Profile



Dr Dhawal Kaushal has approximately 4 years of experience post M.D. He has worked in various hospitals in Chennai and Mumbai with few publications, posters and fellowships to his credit.



Dr Manisha Joshi have been working as assistant professor in one of the esteemed tertiary care hospitals of Mumbai with over 9 years of experience and several publications. She takes keen interest in diagnostic cross-sectional imaging.