

Arthroscopic Anatomic Single Bundle ACL Reconstruction Using Quadrupled Hamstring Autograft

Altat Kawoosa¹, Shafeeq Ahmad²

¹Associate Professor, Department of Orthopaedics, Government Hospital for Bone & Joint Surgery, Government Medical College, Srinagar, J&K India-190015

²Junior Resident, Department of Orthopaedics, Government Hospital for Bone & Joint Surgery, Government Medical College, Srinagar, J&K India-190015

Abstract: Purpose: To observe the findings and results of arthroscopic anatomic single bundle anterior cruciate ligament (ACL) reconstruction using hamstring tendon autograft. Patients and Methods: This prospective study included 25 patients: 22 male patients and 03 female patients, with an age of 18–45 years. The patients underwent arthroscopic anatomic single bundle ACL reconstruction using hamstring tendon autograft. In addition to standard anteromedial (AM) and anterolateral (AL) portals, accessory anteromedial (AAM) portal was used for femoral tunnel placement. In all patients, femoral fixation of graft was done using Endobutton CL. In 8 patients tibial fixation of graft was done using suture disc while in 17 patients tibial fixation of graft was done using interference screw. Results: Medial meniscal tear was found associated in 7 patients and partial medial meniscectomy was performed. In 2 patients, tear of both medial and lateral menisci was found, with bucket handle tear of medial meniscus, partial meniscectomy was done. At final follow up, 80% of patients had a negative Lachman test, 16% of the patients had grade 1+ Lachman test, and 1 patient had grade 2+ Lachman test. None of the patients had grade 3+ Lachman test at final follow up. All the patients with grade 1+ Lachman test were asymptomatic. Pivot shift test was negative in all patients at one year postoperatively. The Lysholm functional score improved from a mean pre-operative value of 63.6 (range 50-81) to a mean of 92.04 (range 76–98) at one year postoperatively. Conclusion: Anatomical single bundle ACL reconstruction using medial portal technique results in excellent functional knee scores.

Keywords: Anatomical, ACL reconstruction, Lysholm knee score

1. Introduction

ACL reconstruction is one of the most commonly performed sports medicine procedures in the United States, with more than 130,000 procedures performed each year.⁽¹⁾ Anatomic placement of ACL graft is critical to the success and clinical outcome of ACL reconstruction. Anatomic ACL graft placement is defined as positioning the ACL femoral and tibial bone tunnels at the center of the native ACL femoral and tibial attachment sites. Clinical studies have demonstrated that non-anatomic ACL graft placement is the most common technical error leading to recurrent instability following ACL reconstruction.^(2,3) In the anatomical SB technique, the femoral tunnel is first drilled to the center of the anatomical attachment of the native ACL at the medial wall of the lateral femoral condyle using AM portal^(4,5,6). Then the tibial tunnel is drilled at the center of anatomic tibial native ACL insertion with a guide and the graft is fixed with the knee at 15-20° of flexion.⁽⁷⁾

2. Materials and Methods

This was a prospective study conducted on skeletally mature patients with ACL tear after approval of the institutional board. Twenty five cases (22 males and 03 females, aged between 18–45 years) operated between August 2015 to

March 2017, were included in this study. Informed consent was obtained from all the cases. The diagnosis was made clinically (Lachman test, Anterior Drawer test, Pivot shift test, and McMurray test) and confirmed by MRI in all cases. All the cases with isolated ACL tear with or without meniscal injury were included in the study. Manual Stability tests especially the Lachman test, anterior and posterior drawer tests and pivot shift tests were performed under anesthesia before surgery. Preoperative Lysholm score was recorded in all the cases.

Table 1: Pre-operative evaluation

S. No.	Age (Years)	Sex	Side involved	Mode of injury	Time since injury	PreOp Lysholm Score
1	30	F	Left	Fall	3 Months	50
2	27	M	Left	Sports Injury	24 Months	64
3	37	M	Right	RTA	6 Months	61
4	26	M	Right	Sports Injury	2 Months	54
5	27	M	Right	Sports Injury	2 Months	64
6	36	M	Left	RTA	3 Months	66
7	25	F	Left	Fall	36 Months	64
8	19	M	Right	Sports Injury	4 Months	66
9	40	M	Right	RTA	3 Months	55
10	30	M	Left	RTA	4 Months	64
11	40	F	Right	Fall	24 Months	61
12	26	M	Right	Sports Injury	48 Months	55
13	33	F	Right	Fall	12 Months	67

Volume 8 Issue 2, February 2019

www.ijsr.net

Licensed Under Creative Commons Attribution CC BY

14	19	M	Right	Sports Injury	2 Months	55
15	32	M	Right	Sports Injury	15 Months	74
16	28	M	Right	Sports Injury	6 Months	66
17	33	M	Right	Fall	12 Months	61
18	23	M	Left	Sports Injury	5 Months	72
19	23	M	Left	RTA	24 Months	81
20	32	M	Right	RTA	12 Months	72
21	25	M	Left	RTA	60 Months	60
22	28	M	Right	Sports Injury	10 Months	72
23	32	M	Right	RTA	5 Months	54
24	23	M	Left	Sports Injury	7 Months	71
25	32	M	Left	Fall	18 Months	61
						Mean = 63.6

Arthroscopic anatomic single bundle ACL reconstruction was done using quadrupled hamstring tendon autograft. After sterile preparation, graft harvest was performed through a 3 to 4 cm incision at the insertion of pes anserinus tendons, 4 cm distal to the joint line and 3 cm medial to the tibial tuberosity. The ACL graft consisted of the four stranded ST and Gracilis tendons with a graft diameter between 7-9 mm. In addition to standard anteromedial (AM) and anterolateral (AL) portals, accessory anteromedial (AAM) portal was used for femoral tunnel placement.

The accessory anteromedial (AAM) portal was established using an 18-gauge spinal needle under direct visualization. AAM portal was placed as low as possible above the medial joint line while avoiding the anterior horn of the medial meniscus. This portal was made to allow improved visualization of the lateral wall of the intercondylar notch and achieve correct placement of the femoral tunnel. Bony landmarks were visualized, especially the lateral intercondylar ridge and the lateral bifurcate ridge, using the following appropriate measurements: The center of the ACL femoral attachment site is 1.7 mm deep to the bifurcate ridge, 6.1 mm posterior to the lateral intercondylar ridge⁽⁸⁾ and 7.3– 8.5 mm superior to the inferior articular cartilage border of the lateral femoral condyle in 90 degree knee flexion. The femoral tunnel was placed below the lateral intercondylar ridge. If this bony landmark was not identified, the whole medial wall of the lateral femoral condyle was visualized and tunnel was placed in the lower 30-35% of the notch wall. The tibial tunnel was drilled in the center of the tibial footprint using a tibial aimer and a fluted reamer. Four anatomic landmarks were used to locate the tibial tunnel centre: (1): the anterior horn of lateral meniscus, (2): the medial tibial spine, (3): the PCL, and (4): the ACL stump. In all patients, femoral fixation of graft was done using Endobutton CL. In 8 patients tibial fixation of graft was done using suture disc while in 17 patients tibial fixation of graft was done using interference screw. Tibial fixation was performed in 20 degrees of knee flexion using interference screw or suture disc. The knee was cycled from 0 to 120° approximately 25 times for preconditioning of the graft. The stability of knee was checked, and the wound was closed. Routine antibiotic prophylaxis was given.

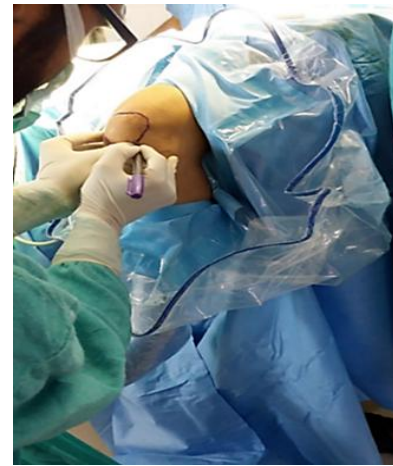


Figure 1: With the knee at 90 degrees of flexion, the borders of the patella, patellar tendon, tibial tubercle, and the joint lines marked on the skin with a sterile surgical marking pen.

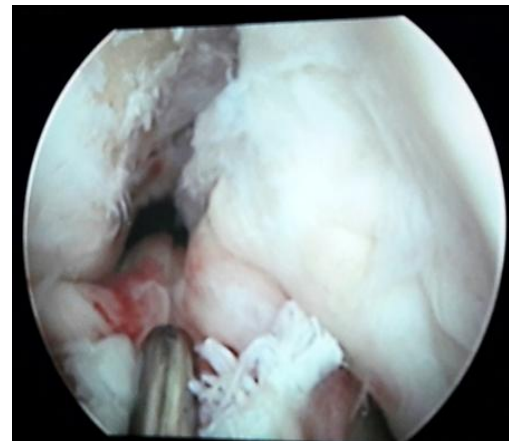

Figure 2: Arthroscopic medial portal view of the right knee, showing the remnants of the torn ACL

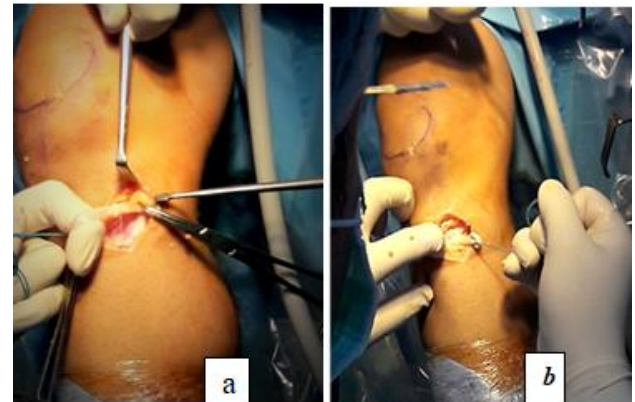


Figure 3 a and b: Hamstring Graft Harvesting

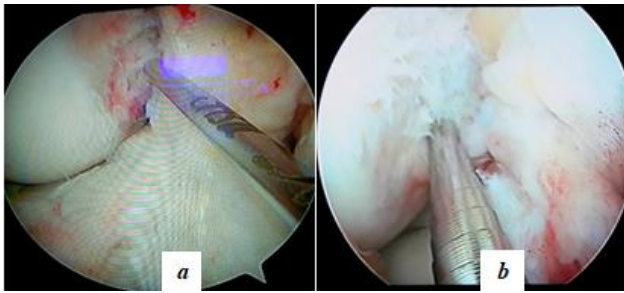


Figure 4. a, b : Arthroscopic medial portal view of the right knee, showing the site of femoral tunnel drilling at the center of the femoral footprint.

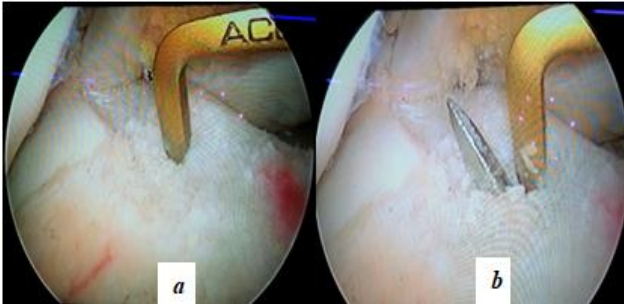


Figure 5. a, b : Arthroscopic view showing the site of tibial tunnel drilling at the center of tibial footprint.

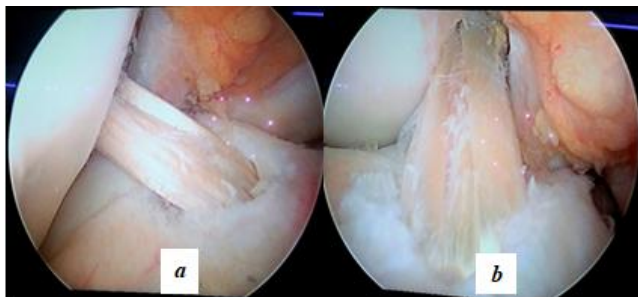


Figure 6.a : Anterolateral portal view of the graft after tibial fixation.

b: Medial portal views of the graft after tibial fixation.

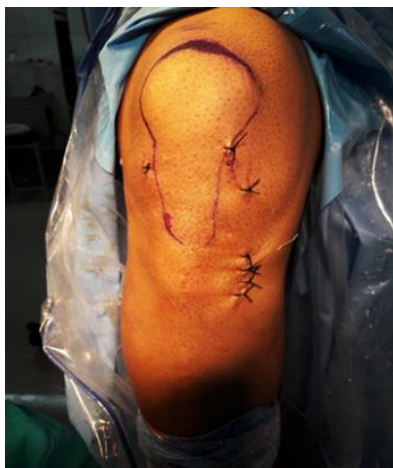

Figure 7: Anterior view of knee showing closure of the arthroscopic portals and the graft harvest site

3. Results

Meniscal injuries were found in 9 cases (36%). Medial meniscal tear was found in 7 patients and partial medial meniscectomy was performed. In 2 patients, tear of both medial and lateral menisci was found, with bucket handle tear of medial meniscus, partial meniscectomy was done.

Table 2: Arthroscopic Findings

S. N	Arthroscopic Findings		
	ACL	Medial Meniscus	Lateral Meniscus
1	Complete ACL Tear	Normal	Normal
2	Complete ACL Tear	MMT,Bucket Handle	Normal
3	Partial ACL Tear	Normal	Normal
4	Complete ACL Tear	Normal	Normal
5	Complete ACL Tear	Posterior horn MMT	Normal
6	Complete ACL Tear	Normal	Normal
7	Partial Tear	Degeneration of MM	Normal
8	Complete ACL Tear	Normal	Normal
9	Complete ACL Tear	Normal	Normal
10	Complete ACL Tear	Normal	Normal
11	Complete ACL Tear	Normal	Normal
12	Complete ACL Tear	MMT, Bucket Handle	LMT, Vertical Tear
13	Complete ACL Tear	Normal	Normal
14	Complete ACL Tear	Normal	Normal
15	Complete ACL Tear	MMT, Bucket Handle	Normal
16	Complete ACL Tear	Normal	Normal
17	Complete ACL Tear	MMT	Normal
18	Complete ACL Tear	MMT	Normal
19	Complete ACL Tear	Normal	Normal
20	Complete ACL Tear	Normal	Normal
21	Complete ACL Tear	MMT, Bucket Handle	LMT
22	Complete ACL Tear	Normal	Normal
23	Complete ACL Tear	MMT	Normal
24	Complete ACL Tear	Normal	Normal
25	Complete ACL Tear	MMT	Normal

The average preoperative Lysholm score was 63.6 with a range between 50-81. It improved at 1- year postoperative to an average of 92.04 with a range between 76- 98. The preoperative Lysholm score was poor (<65) in 60% and fair (65-83) in 40% of cases, it improved at 1-year postoperative to excellent (>94) in 68% and good (84-94) in 20% of cases. None of the patients had a poor functional knee score at one year postoperatively.

Table 3: Lysholm Score

Lysholm score	Pre-operative score		Post-operative score (2 year post op)	
	Number	Percentage	Number	Percentage
<65 (poor)	15	60%	None	0
65-83 (Fair)	10	40%	3	12%
84-95 (Good)	0	0	5	20%
95 - 100 (Excellent)	0	0	17	68%

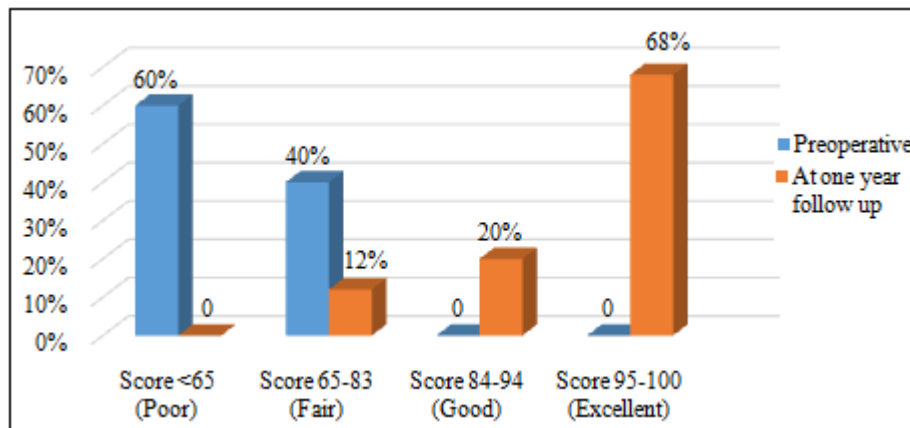


Chart 1: Lysholm Score Comparison preoperatively and at one year postoperatively

At 1 year follow up, two patients complained of anterior knee pain. The Lysholm scores were fair in both patients. At 1 year follow up, 80% of patients had a negative Lachman test, 16% of the patients had grade 1+ Lachman test. Pivot shift test was negative in all patients at final follow up.

Table 4: Lachman test

Lachman test	Lachman test grade			
	Negative	Grade I	Grade II	Grade III
Pre operative	0%	20%	52%	28%
Post operative (1 year follow up)	80%	16%	4%	0

4. Discussion

Anatomical ACL reconstruction requires an understanding of ACL insertion anatomy. Although the lateral intercondylar ridge and lateral bifurcate ridge have been described, they can be difficult to visualise. The remnants of the native ACL fibers can aid with anatomic ACL tunnel placement. Two anteromedial portals can be used: a high portal close to the patella tendon providing visualization and a second more medial portal just above the meniscus for instrumentation. The additional medial portal allows the ACL femoral attachment site to be viewed through the AM portal, while working instrumentation is inserted into the notch through the AAM portal. Drilling the ACL femoral tunnel through an AAM portal increases the obliquity of the ACL femoral tunnel relative to the lateral wall of the notch, resulting in a longer femoral tunnel length and a more elliptical ACL femoral tunnel aperture. Dargel et al.⁽⁹⁾ concluded that AM portal drilling results in a tunnel, which may allow stabilisation for both anterior tibial translation and rotational instability.

The outcomes following ACL reconstruction were determined from subjective Lysholm knee scoring and the stability tests. In our prospective study, the Lysholm score improved from the preoperative mean value of 63.6 to postoperative mean value of 92.04 at 1-year. At final follow up, 80% of patients had a negative Lachman test, 16% of the patients had grade 1+ Lachman test, and 1 patient had grade 2+ Lachman test. None of the patients had grade 3+ Lachman test at final follow up. All the patients with grade 1+ Lachman test were

asymptomatic. One patient had grade 2+ Lachman test. Clinically the patient was asymptomatic, with negative pivot shift test. Postoperative MRI at one year showed the tibial tunnel to be posteriorly located, at 50.9% of the AP depth of tibia.

5. Conclusion

Anatomical single bundle ACL reconstruction using medial portal technique results in excellent functional knee scores.

Funding: Nil

Conflict of interest: None

References

- [1] Mall NA, Chalmers PN, Moric M, et al. Incidence and trends of anterior cruciate ligament reconstruction in the United States. *Am J Sports Med.* 2014;42(10):2363–2370.
- [2] Ganesh G, Redfern J, Greis P, Burks R. Revision anterior cruciate ligament reconstruction. *Am J Sports Med.* 2011; 39(1):199-217.
- [3] Marchant B, Noyes F, Barber-Westin S, Fleckenstein C. Prevalence of nonanatomical graft placement in a series of failed anterior cruciate ligament reconstruction. *Am J Sports Med.* 2010; 38(10):1987-1996.
- [4] van Eck CF, Lesniak BP, Schreiber VM, Fu FH (2010) Anatomic single- and double-bundle anterior cruciate ligament reconstruction flowchart. *Arthroscopy* 26:258–268.
- [5] Hussein, M., van Eck, C.F., Cretnik, A., Dinevski, D. & Fu, F.H. 2012b, "Prospective randomized clinical evaluation of conventional single-bundle, anatomic single bundle, and anatomic double-bundle anterior cruciate ligament reconstruction: 281 cases with 3- to 5-year follow-up", *The American Journal of Sports Medicine*, vol. 40, no. 3, pp. 512-520.
- [6] Steiner, M.E., Battaglia, T.C., Heming, J.F., Rand, J.D., Festa, A. & Baria, M. 2009, "Independent drilling outperforms conventional transtibial drilling in anterior

- cruciate ligament reconstruction", *The American Journal of Sports Medicine*, vol. 37, no. 10, pp. 1912-1919.
- [7] **Beck, C., Paulos, L. & Rosenberg, T. 1992**, "Anterior cruciate ligament reconstruction with the endoscopic technique", *Operative Techniques in Orthopaedics*, vol. 2, pp. 86-98.
- [8] **Ziegler CG, Pietrini SD, Westerhaus BD, et al.** Arthroscopically pertinent landmarks for tunnel positioning in single-bundle and double-bundle anterior cruciate ligament reconstructions. *Am J Sports Med.* 2011;39(4):743–52.
- [9] **Dargel J, Schmidt-Wiethoff R, Fischer S, et al.** Femoral bone tunnel placement using the transtibial tunnel or the anteromedial portal in ACL reconstruction: a radiographic evaluation. *Knee Surg Sports Traumatol Arthrosc.* 2009;17:220–7.