International Journal of Science and Research (IJSR)
ISSN: 2319-7064
ResearchGate Impact Factor (2018): 0.28 | SJIF (2018): 7.426

Peripheral Ossifying Fibroma of oral cavity: A Case Report and Treatment Considerations

Dr Manjeet Singh

(BDS, MDS) (Periodontology), MO Dental Civil Hospital Sarkaghat District Mandi Himachal Pradesh, India

Abstract: ***Gingiva is often the site of localized growths. Suddenly appearing and slowly enlarging gingival overgrowths interfere in normal masticatory functions besides raising suspicion about pathogenicity of the lesion and causing undue distress to the patient. Therefore, correct diagnosis and prompt treatment are essential. This article presents a clinical case of Peripheral Ossifying Fibroma (POF) in a 17 year old girl. After etiotropic therapy, the lesion was excised. The excised specimen was sent for histopathological examination which confirmed the diagnosis of POF.***

Keywords: Gingiva, gingival overgrowth, peripheral ossifying fibroma, management

1. Introduction

Solitary gingival enlargements are relatively common findings usually manifesting from a reactive response to local irritation. One such condition is peripheral ossifying fibroma (POF) which appears in the oral cavity as an overgrowth of gingival tissues.[1] The condition was described by Menzel in 1872 and named as ossifying fibroma by Montgomery, in 1927. The term POF was coined by Eversole and Rovin in 1972.[2] POF is a reactive lesion composed of cellular fibroblastic connective tissue stroma, associated with the formation of randomly dispersed foci of mineralized product consisting of bone, cementum like tissue, dystrophic calcification or a combination of the aforementioned products.[1] Ossifying fibrous epulis, ossifying fibroma with calcification, cemento- ossifying fibroma and calcifying fibroma are the other terms used to describe this overgrowth.[3,4]

There are two types of ossifying fibromas; central and peripheral. The central type originates from endosteum or periodontal ligament adjacent to root apex, causing expansion of the medullary cavity, while the peripheral type occurs solely on soft tissues covering the root bearing areas of jaws.[5] POF accounts for 3.1% of all tumors and 9.6% of gingival lesions. It is more prevalent in whites (71%) compared to blacks (36%).[6] The lesion predominantly affects adolescents and young adults, with a peak prevalence between 10 to 19 years. Female to male ratio reported in literature varies from 1.22: 1 and 1.7: 1 to 4.3:1.[7] Approximately 60% of POF's occur in maxilla, more often in incisor- cuspid region (55 to 60%).[8] POF is a solitary slow growing nodular mass, either pedunculated or sessile. The surface mucosa may be smooth or ulcerated and pink to red in color. Migration of teeth with interdental bone erosion has been reported in certain cases.[6,7] The lesions usually measure less than two cm in diameter but cases up to six cm and nine cm have been reported.[1,5] This article presents a case report of POF with emphasis on the importance of discussion of reasonable differential diagnosis with the patient.

2. Case Report

A healthy 17 year old girl came to the dental Department at civil hospital, with a swelling behind her upper left front teeth. The lesion was of one month duration, slowly increasing in size. Discomfort in the involved area and mild pain was perceived on eating, when lower teeth came in contact with the swelling. No history of bleeding from the lesion either spontaneous, on brushing or while eating was elucidated. It was visibly apparent that the patient was concerned about the pathogenicity of the lesion and had to be reassured. Clinical examination revealed a nodular gingival enlargement in relation to palatal aspect of 22 & 23; originating inter-proximally; approximately 1.5 x 1.2 cm in diameter and red to pink in color with areas of white discoloration (Fig. 1). The lesion was firm in consistency, was pedunculated with a broad base, freely movable from the underlying bone and was tender on palpation. The teeth associated with the lesion i.e. 22 & 23 were non tender on percussion. Plaque Index (Silness and Loe 1964) scores demonstrated moderate plaque accumulation whereas Gingival Index (Loe and Silness 1963) showed moderate inflammation of the involved area. A pocket depth of six mm and seven mm was recorded on the palatal aspect of 22 & 23 respectively and bleeding on probing was evident. The intra oral periapical radiographic examination of 22 & 23 region (Fig. 2) was within normal limits, with no evidence pertaining to involvement of maxillary alveolar bone or pathologic migration of teeth. Following clinical and radiographic examination, a provisional diagnosis of chronic inflammatory gingival enlargement was made. The differential diagnosis consisted of traumatic fibroma,[8] pyogenic granuloma,[3] peripheral ossifying fibroma and peripheral giant cell granuloma.[1]

Initial treatment included complete oral hygiene instructions followed by supra- and subgingival scaling. After one week interval, the swelling had become more firm and fibrous, with a reduced size, measuring approximately 1.2 x 1.0 cm in diameter (Fig. 3). A routine haemogram done prior to the excision of the lesion demonstrated normal blood values. An excision biopsy of the lesion was then performed under local anesthesia using lignocaine hydrochloride solution with adrenaline (1:80,000). 22 & 23 were subjected to thorough subgingival scaling and curettage to ensure complete removal of the lesion from its base and root surfaces free of any residual accretions (Fig. 4). The surgical site was irrigated with 2% povidone iodine and normal saline solution, and periodontal dressing was given. Antibiotics

(Ofloxacin 200 mg plus Ornidazole 500mg twice daily for five days) and analgesics (Ibuprofen 400 mg three times daily for three days) were prescribed. Oral hygiene instructions were reinforced and the patient was recalled after 1 week for reevaluation. The excised specimen was preserved in 10% formalin solution and sent for histopathological analysis. Microscopic examination revealed ulcerated stratified squamous epithelium with cellular fibrous connective tissue and areas of bone formation (Fig. 5). Thus, a final diagnosis of peripheral ossifying fibroma was made. After one week (Fig. 6), the surgical site appeared to be healing well (by secondary intention). Three months post operative examination revealed a completely healed surgical site. There was no evidence of recurrence of the lesion and the patient was asymptomatic during a six months follow up interval (Fig. 7).

3. Discussion

POF is a common gingival growth that is thought to be either reactive or neoplastic in nature.[7] Literature suggests various terms to describe this clinical entity such as fibrous epulis,[5] peripheral fibroma with calcification,[4] peripheral ossifying fibroma,[1] calcifying fibroblastic granuloma,[4] peripheral cementifying fibroma,[2] peripheral fibroma with cementogenesis[6] and peripheral cemento- ossifying fibroma.[9] The sheer number of names used for fibroblastic gingival lesions indicates that there is much controversy surrounding the classification of these lesions.[3,7,9] According to Kumar et al.[7] the term "peripheral odontogenic fibroma" has been designated by the World Health Organization (WHO) as the rare and extraosseous counterpart of central odontogenic fibroma. Therefore, it is a separate clinical entity. Another nomenclature that describes the lesion as "cemento- ossifying fibroma" is now considered to be outdated and scientifically inaccurate. The so called cementicles in POF are not from cementum but instead represent dysmorphic round basophilic bone particles within ossifying fibroma.[8]

Although the etiopathogenesis of POF is uncertain, an origin from the cells of periodontal ligament has been suggested.[7,8] The reasons for considering periodontal ligament origin of POF include: exclusive occurrence of POF in gingiva (interdental papilla), proximity of gingiva to the periodontal ligament, presence of oxytalan fibers within the mineralized matrix of some lesions and the fibro- cellular response in POF which is similar to other reactive gingival lesions of periodontal ligament origin. Classically, local factors such as trauma or irritants like dental plaque, calculus, microorganisms, masticatory forces, ill- fitting dentures and poor quality restorations are implicated in POF induction or progression.[1,4] Chronic irritation of the periodontal and periosteal membrane causes metaplasia of the connective tissue and resultant initiation of bone formation or dystrophic calcification.[8] Serum estrogen and progesterone concentrations render the gingival tissue more susceptible to chronic irritation caused by plaque and calculus. Since POF has an obvious predilection for females and occurs in specific periods of life such as puberty and pregnancy, the existence of hormonal factors in the development of POF has been suggested in literature.[9] Unfortunately, little is known with respect to the pathogenesis and molecular or genetic profiles of these lesions. Therefore, Kumar et al.[7] recommend further analysis of the patient such as karyotyping, which may give insight into any chromosomal or genetic abnormalities that could be present, and whether or not these are constitutional and can be passed on to off-springs. The differential diagnosis for POF has been described in literature. Clinically, POF may be misdiagnosed as pyogenic granuloma or peripheral giant cell granuloma. Traumatic fibroma and other odontogenic tumors must also be considered. In general, the pyogenic granuloma presents as a soft, friable nodule that bleeds with minimal manifestations, but tooth displacement and resorption of the alveolar bone are not observed. Although, peripheral giant cell granuloma has clinical features similar to those of POF, the later lacks the purple or blue discoloration, commonly associated with peripheral giant cell granuloma.[1,3]

In the present clinical study, the patient was a female in second decade of her life and the possible cause of lesion occurrence could have been a reactive response of the gingival tissues to locally accumulated irritants i.e. plaque and calculus. Similar clinical findings as present in this case have been observed in other cases reporting POF,[4,5] though some reports have mentioned POFs ranging from 4 cm to 9 cm in diameter.[2,3] Radiographic features of the POF vary and have been described. Radiopaque foci of calcifications have been reported to be scattered in the central area of the lesion, but not all lesions demonstrate radiographic calcifications. Underlying bone involvement is usually not visible on a radiograph. In rare instances superficial bone erosion may be noted. However, in untreated cases, as the tumor advances, alveolar bone destruction with displacement of adjacent teeth ensues. In our case, radiographic examination was within normal limits, with no findings pertaining to maxillary alveolar bone destruction. This is in agreement with Farquher et al,[4] Das and Azher.[1]

A confirmatory diagnosis of POF is made by histopathological evaluation of biopsy specimens. The following features are usually observed during microscopic examination: (1) intact or ulcerated stratified squamous epithelium; (2) benign fibrous connective tissue with varying number of fibroblasts; (3) sparse to profuse endothelial proliferation; (4) mineralized material consisting of mature lamellar or woven osteoid, cementum like material or dystrophic calcification; (5) acute or chronic inflammatory cells in lesions.[7] Most of the described features were present in this case. Treatment consists of complete surgical excision of the lesion including the involved periodontal ligament and periosteum, as was done in the present case. Although POF is a benign, reactive lesion, a fairly high recurrence rate (8%- 20%) has been reported.[4,10] The patient must be reassured that prompt treatment will lead to uneventful healing of the swelling. However, periodic reevaluation (including rechecking for plaque, calculus, inflammation, other traumatic factors and thorough oral prophylaxis) of the surgical site is necessary, to alleviate any chances of recurrence.[4] In the present study, 6 months follow up did not demonstrate recurrence of the lesion.

4. Conclusion

POF is a slowly progressing lesion, the growth of which is generally limited. A slowly growing pink soft nodule in the anterior maxilla of an adolescent should raise the suspicion of a POF. Discussion of the differential diagnosis should be done tactfully to prevent unnecessary distress to the patient. Treatment consists of judicious excision of the lesion including periosteum. Close post operative follow up is essential because of the growth potential of incompletely removed lesions and a high rate of recurrence.[4]

References

[1] Das UM, Azher U. Peripheral ossifying fibroma. J Indian Soc Pedod Prevent Dent 2009; 27: 49-51.

[2] Martins Junior JC, Keim FS, Kreibich MS. Peripheral ossifying fibroma of the maxilla: case report. Intl Arch Otorhinolaryngol 2008; 12: 295-299.

[3] Moon WJ, Choi SY, Chung EC, Kwon KH, Chae SW. Peripheral ossifying fibroma in the oral cavity: CT and MR findings. Dentomaxillofacial Radiology 2007; 36: 180-182.

[4] Farquhar T, Maclellan J, Dyment H, Anderson RD. Peripheral ossifying fibroma: a case report 2008; 74: 809-812.

[5] Keluskar V, Byakodi R, Shah N. Peripheral ossifying fibroma. Journal of Indian Academy of Oral Medicine and Radiology 2008; 20: 54-56.

[6] Delbem ACB, Cunha RF, Silva JZ, Soubhia AMP. Peripheral cemento-ossifying fibroma in child. A follow-up of 4 years. Report of a case. European Journal of Dentistry 2008; 2: 134-137.

[7] Kumar SKS, Ram S, Jorgensen MG, Shuler CF, Sedghizadeh PP. Multicentric peripheral ossifying fibroma. Journal of Oral Science 2006; 48: 239-243.

[8] Yadav R, Gulati A. Peripheral ossifying fibroma: a case report. Journal of Oral Science 2009; 51: 151-154.

[9] Garcia de Marcos JA, Garcia de Marcos MJ, Rodriguez SA, Rodrigo JC, Poblet E. Peripheral ossifying fibroma: a clinical and immunohistochemical study of four cases. Journal of Oral Science 2010; 52: 95-99.

[10] Kohli K, Christian A, Howell R. Pediatric Dentistry. Peripheral ossifying fibroma associated with a neonatal tooth: case report 1998; 20: 428-429.

Figures

Figure 1: Baseline view of the lesion

Figure 2: Intraoral periapical radiograph of 22, 23 region showing no abnormal findings.

Figure 3: 1 week after oral prophylaxis

Figure 4: Intra-operative view following excision of the lesion

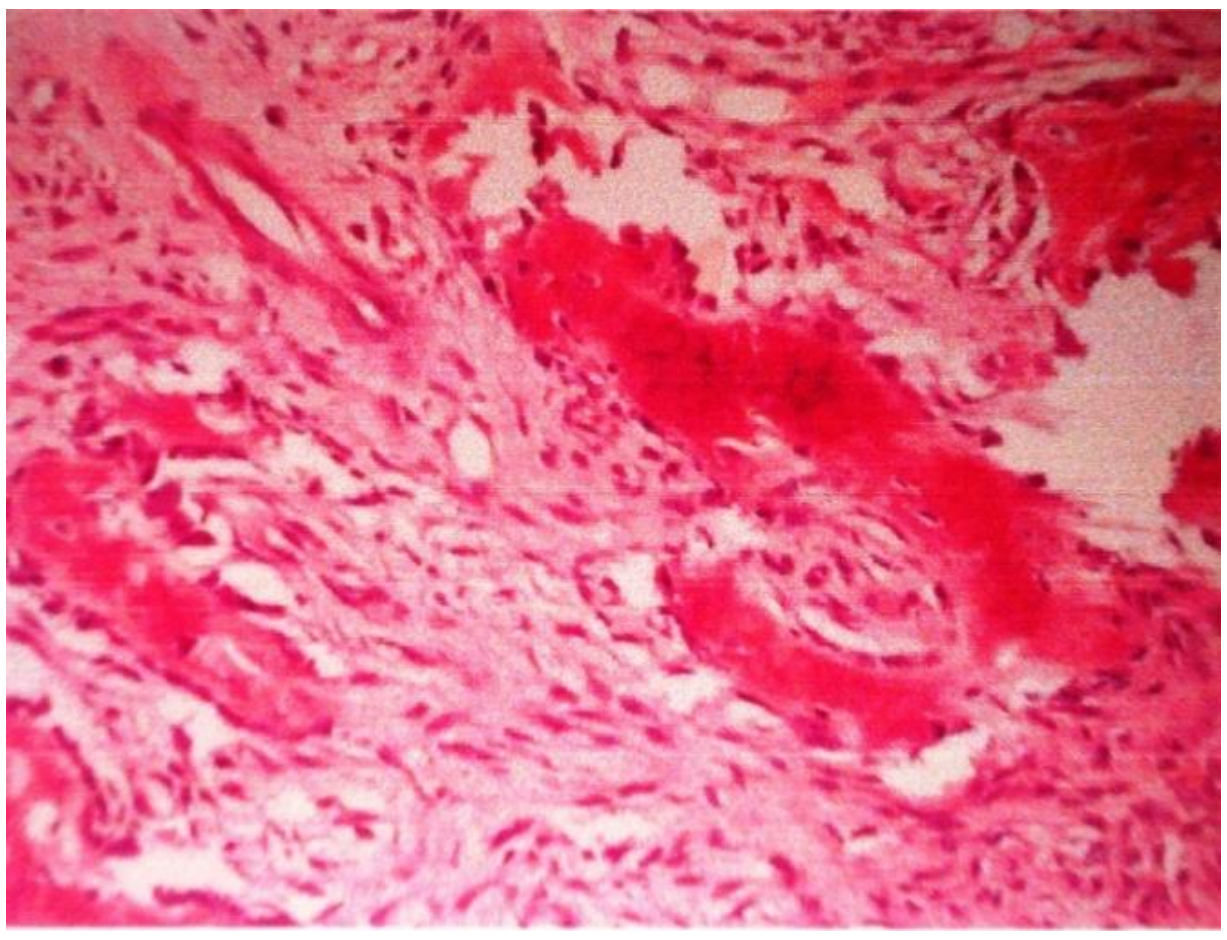

Figure 5: Histopathological picture

Figure 6: One week post operative image

Figure 7: No recurrence at 6 month follow-up interval.