

CT Scan Evaluation of Anatomical Variations of Paranasal Sinuses in Patients with Complaints Related to Paranasal Sinuses—An Exploratory Study

Muhammed Shahab¹, Vinayaka U. S²

¹Postgraduate, Department of Radiodiagnosis, Yenepoya Medical College, Mangalore, Karnataka, India

²Associate Professor, Department of Radiodiagnosis, Yenepoya Medical College, Mangalore, Karnataka, India

1. Introduction

The nasal fossae and paranasal sinuses constitute an anatomical and functional unit. Covered by the same mucosa, the paranasal sinuses communicate with the nasal cavities via small openings and narrow ducts that allow both aeration and sinus drainage¹.

Computed tomography provides detailed picture of the anatomy, the anatomical variants and the extent of the disease in and around the paranasal sinuses. Optimal information about the adjacent bones, soft tissues is available with CT, making it the imaging modality of choice for assessing PNS along with the axial sections, direct coronal scanning and sagittal reconstructions provide accurate delineation of the micro anatomic locales and disease in the PNS. Coronal CT is the investigation of choice for the detailed evaluation of the osteomeatal complexes and the recesses of the PNS².

Coronal plane computerized tomographic scanning has dramatically improved the imaging of paranasal anatomy as compared to sinus radiographs. Increasingly, subtle bony anatomic variation and mucosal abnormalities of this region are being detected³.

With the advent of functional endoscopic sinus surgery (FESS) and coronal computed tomography imaging, considerable attention has been directed towards paranasal region anatomy. Detailed knowledge of anatomic variations is critical for surgeons performing endoscopic sinus surgery as well as for radiologist involved in the preoperative work up⁴.

Aim:

To explore the anatomical variations of paranasal sinuses using CT scan.

Objectives

- 1) To identify anatomical variations of paranasal sinuses using CT scan
- 2) To document the frequencies of the anatomic variants of paranasal sinuses.

2. Materials and Methods

This was a prospective study performed to assess the anatomical variations of paranasal sinuses in patients

presenting with complaints related to paranasal sinuses. 550 patients were included in my study after ethical clearance from ethical committee of Yenepoya University. Patient was informed about the study with written consent taken.

Duration of Study

24 months (November 2015 to October 2017).

Equipment

GE BRIGHT SPEED 16 SLICE (Single source 16 detector row CT unit GE medical system USA)

Inclusion Criteria

- Patients included in the study were those with complaints related to PNS referred for CT scan at Yenepoya medical college

Exclusion Criteria

- Facial trauma
- Previous sinonasal surgery (excluding nasointra-antral window antrostomy).
- Sinonasal anatomy alteration or obscuration due to inflammatory diseases (When bony details were obscured by polypoid mucosal disease).
- Paranasal sinus neoplasm
- Paediatric age group, pregnant women

3. Statistical Analysis

IBM SPSS 16 software was used for analysis of data. Descriptive statistics like Frequency (%) for categorical variable, and expressed in charts and diagrams.

4. Discussion

The paranasal sinus region is subject to a large variety of variations. Congenital anomalies and normal anatomical variations in this region are important as they may have pathological consequence or may be the source of difficulty complication during surgery.

Rao et al observed that the most common type of DNS in patients with complaints of sinusitis is type V (46%) followed by type VI (17%), type III and type IV (10%), type VII (7%), and the least common is type I, where as in patients without sinusitis most common type of DNS observed was Type I (56%)⁵.

Volume 7 Issue 9, September 2018

www.ijsr.net

Licensed Under Creative Commons Attribution CC BY

Perez et al observed that the most common variation observed was nasal septum variation having 55% out 110 patients studied¹. Shpilberg KA et al observed that the most common anatomic variant was nasal septal deviation with (98.4%) out of 192 patients presenting with complaints of sinusitis.⁶

In two other studies Murthy DD et al and Lingaiah RK et al observed that Deviated Nasal Septum was the most common variation with (73.2%) and (62%) respectively.⁷ Findings noted in our study is also consistent with the above mentioned studies of para nasal sinuses with deviated nasal septum being the most common type of variation, with (59.1%) in 550 patients studied, of which 28.7% was type I, 12% was type II, 8.7% was TYPE III, 2.2% was type IV, 3.8 % was type V, 2.4% was type VI and 1.3 % was type VII.

Concha bullosa (pneumatized middle turbinate) has been implicated as a possible aetiological factor in the causation of recurrent chronic sinusitis. It is due to its negative influence on PNS ventilation and mucociliary clearance in the middle meatus region. The presence of a concha bullosa has ranged between 4% and 80% in different studies; our data gave 24.7% which is similar compared to (24.5%) observed by Peres et al, more compared to incidence reported by Dua K (16%)⁸ and less compared to Zinreich S et al (36%)⁴. Such a wide range of incidences is due to the criteria of pneumatization adopted. Sinus ventilation in the anterior ethmoid, frontal recess and infundibulum regions can be impaired by a curved uncinat process as observed by Zinreich et al⁴. In the our study curved uncinat process was found in 17 patients unilaterally (2.9%) and 2 patient bilaterally (0.4), a total of 3.3%. Bolger et al reported a total incidence of 2.5% in his study.³

Pneumatization of uncinat process or curvature to medial side will have an extensive contact with the middle turbinate, which can cause sinusitis. Anatomic variations like uncinat bulla and infraorbital cells may elevate the pathogenic effect when seen along with pneumatized uncinat process compared to the effect of single variant. We encountered uncinat process pneumatization in 24 patients (4.4%) out of which 22 were unilateral (4%) and 2 were bilateral (0.4%). This is in consistent with 5% reported by Mecit et al⁹ and more compared to Zinreich (0.4%)⁴ and Bolger et al (2.5%)³.

5. Results

Table 1: Gender distribution of anatomical variation of PNS (n=550)

Sex	Frequency	Percentage
Female	215	39.1
Male	335	60.9
Total	550	100

Table 2: Frequency and types of deviated nasal

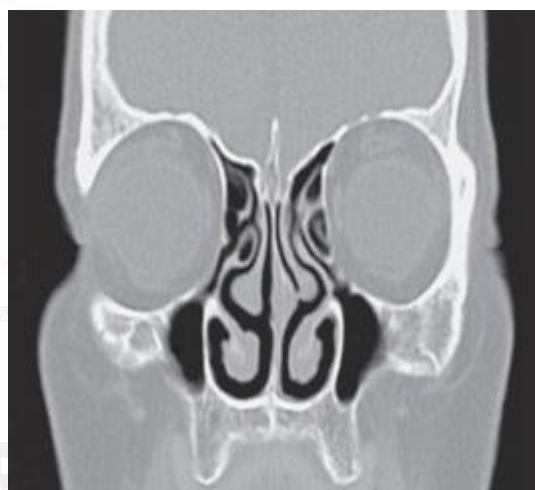Types	Frequency	Percent
I	158	28.7
II	66	12.0
III	48	8.7
IV	12	2.2
V	21	3.8
VI	13	2.4
VII	7	1.3

Table 3: Frequency of Concha bullosa

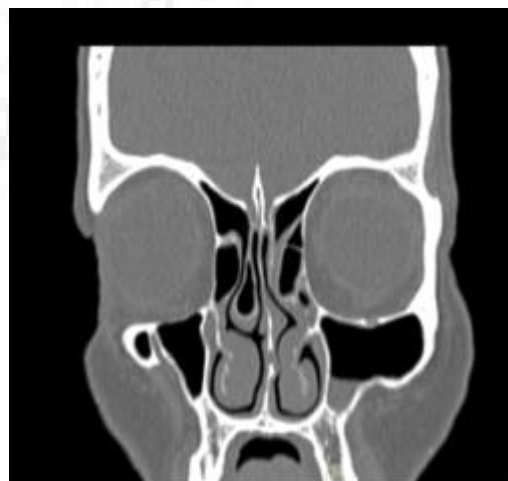
	Frequency	Percent
B/L	37	6.7
L	51	9.3
R	48	8.7

Table 4: Summary of frequency of anatomical variations of PNS

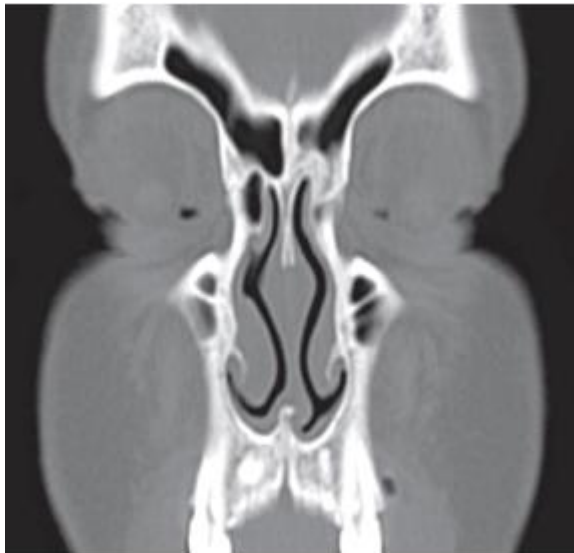
	Anatomical Variation	Unilateral		Bilateral		Total	
		NO	%	NO	%	NO	%
1	Concha Bullosa	99	18	37	6.7	136	24.7
2	Paradoxicalmiddle Turbinate	23	4.2	2	0.4	25	4.6
3	Curved Uncinate Process	15	2.9	2	0.4	17	3.3
4	Uncinate Process Pneumatition	22	4.0	2	0.4	24	4.4
5	Haller Cell	19	3.5	7	1.3	26	4.8
6	Agar Nasi Cell	18	3.3	9	1.6	27	3.9
7	Onodi Cell	29	5.2	4	0.7	33	5.9
8	Hypoplastic Frontal Sinus	7	1.3	9	1.6	13	2.9
9	Sphenoid Sinus Septations	77		14%		77	14%



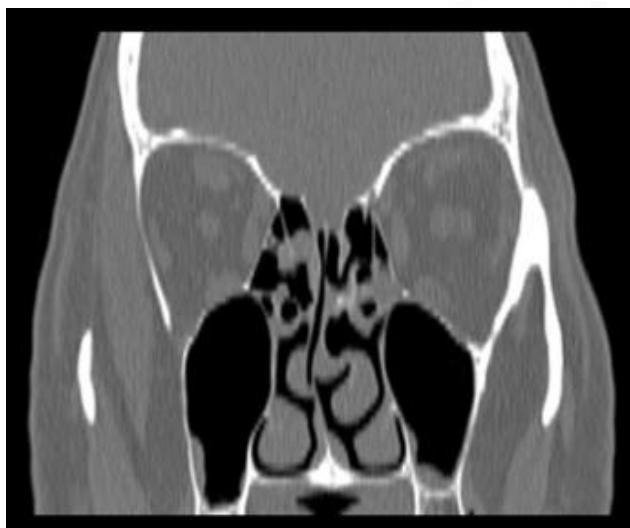Coronal CT scan PNS showing right uncinat process pneumatization.



Ethmoid roof keros type II with right concha bullosa



CT scan PNS Coronal sections showing agger nasi cell on the right side



Coronal CT Scan PNS showing left Paradoxical middle turbinate

6. Conclusion

Computed Tomography of the paranasal sinus has improved the imaging of paranasal sinus anatomy and has allowed greater accuracy in evaluating paranasal sinus disease for anatomical variants and inflammatory diseases affecting the sinuses. Advances in FESS and CT technology has concurrently increased interest in the paranasal region anatomy and its variations. Radiologists must report the anatomical variations that may predispose patients to increased risk of intraoperative complications and help avoid possible complications and improve success of management strategies.

References

- [1] Perez-Pinas I, Sabate J, Carmona A, Catalina H C J, Jimenez C J. Anatomical variations in the human paranasal sinus region studied by CT. *Journal of Anatomy* 2000;197(2):221-227.
- [2] Kantarci M, Karasen RM, Alper F, Onbas O, Okus A, Karaman A Remarkable anatomic variations in

- paranasal sinus region and their clinical importance. *European journal of Radiology* 2004, 50(3):296-302.
- [3] Bolger WE Butzin CA parsons DS, Para nasal sinus bony anatomic variations and mucosal abnormalities CT analysis for endoscopic sinus surgery. *Laryngoscope* 1991;101:56-64.
- [4] Zinreich SJ, Kennedy DW, Rosenbaum AE, Gayler BW, Kumar AJ, Stammberger H. Paranasal sinuses: CT imaging requirements for endoscopic surgery. *Radiology*. 1987 Jun;163(3):769-75.
- [5] Earwaker J. Anatomic variants in sinonasal CT. *Radiographics*. 1993 Mar;13(2):381-415.
- [6] Murthy DD, Rao BR, Rao SS. Analytical study of anatomical variations of nose and PNS in CT scan and chronic sinusitis. *IOSR-JDMS*. 2016 Jul;15(7):30-5.
- [7] Kainz J, Stammberger H. Das Dach des vorderen Siebbeines: ein Locus minoris resistentiae an der Schadelbasis. *Laryngol Rhinol Otol* 1988;67: 142-9.
- [8] Unal B, Bademci G, Bilgili YK, Batay F, Avci E. Risky anatomic variations of sphenoid sinus for surgery. *Surgical and Radiologic anatomy*. 2006 May 1;28(2):195-201.
- [9] Rao JJ, Kumar EV, Babu KR, Chowdary VS, Singh J, Rangamani SV. Classification of nasal septal deviations relation to sinonasal pathology. *Indian journal of otolaryngology and head and neck surgery*. 2005 Jul 1;57(3):199-201.
- [10] Nitinavakarn B, Thanaviratnanich S, Sangsilp N. Anatomical variations of the lateral nasal wall and paranasal sinuses: A CT study for endoscopic sinus surgery (ESS) in Thai patients. *J Med Assoc Thai*. 2005 Jun 9;88(6):763-8.
- [11] Som P M, Park E E, Naidich T P. Crista Galli pneumatization is an extension of the adjacent Frontal sinuses. *Am Neuroradiol* 2009;30:31-33.
- [12] Dua K, Chopra H, Khurana AS, Munjal M. CT Scan variations in Chronic Sinusitis. *Ind J RadiolImag* 2005;15:315-320.
- [13] Asruddin , Yadav SPS, Yadav RK, Singh J. Low dose CT in chronic sinusitis.
- [14] Mecit K, Mural K, Fatih A, Omer O, Adnan O, Adem K. Remarkable anatomic variations in paranasal sinus region and their clinical importance. *European Journal of Radiology* 2004; 50(3):296-303.
- [15] Radiological observation of ethmoid roof on basis of keros classification and its application in endonasal surgery. article · august 2017 with 9 reads. doi:10.16965/ijar.2017.284.