

Stability after Mandibular Setback with Bilateral Sagittal Split Osteotomy

Shihiji Srivastava¹, Mukul Padhye²

¹Resident, D. Y. Patil University School of dentistry Navi Mumbai, India

²Professor & Dean of faculty, D. Y. Patil University School of dentistry Navi Mumbai, India

Abstract: *Introduction:* bilateral sagittal split osteotomy (bssso) is the most commonly performed jaw surgery. Bssso of mandible is a surgical method used to correct the sagittal, transverse and vertical position of the lower jaw. *Aim:* The aim of this study was to assess the stability of bssso for setback of mandible and its relationship to intra-operative positioning of the proximal segment during fixation. *Methodology* of the 25 bssso patients whose records were originally identified, 5 subjects were dropped because of loss of follow up. Lateral cephalograms were taken at time points t1, t2, t3, and t4. These cephalograms were traced and superimposed using burr stones analysis for the assessment of amount of setback needed. *Results:* our study shows that it's a general tendency for the recovery in the position of the posterior border of the ascending ramus in the postsurgical phase to be greater in cases in which its posterior displacement during surgery was greater. *Conclusion:* mandibular repositioning for correction of mandibular prognathism results in significant soft and hard tissue changes in the lower face. If the position of the proximal segment of the mandible is changed during the fixation procedure during mandibular setback surgery, the proximal segment has a tendency to move back toward its presurgical position in the period following surgery.

Keywords: BSSO, Osteotomy, Orthognathic Surgery

1. Introduction

The word "osteotomy" means the division, or excision of bone. A **dentofacial osteotomy or orthognathic surgery** is an oral surgery where bone is cut, moved, modified, and realigned to correct a dentofacial deformity^[1]. Orthognathic surgery involves the surgical correction of the components of the facial skeleton to restore the proper anatomical and functional relationship in patients with dentofacial skeletal abnormalities. An important component of orthognathic surgery is the **Bilateral Sagittal Split Osteotomy (BSSO)**, which is the most commonly performed jaw surgery, either with or without upper jaw surgery. **BSSO** of mandible is a surgical method used to correct the sagittal, transverse and vertical position of the lower jaw^[2].

Indications for a bilateral sagittal split include horizontal mandibular excess, deficiency, and/or asymmetry. It is also performed for mandibular advancement and mandibular setback of small to moderate magnitude. More than 8 to 9 mm of posterior repositioning of the mandible with a Bilateral Sagittal Split Osteotomy can be difficult.^[3] Asymmetry cases require careful workup and planning, but can be easily addressed with a Bilateral Sagittal Split Osteotomy^[3].

The stability of BSSO is influenced by the way of fixation of bony fragments, the type of skeletal abnormality, quality of orthodontic preparation, magnitude and direction of movement of bony fragments, change of occlusal plane, soft tissue tension, preoperative impairment of temporomandibular joint, postoperative orthodontic retention, achievement of perfect postoperative occlusion and age of patient in the time of operation. Relapse consists of skeletal and dental factors and is considered to be clinically relevant if it exceeds 2 mm, otherwise it can be corrected orthodontically^[4].

Aim and Objectives

The aim of this study was to assess the stability of BSSO for setback of mandible and its relationship to intra-operative positioning of the proximal segment during fixation.

- 1) To determine any relationship between positional changes of the proximal segments during surgery and the positional rebound of the mandible during the postsurgical period.
- 2) To assess presurgical, immediate preoperative, immediate post operative and after one year stability of setback of mandible after BSSO.

The objective of his study was to evaluate whether changes in the technique for mandibular setback surgery since the introduction of rigid internal fixation have improved postoperative stability in Class III correction with setback alone and 2-jaw surgery. Despite improvements in surgical techniques for mandibular setback since 1995, postoperative stability still leaves something to be desired, but there is better control of the ramus position when 2-jaw surgery is performed.

2. Literature Survey

Proffit WR (1991) [6] The objective of his study was to evaluate whether changes in the technique for mandibular setback surgery since the introduction of rigid internal fixation have improved postoperative stability in Class III correction with setback alone and 2-jaw surgery. Despite improvements in surgical techniques for mandibular setback since 1995, postoperative stability still leaves something to be desired, but there is better control of the ramus position when 2-jaw surgery is performed.

Masaki Fujioka, Tohru Fujii, Akiyoshi Hirano (2000) [15] They found that the postoperative excessive shear force stress, produced by the compressive action of the masseter

muscle, transformed the mandibular shape as the distal segment rotated clockwise and proximal segment rotated counterclockwise. Consequently, the mandible was bent at the miniplate. It was concluded that bicortical osteosynthesis was more rigid against this shearing stress than monocortical osteosynthesis.

Heon Jae Cho (2006) [1] Concluded in their study that when rigid fixation procedures alter the position of the proximal segments during sagittal split osteotomy of the mandible, the proximal segments tend to go back toward their presurgical positions following surgery.

Christof Urs Joss and Urs Walter Thüer (2008) [16] The long-term results in mandibular setback patients were more stable when compared with the mandibular advancement patients examined previously. The initial soft tissue profile, the initial growth direction, and the remodelling processes of the hard tissues must be considered as reasons for long-term elapse. Growth direction positively influenced the long-term results in females: further distalization of the mandible occurred.

Hoffmannová J (2008) [17] Early relapse is usually caused by movements at the osteotomy site or temporomandibular joint sag and should be called surgical displacement. Long term relapse happens due to the progressive temporomandibular joint condylar resorption, which causes a loss of condylar and mandibular ramus height.

Inclusion Criteria and Exclusion Criteria

Table 1

<i>Inclusion Criteria</i>	<i>Exclusion Criteria</i>
➤ Diagnosis of Class III skeletal malocclusion with prominent mandibular prognathism in a non-growing adult.	➤ Subjects who had undergone previous orthodontic treatment or orthognathic surgery were excluded.
➤ Treatment involving BSSO followed by rigid fixation of the proximal and distal segments with titanium miniplates and screws.	➤ Medically compromised patients
➤ Availability of technically satisfactory lateral cephalograms at time points immediately prior to surgery (T2), immediately after surgery (T3), and at the end of active orthodontic treatment (T4) (Table 3)	➤ Patients not willing to be a part of this study

All had an initial chief complaint of excessive mandibular prominence.

The investigation involved a comparison of measurements on the lateral cephalograms made at T2, T3, and T4 for all patients who met the criteria for inclusion in the experimental sample (Table 3)

Table 2

Time points at which the measurements were obtained
T1- Start of presurgical orthodontic treatment
T2- Immediately before surgery
T3- Immediately after surgery
T4 -End of active orthodontic treatment

Of the 25 BSSO patients whose records were originally identified, 5 subjects were dropped because of loss of follow up.

S Vinay Darshan1 (2014) [18] Mandibular advancement remained stable over the long period when compared to mandibular setback.

Nasser Nooh (2009) [19] In this study the results showed in terms of advancement that there was no significant difference between the groups after one year. However, in terms of setback, this study showed significant difference.

Chung H, Yoo CK (2008) [20] The findings of their study suggest that there were no significant differences in postoperative changes in mandibular shape in both the monocortical and bicortical fixation groups after sagittal split ramus osteotomy. They concluded that monocortical osteosynthesis using a miniplate could be used to obtain stable postoperative changes after mandibular setback.

3. Material and Methods

This study was conducted in the Department of Oral and Maxillofacial Surgery at D.Y.Patil University, School of Dentistry, Nerul, Navi Mumbai, using standardized Digital Lateral Cephalometric radiographs on 25 class III patients in the age group of 18-35 years with horizontal mandibular excess who were treated with Bilateral Sagittal Split Osteotomy for mandibular retro positioning-setback.

The final sample, therefore, included 20 patients (12 female and 8 male). Lateral Cephalograms were taken at time points T1, T2, T3, and T4. These cephalograms were traced and superimposed using Burr stones analysis for the assessment of amount of setback needed. Midlines were drawn for the double images in the inferior and posterior borders of the mandible. 3 measurements were designed, all being linear measurements which were made parallel to the Frankfort horizontal (FH) plane. Dimension A was made with the T2 and T3 films superimposed on the anterior cranial base, as shown in (Figure 1). Dimensions B and C were made with the T3 and T4 films superimposed on the anterior cranial base in the same manner, as shown in (Figure 2).

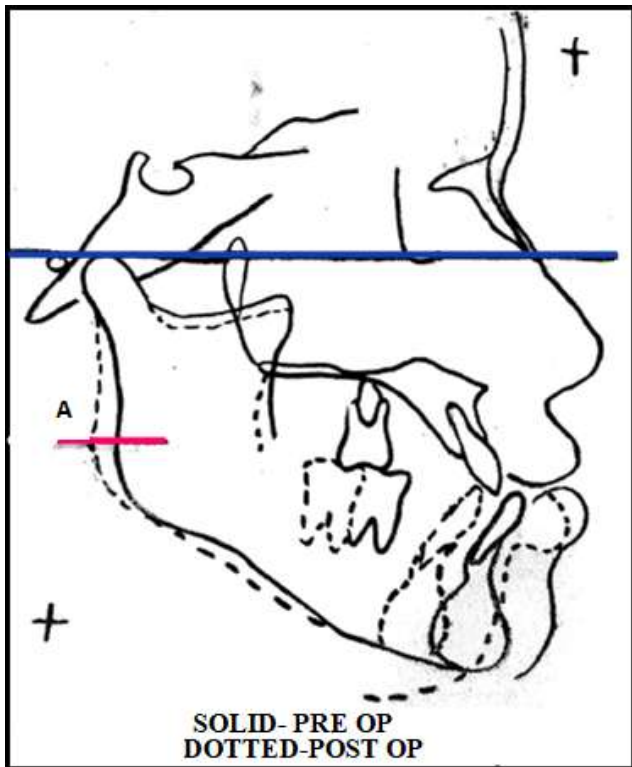


Figure 1: Created by Superimposition of T2 and T3 to evaluate point A in order to assess the amount of intraoperative movements of proximal segment could be recorded.

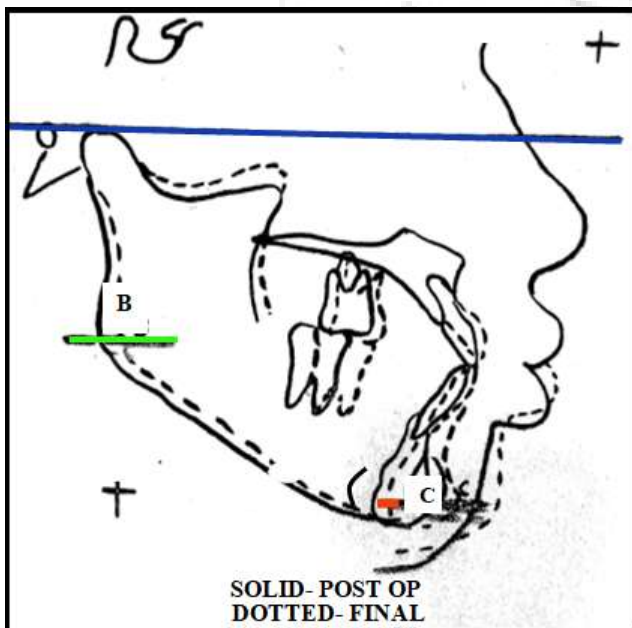


Figure 2: Created by Superimposition of T3 and T4 to evaluate point B & C in order to assess the amount of relapse/stability postoperatively in the ramal and the pogonion region once the orthodontic treatment got over.

Presurgical decompensation was achieved in most of the subjects as per calculation of the mean initial mandibular incisor plane angle (IMPA) was $81.9 \pm SD 8.36$, and mean presurgical IMPA was $89.0 \pm SD 6.17$ showing that decompensation was achieved orthodontically before the surgery. Average overall treatment duration (T1–T4) was 30.3 months.

The average interval between presurgical records and immediate postsurgical records was six days. The average duration of postsurgical treatment (T3–T4) was 10.9 months. The surgical procedures were performed by the same, team of experienced surgeons.

Ethical approval was obtained from the Institutional Review Board, D.Y.Patil University. An informed consent was taken from the patient.

4. Observation

Measurements and Data Collection

Lateral Cephalograms were taken at time points T2, T3, and T4. These cephalograms were traced and superimposed using burrstones analysis. Midlines were drawn for the double images in the inferior and posterior borders of the mandible. Three linear measurements were designed which were made parallel to the Frankfort horizontal (FH) plane. Measure A was made with the T2 and T3 films superimposed on the anterior cranial base, as shown in (Figure 1). Measures B and C were made with the T3 and T4 films superimposed on the anterior cranial base in the same manner, as shown in (Figure 2). A linear graph and correlation test was used to check any relationship between the positional changes of the proximal segments of the mandible during surgery and the positional changes of the proximal and distal segments of the mandible during the postsurgical phase of orthodontic treatment.

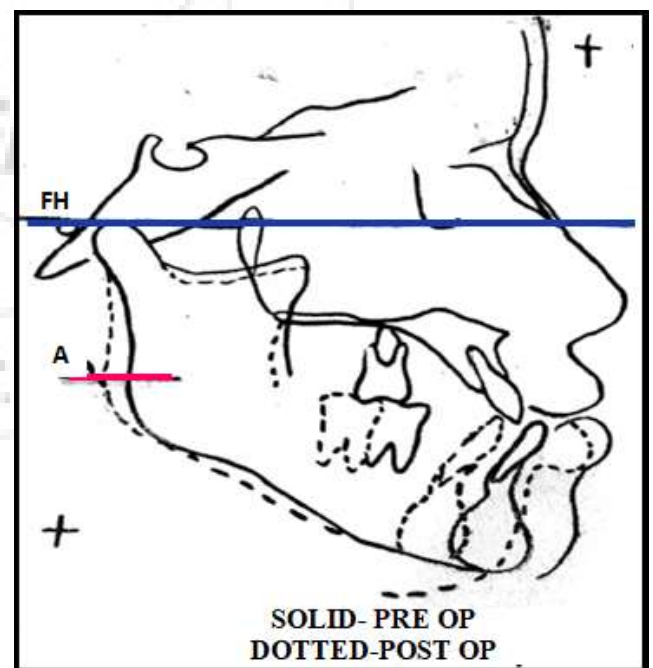


Figure 3

Dimension A (T3–T2): Is the amount of linear changes at the distal border of proximal segments that occurred during surgery (T2–T3). Measure A was a measurement of the most displaced distance between two images of T2 and T3 tracings at the distal border of the proximal segments on the line parallel to FH plane in superimposition between T2 and T3 tracings.

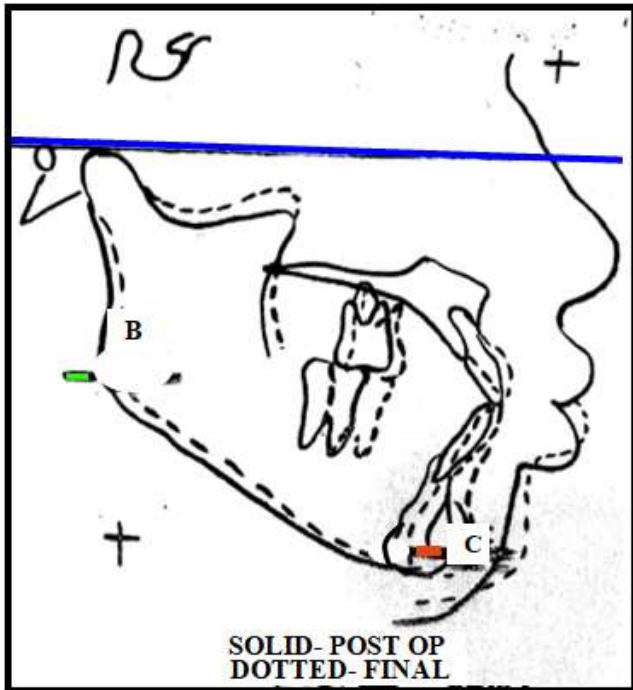


Figure 4

Dimension B (T4–T3): The amount of linear change at the distal border of proximal segments that occurred during postoperative phase of orthodontic treatment. It is the most displaced distance between two images of T3 and T4 tracings at the distal border of proximal segments on the line parallel to FH plane in superimposition between T3 and T4 tracings.

Dimension C (T4–T3): The amount of linear change at the pogonion that occurred during the postoperative phase of orthodontic treatment (T3–T4). It is the most displaced distance between two images of T3–T4 at the pogonion on the line parallel to FH plane in superimposition between T3 and T4 tracings.

5. Results and Statistics

Table 3: Showing the measurements

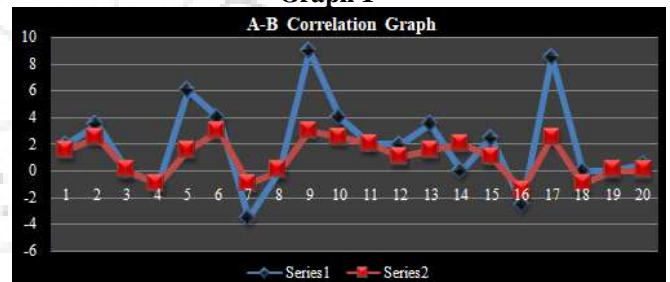
1.	2	1.5	1.5
2.	3.5	2.5	2
3.	0	0	0
4.	-1	-1	0
5.			
6.	4	3	1.5
7.	-3.5	-1	1
8.	0	0	0
9.			
10.	4	2.5	1
11.	2	2	0.5
12.	2	1	1.5
13.	3.5	1.5	2
14.	0	2	2
15.	2.5	1	0.5
16.	-2.5	-1.5	1
17.			
18.	0	-1	-1
19.	0	0	0
20.	0.5	0	0

- This table enumerates the no. of patients on which the study was conducted.
- It depicts the values measured on the lateral cephalograms by superimposing them. All the values were calculated for 20 patients and tabulated.
- Dimension A which was achieved from T2 and T3 and Dimension B from T3 and T4 and the Dimension C depicts the linear displacement of the pogonion measured on T3 and T4 superimposition.
- 10% (2) patients showed that there were instances when even after no post op proximal changes were noted still some relapse was shown after the final treatment suggesting that there are other parameters too affecting the properties of relapse post operatively.
- 15% (3) patients showed maximum relapse postoperatively
- 15% (3) patients show stability of the jaw post-operatively showing 0 displacement
- 75% patients showed some amount of relapse postoperatively if there were positional changes in the proximal segments intraoperatively concluding the importance of holding the proximal segment at its position during fixing the osteotomised segments.
- Our study shows that it's a general tendency for the recovery in the position of the posterior border of the ascending ramus in the postsurgical phase (Measure B) to be greater in cases in which its posterior displacement during surgery (Measure A,) was greater.

Statistical Representation of Graphs

	A-B	A-C
r-VALUE	0.031	0.70
P-VALUE	0.001524967	0.000284378
t-VALUE	3.770657343	4.548978489

Graph 1

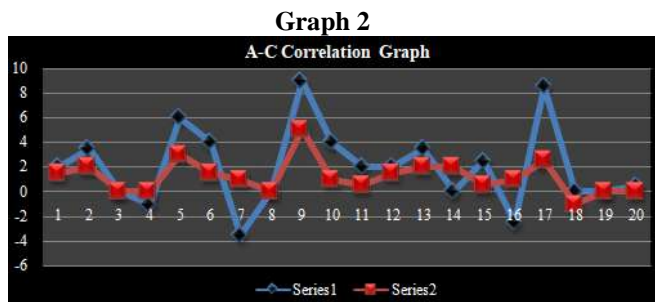


Graph 1: Showing relation between points A and B measured from T2 and T3.

Analysis of graph 1- shows direct relation and maximum displacement or relapse immediate post op bone remodels and stabilises after a year post operatively during postsurgical phase of orthodontic treatment (Measure B, T4–T3), $r = 0.031$, and $P = 0.00152$

It shows a general tendency for the recovery in the position of the posterior border of the ascending ramus in the postsurgical phase (Measure B) to be greater in cases in which its posterior displacement during surgery (Measure A,) was greater. The strength of the correlation between these two variables is $r = 0.031$, $P = 0.00152$ signifies that, in this sample, the amount of linear displacement of the posterior border of the proximal

segments during surgery (T3–T2) is closely related to the amount of linear rebound of the posterior border of the proximal segment during the postsurgical phase of orthodontic treatment (T4–T3).



Graph 2: Showing relation between points A and C measured from T3 and T4.

Analysis of graph 2- pogonion shift was noted in the final lateral cephalogram. In some patients it was markedly changed whereas in some there were no changes.

Analysis 2

A linear graph and Pearson correlation (r) were used to investigate the relationship between the amount of linear displacement of the posterior border of the proximal segments during surgery (Measure A), and the amount of linear displacement of pogonion during the postsurgical phase of orthodontic treatment (Measure C.).

This shows that there is a general tendency for the anterior displacement of pogonion in the postsurgical phase (T4–T3) to be greater in cases in which the posterior displacement of the posterior border of the proximal segment was greater during surgery (T3–T2). The strength of the correlation between the two variables is $r = 0.70$, $P = 0.00028$, signifies that, in this sample, the amount of linear displacement of the posterior border of the proximal segments during surgery is closely related to the amount of linear rebound of pogonion during the postsurgical phase of orthodontic treatment.

6. Discussion

The ultimate form of the dentofacial complex is the consequence of the genetic-environmental interaction, where certain familial characteristics do play a role. Hence for any individual, age, sex, race or other parameters, which influence facial growth, can be considered. One of the most desirable objectives of Orthognathic surgery is facial aesthetics apart from functional ability^[1,5].

This study evaluated the measurements of pre-operative and postoperative movements of the jaw to assess the amount of relapse.

This study is similar to the study by Heon Jae Cho^[1] in which they included and evaluated the angles formed by the posterior ramus displacement.

In our study the data collected and tabulated denotes that amongst the 20 patients the 15% (3 patients) had their proximal segment in the same position pre-operatively and intra-operatively. These patients showed no relapse the

entire treatment. This concluded that positioning of the proximal segment intraoperatively while fixing the segments into its new position is of utmost importance.

10% (2 patients) had no changes in the proximal segment pre-operatively and postoperatively on the cephalograms but still showed changes (relapse) post treatment completion. This means that there are other factors too contributing to relapse other than the positional changes of the proximal segment.

60% (12 patients) of the patients had change in values post operatively if the proximal segment showed improper positioning intraoperatively. The amount of change seen postoperatively as relapse is directly proportional to intra operative improper positioning of the proximal segments. This concludes that it's important to maintain the position of the proximal segment while fixing the osteotomised segments to its new position.

According to Analyses 1 and 2, a strong relationship exists between the amount of positional change of the proximal segment during surgery and the amount of positional relapse of the proximal segments of the mandible during the postsurgical phase of orthodontic treatment. This rebound of the proximal segment can affect the final position of the distal segment of the mandible which holds the dentition and pogonion.

Rivera et al^[20] reported that patients underwent orthognathic surgery to improve esthetic, functional, and temporomandibular joint (TMJ) problems. However, these benefits from the orthognathic surgery are not always realized. One of main reasons for an unsatisfactory treatment outcome could be the frequently observed relapse of surgical changes. It also has been reported that the relapse rates following mandibular setback surgery are among the highest for any surgical procedure. According to the author's clinical observation, most relapse after mandibular setback surgery seems to occur during the immediate postsurgical phase within the first two months following surgery. **Mobarak**^[8] reported similar findings. There seems to be additional minor relapse during the period from two months to one year after surgery. This author also has observed minimal relapse beyond the first post-postoperative year, similar to that reported by **Eggensperger et al**^[13].

Analysis 2. The rebound tendency definitely affects the final occlusion and facial esthetics. In Class III mandibular setback surgery, surgeons tend to push proximal segments backward during the fixation procedure. This seems to be the main reason for the forward rebound of mandible in the majority of the mandibular setback surgery subjects. Infrequently, the opposite situation may occur. In some of the mandibular setback surgery subjects, unusual postsurgical changes involving backward displacement of mandible can occur when the surgeon brings the proximal segments forward during the fixation procedure.

The correlation between the amount of surgical correction and the amount of relapse needs more thorough study

through larger sample size and multiple parameter of relapse.

Sinclair^[6] reported that the mean severity of the relapse of mandibular setback surgery is about 20%–30% of the total surgical change and is in the anterior direction. The percent of change varies greatly in different individuals and in some cases it is in the posterior direction. **Bailey**^[14] said, “It is quite misleading to describe, in terms of the percentage of treatment, change that was retained at some follow-up time, as was done in many early articles on stability after orthognathic surgery. Reporting such percentages implies that the more we change, the more relapse would occur. Indentofacial patients, that almost never is the case.” She also pointed out that it is hard to predict which patients will experience severe relapse after surgery.

It is possible that postsurgical restriction of the space available for the tongue may have been a factor in mandibular relapse and that the alternative of maxillary advancement surgery would have provided more space for the tongue. **Kawakami**^[26] and associates examined the effect of partial glossectomy on skeletal stability and postoperative change after mandibular setback surgery. They reported adaptations in hyoid bone position and tongue mass to the altered environment after setback surgery, but found no significant difference between the tongue reduction group and control group in the horizontal and vertical changes of incisor position one year after surgery.

Another possible factor in relapse after mandibular setback surgery is an expression of some remaining mandibular growth potential. **Wolford et al**^[5] reported the efficacy of high condylectomy for management of condylar hyperplasia. In his study, the patients in group I (n = 12; average age at surgery 17.5years) were treated only with orthognathic surgery, including bilateral sagittal split osteotomy (BSSO), while the patients in group II (n =25; average age at surgery 16.7years) had high condylectomy, articular disc repositioning, and orthognathic surgery including BSSO. All patients in group I grew back into skeletal and occlusal Class III relationships and required additional treatment. Only one patient in group II required secondary surgery. Wolford et al^[5] also reported a statistically significant difference between groups in terms of stability at long-term follow-up. The patients in his sample were obviously growing at the time of surgery since patients with mandibular prognathism tend to have more mandibular growth and a longer growth period.

Presurgical orthodontic treatment is usually started after the completion of mandibular growth, defined as the absence of observable growth in the last three cephalograms. The presurgical position of proximal segments relative to adjacent anatomic structures seems to be very critical in each person’s stomatognathic system. Its position may be related to other important physiologic functions such as respiration, chewing, swallowing, and speech.

So, if the presurgical position of proximal segments is changed during a treatment procedure, such as mandibular setback surgery, there is a strong tendency for the structure to return to its original position. Therefore, this is a strong return tendency of the proximal segment of the mandible can be a driving force for change of the distal segments of the mandible during the postsurgical phase of orthodontic treatment.

7. Summary and Conclusion

It can be concluded that:

- Mandibular repositioning for correction of mandibular prognathism results in significant soft and hard tissue changes in the lower face.
- If the position of the proximal segment of the mandible is changed during the fixation procedure during mandibular setback surgery, the proximal segment has a tendency to move back toward its presurgical position in the period following surgery.
- In the present sample, there were few or no changes in the mandibular position during the postsurgical phase of orthodontic treatment when the surgeon had maintained the presurgical positions of proximal segments during mandibular setback surgery.
- Maintaining the presurgical position of the proximal segments during surgery seems to be a major determinant of postsurgical stability.
- However there can be other variables also affecting the post operative relapse of Bilateral Sagittal Split Osteotomy of the mandible hence, relapse is a multifactorial cause.

References

- [1] Long-Term Stability of Surgical Mandibular Setback-Heon Jae Choa November 2006. The EH Angle Education and Research Foundation
- [2] Steinhäuser EW: Historical development of orthognathic surgery J Cranio Maxillofac Surg 24:195, 1996
- [3] Prague medical report / vol. 109 (2008) no. 4, p. 286–297
- [4] Laura A. Monson, MD Semin Plast Surg. 2013 Aug; 27 (3): 145–148. doi: 10.1055/s-0033-1357111PMCID: PMC3805998 Bilateral Sagittal Split Osteotomy
- [5] Cho HJ. Patient with severe skeletal Class III malocclusion and severe open bite treated by orthodontics and orthognathic surgery—a case report. Am J Orthod Dentofacial Orthop. 1996;110:155–162.
- [6] Proffit WR, Philips C, Dann C, Turvey TA. Stability after surgical orthodontic correction of skeletal Class III malocclusion. I. Mandibular setback. Int J Adult Orthodon Orthognath Surg. 1991;6:7–18.
- [7] Proffit WR, Philips C, Turvey TA. Stability after surgical orthodontic correction of skeletal Class III malocclusion. III. Combined maxillary and mandibular procedures. Int J Adult Orthodon Orthognath Surg. 1991; 4:211–225.

- [8] Wolford LM, Mehra P, Reiche-Fischel O, Morales CA, Garcia-Morales P. Efficacy of high condylectomy for management of conylar hyperplasia. *Am J Orthod Dentofacial Orthop.* 2002;121:136–151.
- [9] Fuselier JC, Freitas RZ, Wolford LM. Stability of mandibular setback procedures with sagittal split osteotomies in nongrowing patients. *J Oral Maxillofac Surg.* 1999;57 (suppl 1):94–95.
- [10] Sinclair PM. The long-term stability of orthognathic surgery. *AAO audiotape, PROD.* 1993; October:5–6.
- [11] Mobarak KA, Krogstad O, Espeland L, Lyberg T. Long-term stability of mandibular setback surgery: a follow-up of 80 bilateral sagittal split osteotomy patients. *Int J Adult Orthodon Orthognath Surg.* 2000;15:83–95.
- [12] Busby BR, Bailey LJ, Proffit WR, Phillips C, White RP. Long-term stability of surgical Class III treatment: a study of 5-year postsurgical results. *Int J Adult Orthodon Orthognath Surg.* 2002;17:159–170.
- [13] Eggensperger N, Raditsch T, Taghizadeh F, Iizuka T. Mandibular setback by sagittal ramus osteotomy: a 12-year follow-up. *Acta Odontol Scan.* 2005;63:183–188.
- [14] Bailey LJ, Cevidanes LH, Proffit WR. Stability and predictability of orthognathic surgery. *Am J Orthod Dentofacial Orthop.* 2004;126 (3):273–277.
- [15] Komori E, Aigase K, Sugisaki M, Tanabe H. Cause of early skeletal relapse after mandibular setback. *Am J Orthod Dentofacial Orthop.* 1989;95:29–36.
- [16] Hullihen SP. Case of elongation of the under jaw and distortion of the face and neck, caused by a burn, successfully treated. *Am J Dent Sci* 1849; 9:57
- [17] Björk A, Skieller V. Normal and abnormal growth of the mandible. A synthesis of longitudinal cephalometric implant studies over a period of 25 years. *Eur J Orthod.* 1983;5:41–43.
- [18] Masaki Fujioka, M.D. Tohru Fujii, M.D. Akiyoshi Hirano Comparative Study of Mandibular Stability After Sagittal Split Osteotomies: Biocortical Versus Monocortical Osteosynthesis, M.D. January 2000.
- [19] Christof Urs Joss and Urs Walter Thüer Departments of Orthodontics, University of Geneva and University of Bern, Switzerland doi:10.1093/ejo/cjn008
- [20] European Journal of Orthodontics 30 (2008) 352–358; Prague Medical Report/Vol.109 (2008)No.4, p. 286–297. Factors Affecting the Stability of Bilateral Sagittal Split Osteotomy of a Mandible Hoffmannová J., Foltán R., Vlk., Pavlíková G. Charles University Prague
- [21] Chung IH¹, Yoo CK, Lee EK, Ihm JA, Park CJ, Lim JS, Hwang KG-J *J Oral Maxillofac Surg.* 2008 Mar;66 (3): 44652. doi:10.1016/j.joms.2007.06.643. Postoperative stability after sagittal split ramus osteotomies for a mandibular setback with monocortical plate fixation or bicortical screw fixation.
- [22] Proffit WR¹, Phillips C, Turvey TA-J *J Oral Maxillofac Surg.* 2012 Jul;70 (7):e408-14. Doi: 10.1016/j.joms.2012.01.006. Epub 2012 Feb 24. Stability after mandibular setback: mandible-only versus 2-jaw surgery.
- [23] S Vinay Darshan¹, Yusuf Ahammed Ronad², M S V Kishore³, K Sadashiva Shetty⁴, M Rajesh⁵, S D Suman⁶ Long Term Stability and Relapse Following Mandibular Advancement and Mandibular Setback Surgeries: A Cephalometric Study
- [24] Nasser Nooh, *The Saudi Dental Journal* (2009) 21, 123–126 Department of Oral and Maxillofacial Surgery, College of Dentistry, King Saud University, Stability of the mandible after bilateral sagittal split osteotomy: Comparison between positioning screws and plate
- [25] Rivera SM, Hatch JP, Dolce C, Bays RA, Van Sickels JE, Rugh JD. Patients' own reasons and patient-perceived recommendations for orthognathic surgery. *Am J Orthod Dentofacial Orthop.* 2000;118:134–141.
- [26] Kawakami M, Yamamoto K, Noshi T, Miyawaki S, Kirita T. Effect of surgical reduction of the tongue on dentofacial structure following mandibular setback. *J Oral Maxillofac Surg.* 2004;62:1188–1192