

A Cadaveric Study to Correlate the Antero-Posterior Length of Insula and Sylvian Fissure Length on Lateral Surface along with its Clinical Significance

Dr. Jaya Kadam¹, Dr. Deepak Sharma²

¹Post Graduate Student, Department of Anatomy, Gandhi Medical College, Bhopal, India

²Assistant Professor, Department of Anatomy, Gandhi Medical College, Bhopal, India

Abstract: *The cerebral hemisphere is divided by a longitudinal fissure into 2 parts right and left, each containing 6 lobes Frontal, Parietal, Temporal, Occipital, Insular cortex and Limbic system. The Frontal, Parietal, Temporal, Occipitallobes clearly visible on the brain's surface, the insula is hidden in the sylvian cistern. The limbic lobe is a curved area on the medial side of each cerebral hemisphere. 29 human cadaveric brains, comprised of 58 insulae and 58 sylvian fissures (lateral sulcus) are studied in the Department of Anatomy, Gandhi Medical college, Bhopal(M.P.). The purpose of our study is to understand regional anatomy of Insula and sylvian fissure. There is positive correlation between the anteroposterior length of insular cortex and sylvian fissure length on lateral surface. Insula has high clinical and surgical importance due to asymmetry of insular cortex, its variations and correlation with sylvian fissure. The study is expected to be useful for neuroanatomists, neurosurgeons, neurophysicians, neuroradiologists & psychiatrists.*

Keywords: sylvian fissure, insular cortex

1. Introduction

The Island of Reil is named after the great anatomist Dr. Johann Christian Reil (1809). It forms the base of the Sylvian cistern¹. The sylvian cistern is divided into deep (base) and superficial (lateral sulcus or sylvian fissure) part. The Anteroposterior length of insula is on the dorsal surface of insular cortex. It is the linear distance from the most anterosuperior point to most posteriosuperior point of insular cortex on peripheral sulci. The length of sylvian fissure on lateral surface is the distance between anterior most point to posterior sylvian point on sylvian fissure. The lengths are of surgical importance and the insular lobe is also connected with other lobes of brain.

Brodmann, best known today for his classical cortical architectonic maps, defined five lobes of the brain and fifth the insular lobe was described by Vogt². The human insular lobe includes Brodmann areas 13 to 16³. The Sylvian fissure is formed as a result of the 'telencephalisation' leads to frontal, parietal and temporal opercularisation. The other result structures situated on the surface of the cerebral hemisphere during fetal stages become buried and its growth may not keep pace with this telencephalisation process. It has a gradual increase in the complexity of its anatomical and physiological hominid evolution⁴.

The human insula is considerably greater in size when compared to the macaque brain and it has also been observed that the insula is longer in its antero-posterior length in humans, baboons and macaques than in the chimpanzee^{4,5,6}. The term apex is situated most laterally and it is little elevated than above the plane of the insula. The term pole of anterior lobule is the most anteroinferior point on the insula. The new term pole of the posterior lobule is introduced to indicate the anterior most extent of the posterior

lobule of the insula where the two long gyri converge to form the posterior wall of the limen insulae⁷.

The sylvian fissure is anatomical and surgical landmark on the lateral surface and on the inferior surface of brain. It is a fissure that carries the middle cerebral artery and its branches and provides a surgical gateway. Various previous researches explained about asymmetry of brain, temporal lobe and sylvian fissure^{8,9,10}. The aim is to study the correlation and clinical significance of Insular cortex and sylvian fissure. According to **Craig** et al (2009) the insula is unique and it is situated at the interface of the cognitive, homeostatic, and affective systems of the human brain. The stimulus-driven processing and brain regions involved in monitoring the internal environment of mind and body are directly related with insula¹¹.

According to **Fengweng** et al. (2015), Island of Reil, The recent advanced researches concluded that Insula is not an isolated Island like cortical area as it has broad anatomic and functional connections with other important brain structures. Specially the internal capsule and basal ganglia are there in relation to insula. That's why need to study insula first¹². According to **T Yamada and L J Chang** et al (2016), Subdivisions of Insula (Functional parcellation Analysis) are based on analysis of the task related functional magnetic resonance imaging data with 3 functionally distinct subregions. These include a ventro anterior insular region associated with chemosensory and socio-emotional processing. The dorsoanterior insular region associated with higher cognitive processing and posterior insular region associated with pain and sensorimotor processing. That's why¹³.

2. Materials and Method

Morphometry of sylvian fissure (lateral surface) and antero-posterior length of insula

- a) **Study design** - cross sectional observational study.
- b) **Study area** - Department of Anatomy, Gandhi Medical College, Bhopal, (M.P.)
- c) **Material** - digital vernier calliper, thread, artery forcep, scale, protractor, scalpel, forceps, number tags, acrylic colours.
- d) **Sample size** - 29 formalin fixed human cadaveric brains, comprised of 58 insulae and 58 sylvian fissures (lateral sulcus).
- e) **Selection criteria**

Inclusion criteria

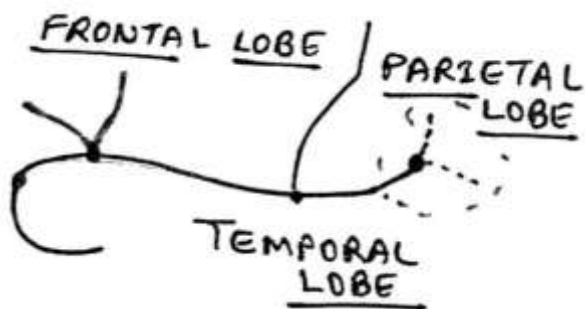
Undamaged specimens of both right and left sided cerebral hemispheres cadaveric brains with intact Insula and sylvian fissure.

Exclusion criteria:

Damaged specimens of both right and left sided cerebral hemispheres cadaveric brains with intact Insula and sylvian fissure.

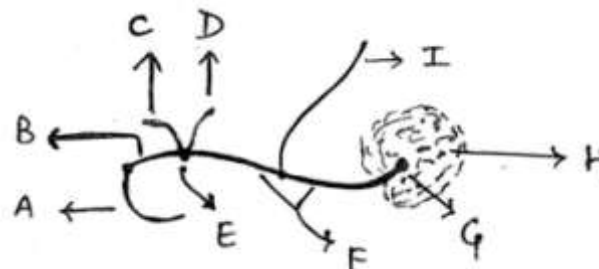

Data collection: Brains are studied in the Department of Anatomy, Gandhi Medical college, Bhopal. M.P. The formalin fixed brain was dissected and studied according to Cunningham's practical manual. Then study of sylvian fissure, morphological and morphometric analysis of insula was done. Statistical analysis of results and comparisons among right and left hemispheres was done.

Method: The present study included formalin fixed 29 brains (58 right and left cerebral hemispheres) with intact arachnoid were used to measure lengths of all the sulci and gyri of insular cortex and all segments of sylvian fissure.



Sylvian Fissure between Frontal lobe, parietal lobe, and Temporal lobe.

P Ob=Pars orbitalis, P T=Pars Triangularis, P Op= Pars Opercularis



All Segments of Sylvian Fissure

- Segment A= stem of sylvian fissure (on inferior surface)
- Segment B= stem of sylvian fissure (on lateral surface)
- Segments A + B= stem of sylvian fissure (total length)
- Segment between Point E to Point G= posterior ramus of sylvian fissure
- Segment B + Segment between Point E to Point G= sylvian fissure (lateral surface)
- {Segments A + B} + {Segment between Point E to Point G} = sylvian fissure (total length)
- Anterior rami of sylvian fissure {C=anterior horizontal limb and D=anterior ascending limb}
- E=Anterior sylvian point
- G=Posterior sylvian point
- H=Supra Marginal Gyrus

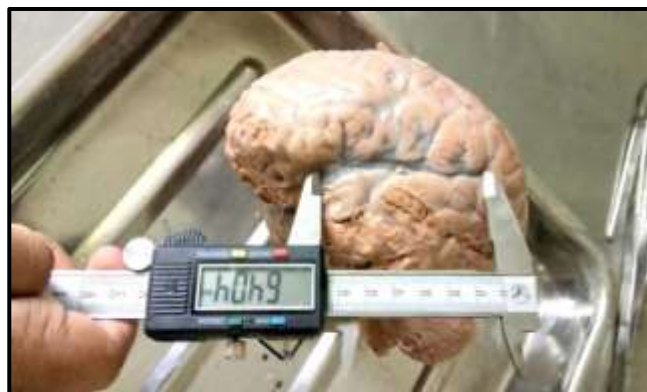

Figure 1: Sylvian Fissure (Lateral Surface)



Figure 2: Antero-posterior length of Insular cortex (APL-IC)

(Measurements were taken by Digital Vernier Caliper)

The Antero posterior length of insula is on the dorsal surface of insular cortex. It is the linear distance from the most antero superior point to most posterior superior point of insular cortex on peripheral sulci.

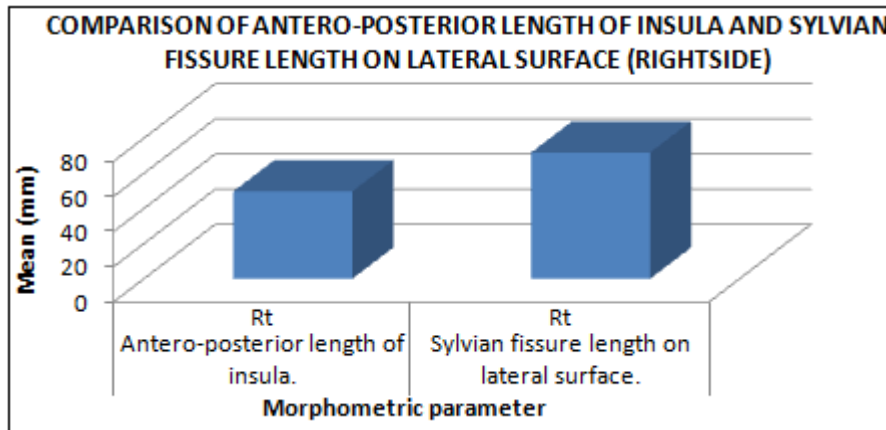
Deviation, Unpaired t test, p value, r value, Degree of freedom, Confidence interval, Standard error of deviation were calculated and recorded.

Statistical analysis: Morphological and morphometric parameters were recorded, then Range, Mean, Standard

3. Results and Observations

Table 1: Comparison of antero-posterior length of insula and sylvian fissure length Onlateral surface(rightside)

S.No.	Morphometricparameter	Side	Minimum (mm)	Maximum (mm)	Mean (mm)	SD
1	Antero-posterior lengthofinsula.	Rt.	44.02	61.16	49.68	4.11
2	Sylvianfissurelengthonlateralsurface.	Rt.	59.15	86.90	71.79	6.46



Graph 1: Comparison of antero-posterior length of insula and sylvian fissure length on lateral surface (rightside)

Table 2: Comparison of antero-posterior length of insula and sylvian fissure length on lateral surface (rightside) (statistics)

Confidence interval	p (value)	t (value)	SED
-24.9582to -19.2618	0.0001	15.5507	1.422

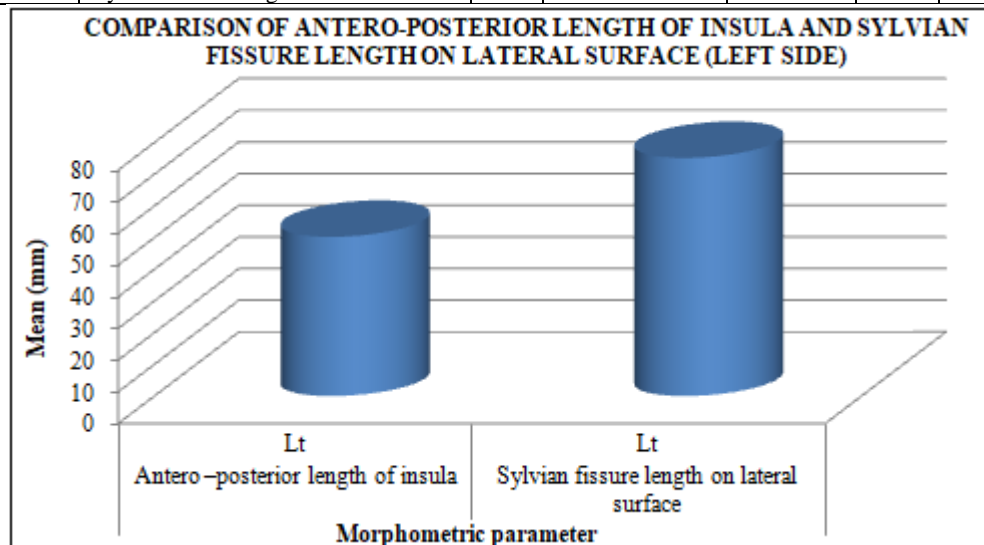
cerebral hemispheres is in the range of 44.02 to 61.16 mm and 59.15 to 86.90 mm, respectively.

As the p value is <0.05 it explains the values are statistically significant. It indicates there is positive correlation between the lengths of antero posterior length of insular cortex and sylvian fissure on lateral surface.

The lengths of antero posterior length of insular cortex and sylvian fissure length on lateral surface on all 29 right side

Table 3: Comparison of antero-posterior length of insula and sylvian fissure length on lateral surface (leftside)

S.No.	Morphometric parameter	Side	Minimum (mm)	Maximum (mm)	Mean (mm)	SD
1	Antero -posterior length ofinsula	Lt	44.03	57.19	50.24	3.39
2	Sylvianfissure lengthon lateralsurface	Lt	61.80	84.72	75.15	5.84



Graph 2: Comparison of antero-posterior length of insula and sylvian fissure length on lateral surface (leftside)

Table 4: Comparison of antero-posterior length of insula and sylvian fissure length on lateral surface (left side) (statistics)

Confidence interval	p (value)	t (value)	SED
-27.4219to -22.3981	0.0001	19.8656	1.254

The antero posterior length of insular cortex and sylvian fissure length on left side are (44.03 to 57.19) mm and (61.80 to 84.72) mm, respectively.

As the p value is <0.05 it explains the values are statistically significant. It indicates there is positive correlation between the lengths of antero posterior length of insular cortex and sylvian fissure on lateral surface.

4. Discussion

The lengths of anteroposterior length of insular cortex and sylvian fissure length on lateral surface on all 29 right side cerebral hemispheres is in the range of (44.02 to 61.16) mm and (59.15 to 86.90) mm, respectively. The antero posterior length of insular cortex and sylvian fissure length on lateral surface on all 29 left side cerebral hemispheres the range is (44.03 to 57.19) mm and (61.80 to 84.72) mm, respectively. As the p value is < 0.05 it explains the values are statistically significant. It indicates if the length of sylvian fissure on lateral surface is more than the anteroposterior length of insular cortex is also more. If the length of sylvian fissure on lateral surface is less than the antero posterior length of insular cortex is also less.

All these observations are very important anatomically as well as clinically, as insular functions are related with psychogenic behavior of an individual. According to **Vinod Menon** et al(2010), the insula is a brain structure implicated in cognitive including interoceptive awareness. While considered a limbic region, recent evidence from network analysis suggests a critical role for the insula, particularly the anterior division, in high-level cognitive control and attentional processes. Some Psychological disorders diagnosis are related with short lengths of sylvian fissure and some diseases are related with short length of insula. If the length of sylvian fissure is shorter then it clearly represents short anterior posterior length of insula¹⁴.

5. Conclusions

In the present study morphological and morphometrical parameters were there to understand the normal gross anatomy with variations and asymmetry of insular cortex, sylvian fissure. As the p value is <0.05 it explains the values are statistically significant. It indicates there is positive correlation between the antero posterior length of insular cortex and sylvian fissure length on lateral surface.

References

[1] Reil 1809. Cited by: Ture U, Yasargil DCH, AI-Mefty O, Yasargil MG. Topographic anatomy of the insular region. J Neurosurgery 1999;90:720-733.
 [2] Vogt (1903) and BA(2009) Cingulate neurobiology and diseases. Oxford university press.

[3] Area 13 of Brodmann(guenon), University of Washington. Retrieved 3 June 2010.
 [4] Ture U, Yasargil DCH, AI-Mefty O, Yasargil MG. Topographic anatomy of the insular region. J Neurosurg 1999;90:720-733.
 [5] Mufson EJ, Mesulam MM (1982) Insula of old world monkey .II; Afferent cortical input and comments on the claustrum. J Comp Neurol 212 (1);23-37.
 [6] Augustine JR. The insular lobe in primates including humans. Neurol Res 1985;7:2-19.
 [7] Thomas naidich, Kang E, (2004) The insula; anatomic study and MR imaging display at 1.5 T. Am J Neuroradiol 25(2)222-232.
 [8] Oppenheimer SM, Kedem G, Martin WM. Left-insular cortex lesions perturb cardiac autonomic tone in humans. Clin Auton Res 1996;6:131-140
 [9] Boni, R.C.; Prodocimi, F.C.; Bonsi, A.B.; Almeida, T.M. & Ribeiro, LAM. Asymmetries of the left and right temporal lobes. Int.J. Morphol. 2007;25(1):117-120.
 [10] Toga AW, Thompson PM, Mapping brain asymmetry, Nature Reviews Neuroscience. 2003;4:37-48. [PubMed]
 [11] Craig AD (2009) How do you feel – now ? Interoception ;the anterior insula and human awareness. Net Rev Neurosci 10 (1);59-70.
 [12] Tao Sun ,Feng Wang, Jianqi Cui .Insular cortex and Insular Epilepsy .Journal of Neurology and neuroscience. ISSN 2171-6625, 2015 Vol 6 No.2.9
 [13] Takashi Yamada, Takashi Ithahashi, and Ryo-ichiro Hashimoto. Altered functional organization within the insular cortex in adult males with high-functioning autism spectrum disorder; evidence from connectivity based parcellation. Molecular Autism .2016;7:41. Published online 2016 Oct 5.
 [14] Vinod Menon and Lucina Q Uddin Saliency , Switching ; Attention and control ; a network model of insula function Brain Struct Funct .2010 jun ;214 (5-6)655-667.