

Acute Appendicitis: Correlation between Ultrasonographic and Surgical Findings

Dr Akanksh Chokkapu¹, Dr M Sai Swetha², DrZaibee Ahmed³

Abstract: The main aim of our study is to estimate sensitivity and specificity of Ultrasonography in identifying acute appendicitis in patients referred with symptoms of right iliac fossa pain and its role in the therapeutic management. **Materials and methods:** This study was carried out in the department of Radiodiagnosis, Maharajah's Institute of Medical Sciences, Vizianagaram on Philips affinity 70 Ultrasound machine using – MHz transducer on a hundred patients who presented to surgical out patient department, with symptoms of right iliac fossa pain. They underwent ultrasonography and appendectomy followed by histopathological examination of the specimen. Obese persons (due to difficulty in imaging) and patients requiring emergent surgery were excluded from our study. Ultrasound was done in supine position and in left lateral oblique position, using graded compression technique. **Results:** Out of the hundred patients selected in our study, 64 were male patients, of which 49 were diagnosed to have acute appendicitis and 36 were female, of which 25 were diagnosed to have acute appendicitis on USG. 2 males and 2 females were diagnosed to have appendicular mass on USG. Maximum age was 67 years and minimum age was 3 years. Maximum number of patients were in the age range of 11-20 years. Based on the Alvarado value (more than 5 were taken to have appendicitis), 73% were likely to have appendicitis. On USG, 74 patients were diagnosed to have acute appendicitis of which 73 were confirmed on histopathology. On histopathological examination of all the removed appendix specimens, 76 were diagnosed as acute appendicitis. Sensitivity of USG in diagnosing acute appendicitis in our study was 96.05%. Specificity was 95.83%. The positive predictive value of the study is 98.64% and negative predictive value is 88.46%. The most common position of appendix in our study was retro-caecal (78.20%), followed by pelvic (16.66%). **Conclusion:** Ultrasound has high sensitivity and specificity for diagnosis of appendicitis and should suffice as the modality of choice whenever the appendix is identified. CT should be reserved for complicated cases in which the appendix is not identified or the presence or absence of perforation cannot be determined with ultrasound, and histopathology should remain as gold standard.

Keywords: Acute appendicitis, mimics of appendicitis, histopathological correlation

1. Introduction

Aims and objectives

One of the most frequent causes of surgical emergencies and abdominal pain is acute appendicitis. Patients with appendicitis present with a wide variety of clinical manifestations, which may mimic symptoms of other diseases¹.

If not diagnosed early, it can rapidly develop severe acute abdominal complications such as perforation, abscess formation, sepsis, bowel obstruction and general peritonitis. Prompt diagnosis is essential to minimize morbidity and mortality. Therefore surgeons have been performing appendectomy, in cases where the diagnosis was only probable, thus elevating the rate of removal of normal appendices.

The classic presentation of a patient with appendicitis has a typical sequence of symptoms (poorly localized periumbilical pain followed by nausea and vomiting, with subsequent migration of pain to the right lower quadrant). This classic presentation occurs in only 50%- 60% of patients, and the diagnosis may be missed or delayed when atypical patterns of disease are encountered².

A wait-and-see approach can increase the risk of complications. Ultrasonography, with graded compression, is an accurate, non-invasive, easily available imaging modality for the diagnosis of acute appendicitis and does not use ionizing radiation. The appendix may lie in a retrocecal, subcecal, retroileal, preileal, or pelvic site. This variability in location may greatly influence the clinical presentation in patients with appendicitis³.

The main aim of our study is to estimate sensitivity and specificity of US in identifying acute appendicitis and its role in the therapeutic management.

2. Materials and Methods

This study was carried out in the department of radiodiagnosis, maharajah's institute of medical sciences, vizianagaram on philips affinity 70 USG machine using – MHz transducer.

A 100 patients who presented to surgical out patient department, with symptoms suggestive of acute appendicitis, who underwent ultrasonography and appendectomy followed by histopathological examination of the specimen were selected.

Inclusion criteria

Patients who underwent appendectomy and histopathological examination of the specimen.

Exclusion criteria

- Obese persons due to difficulty in imaging.
- Problems preventing imaging, including those requiring emergent surgery.

Ultrasound was done in supine position, the best position to assess appendix and in left lateral oblique position, using graded compression technique⁴.

On USG, acute appendicitis was diagnosed if at least one of the following abnormalities was revealed:

- 1) The appendix could not be compressed; parietal thickness >3 mm and outer-to-outer diameter >7 mm⁵.
- 2) Loss of normal parietal stratification⁶.

- 3) Hyperechoic periappendiceal fat i.e. periappendicealfat stranding⁷.
- 4) Abscess collection in the appendix⁸.
- 5) Periappendiceal fluid collection⁹

Alvarado number was also calculated by using the data obtained.

3. Results

A hundred patients who presented with symptoms suggestive of acute appendicitis were selected in our study. 64 were male patients, of which 49 were diagnosed to have acute appendicitis on USG and 36 were female of which 25 were diagnosed to have acute appendicitis on USG. 2 males and 2 females were diagnosed to have appendicular mass on USG. Maximum age was 67 years and minimum age was 3 years. Maximum number of patients were in the age range of 11-20 years. Using the formula given in methods, alvarado number was calculated. Highest was 9 and the lowest was 0. patients who had alvarado value of more than 5 were taken to have appendicitis and those who had value less than 5 were taken as without risk. Based on this, 73% were likely to have appendicitis.

Spectrum of Complaints

Complaints	n	%
Right lower quadrant tenderness	85	85
Rebound tenderness	41	41
Fever	22	22
Loss of appetite	53	53
Nausea, vomiting	78	78
Shift in pain	42	42
Leukocytosis	79	79
Left shift	76	76

Spectrum of diseases mimicking acute appendicitis in our study

Disease	Males	Females	Total
ACUTE APPENDICITIS	49	25	74
APPENDICULAR MASS	2	2	4
RT. ACUTE PYELONEPHRITIS	-	1	1
RT. URETERIC CALCULUS	3	-	3
PID	-	2	2
TWISTED OVARIAN CYST	-	2	2
ILEO-CAECAL TB	1	2	3
CA CAECUM	3	-	3
NAD	6	2	8
TOTAL	64	36	100

Sex incidence of acute appendicitis and appendicular mass in our study:

Disease	Males	Females	Total
Acute Appendicitis	49	25	74
Appendicular Mass	2	2	4

Spectrum of appendicitis and diseases mimicking acute appendicitis in our study

Sonographic Diagnosis	Patients With Disease	Patients Without Disease
Positive	73	1
Negative	23	3

Total number of cases : 100
 Sonographically positive for acute appendicitis: 74
 Sonographically negative : 26
 False positive : 1
 False negative : 3
 Sensitivity : 96.05%
 Specificity : 95.83%
 Positive predictive value : 98.64%
 Negative predictive value : 88.46%

On USG, 74 patients were diagnosed as having acute appendicitis of which 73 were confirmed on histopathology. On histopathological examination of all the removed appendix specimens, 76 were diagnosed as acute appendicitis.

In our study, 3 were false negative and 1 case was false positive. Sensitivity of USG in diagnosing acute appendicitis in our study was 96.05%. Specificity was 95.83%. The positive predictive value of the study is 98.64% and negative predictive value is 88.46%. The most common position of appendix in our study was retro-caecal(78.20%), followed by pelvic(16.66%).

4. Discussion

A hundred patients who presented with complaints suggestive of appendicitis were included in our study. These underwent USG examination and appendicectomy followed by histopathological examination of the removed appendiceal specimen. Alvarado score was calculated based on the available data. The maximum score obtained was 9 and the minimum was 0. 73% were suspected to likely have appendicitis based on this scoring.

USG was done using graded compression technique. In our study, 74 cases were diagnosed as acute appendicitis on USG of which 73 were confirmed on histopathology. 3 cases were false negative and 1 case was false positive on USG.

Sensitivity of USG in diagnosing acute appendicitis in our study was 96.05% which is comparable to Harshada M. Joshi et al (1996) and RB Jeffrey et al (1987). Specificity was 95.83% which was comparable to RB Jeffrey et al (1987) and Monzer et al (1987).

The positive predictive value of the study is 98.64% and negative predictive value is 88.46%. The most common position of appendix in our study was retro-caecal(78.20%) the percentage of which is greater than that of the study done by wakeley¹⁰, followed by pelvic(16.66%), which was lesser when compared to the study done by wakeley.

Comparative results of different studies:

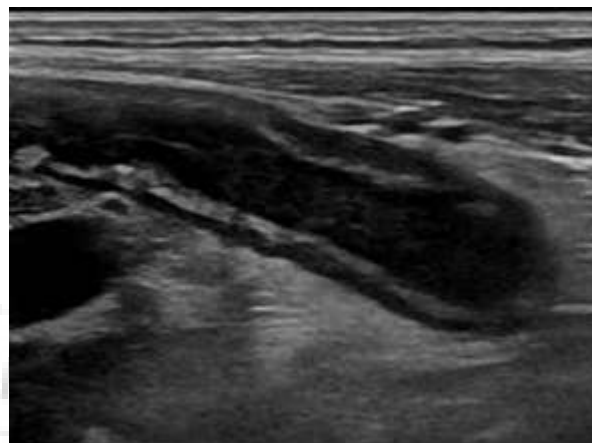
References	Transducer Frequency (MHz)	Accuracy (%)	Sensitivity (%)	Specificity (%)	PPV (%)	NPV (%)
Puylaert et al (1986)	5/7.5	-	75	100	-	-
Kastrup et al (1986)	5	87	83	94	96	76
Monzer et al (1987)	5	90	80	95	91	89
RB Jeffrey et al (1987)	5	93.9	89.9	96.2	93	94.3
Wolf et al (1989)	5	95.7	88.5	98	94.5	96.3
Harshada M. Joshi et al (1996)	6.5/10	95	96	93	98	88
Present study			96.05	95.83	98.64	88.46

Position of appendix in a study by Wakeley in 10,000 patients:

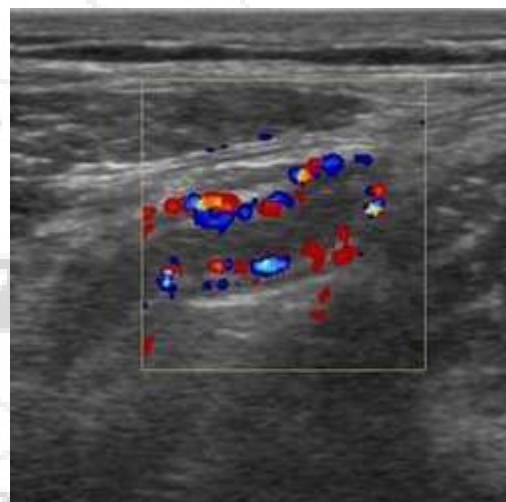
Position of Appendix	Percentage%
Retro-caecal & retro colic	65.28
pelvic	31.01
Subcaecal	2.26
Pre ileal	1
Post ileal	0.4

Percentage of position of appendix in our study:

Position of Appendix	No. of Cases	Percentage%
Retro-caecal	61	78.20
pelvic	13	16.66
Subcaecal	1	1.28
Pre ileal	1	1.28
Post ileal	1	1.28
subhepatic	1	1.28
Total	78	100



Acute appendicitis longitudinal view



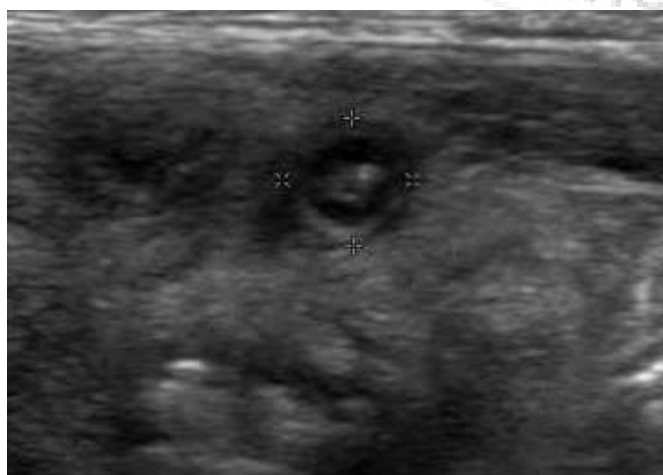Acute appendicitis color doppler

5. Conclusion

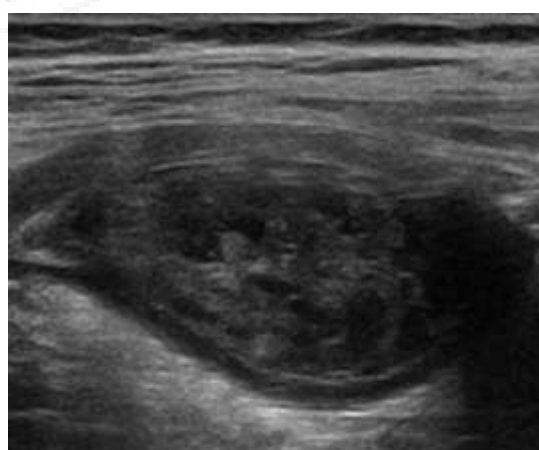
Ultrasound has high sensitivity and specificity for diagnosis of appendicitis and should suffice as the modality of choice whenever the appendix is identified.

The decision to perform appendectomy or to treat a patient conservatively should be made in association with clinical findings.

CT should be reserved for complicated cases in which the appendix is not identified or the presence or absence of perforation cannot be determined with ultrasound, and histopathology should remain as gold standard.



Acute appendicitis axial view



Appendicular mass

References

- [1] Rumack C. Diagnostic ultrasound. 5th ed. St. Louis: Elsevier Mosby; 2018.
- [2] Appendicitis: Practice Essentials, Background, Anatomy [Internet]. Emedicine.medscape.com. 2018 [cited 14 May 2018]. Available from: <https://emedicine.medscape.com/article/773895-overview?pa=LvvnvTPYjoFoKfdyp%2BjxGBelYtA4EYdILGD0x8gs9EJC1mD2Ou0yFUZA8g8rK2ilZpBVtw95Fr5za5%2FiYH3WttF%2FDMAAtBBAsM6eN9kpLn%2Fas%3D>
- [3] Baert A. Encyclopedia of diagnostic imaging. Berlin: Springer; 2008.
- [4] Lee J, Jeong Y, Hwang J, Ham S, Yang S. Graded Compression Sonography with Adjuvant Use of a Posterior Manual Compression Technique in the Sonographic Diagnosis of Acute Appendicitis. *American Journal of Roentgenology*. 2002;178(4):863-868.
- [5] E Yacoe, M & B Jeffrey, R. (1994). Sonography of appendicitis and diverticulitis. *Radiologic clinics of North America*. 32. 899-912.
- [6] Summa M, Perrone F, Priora F, Testa S, Quarati R, Spinoglio G. Integrated clinical-ultrasonographic diagnosis in acute appendicitis. *Journal of Ultrasound*. 2007;10(4):175-178.
- [7] Noguchi T, Yoshimitsu K, Yoshida M. Periappendiceal Hyperechoic Structure on Sonography. *Journal of Ultrasound in Medicine*. 2005;24(3):323-327.
- [8] Her JW, Hwang JS, Ahn SH, Park SK, Kim H. Epigastric Appendiceal Abscess with Spontaneous Drainage into the Stomach. *The Korean Journal of Internal Medicine*. 1999;14(2):82-85. doi:10.3904/kjim.1999.14.2.82.
- [9] Puylaert J. Ultrasonography of the acute abdomen. *Radiologic Clinics of North America*. 2003;41(6):1227-1242.
- [10] Wakeley CPG. The Position of the Vermiform Appendix as Ascertained by an Analysis of 10,000 Cases. *Journal of Anatomy*. 1933;67(Pt 2):277-283.