

# Difference in Caspase-3 Expression among Benign, Borderline and Malignant Epithelial Type of Ovarian Tumor

I Made Brammartha Kusuma<sup>1</sup>, Ketut Suwiyoga<sup>2</sup>, I Nyoman Gede Budiana<sup>3</sup>, I Wayan Juli Sumadi<sup>4</sup>

<sup>1,2,3</sup> Department of Obstetrics and Gynaecology, Oncogynaecology Division

<sup>4</sup>Department of Patology Anatomi, Faculty of Medicine Udayana University / Sanglah Hospital Denpasar- Bali

**Abstract:** *Background:* Ovarian tumor is a worldwide problem and mortality due to ovaria tumor is the highest among gynaecologic malignant tumors. Epithelial type are the most common ovarian tumor. The distribution of benign ovarian epithelial tumors, borderline and malignant causes a variety of tumor characteristics that lead to difficulties in its management. One of the genes that play a role in ovarian tumors is caspase-3, which is a protease execution DNA fragmentation that malfunctioning, causing no apoptosis. The malfunction results in slowed ovarian cell death process and uncontrolled proliferation of ovarian cells that cause carcinogenesis. *Research purposes:* To know the differences of caspase-3 expression in benign, borderline and epithelial type malignant ovarian tumor. *Research methods:* A cross-sectional study was conducted from 40 paraffin block samples of benign, borderline and malignant type of epithelial ovarian tumor. Caspase-3 expression was measured using immunohistochemical staining. Statistical analysis was performed using Chi-Square test. *Results:* We found a significant difference in caspase-3 expression among benign, borderline and malignant epithelial ovarian tumor ( $p=0.008$ ), a significant difference between benign and malignant epithelial ovarian tumor ( $p = 0,004$ ). We did not find a significant differences of caspase-3 expression between benign and borderline ( $p = 0,304$ ) as well as between malignant and borderline epithelial type ovarian tumors ( $p = 0,215$ ). *Conclusion:* Caspase-3 expression was higher in benign epithelial type ovarian tumor and lower in borderline and malignant epithelial type of ovarian tumor.

**Keywords:** caspase-3, immunohistochemistry, ovarian, epithelial type tumors

## 1. Background

Ovarian tumor grows rapidly and the mortality is still high. Up to 90% cases is diagnosed at an advanced stage that is difficult to cured by surgery or chemotherapy. The most common type of ovarian tumors is epithelial type (90% of cases).<sup>1</sup> Epithelial ovarian tumors can be classified as benign, borderline and malignant. About 80% of benign tumors occur in young women ages 20 to 45 years. Borderline and malignant tumors are more common in older women (age 45 to 65 years).<sup>2</sup> Although the incidence is lower when compared to cervical and uterine tumors but malignant ovarian tumors have the highest mortality. According to Busmar (2010), in the United States there were 25.400 cases of ovarian malignant tumors with 14.300 deaths, which accounted for 56,3% of all female deaths due to malignant ovarian tumors in 2003. In 2008, the incidence of ovarian tumors in the world reached 9,4 % with a mortality rate 5,1%.<sup>3</sup> The number of ovarian malignant tumors cases in Indonesia is 829, the third after cervical 2.532 cases and 2.254 cases of breast.<sup>4</sup> Karyana (2005) found the incidence of malignant ovarian tumors at Sanglah General Hospital accounted for 35% of all gynecological cancers, with a five-year survival rate only 15%.<sup>5</sup>

Invasion and metastasis of ovarian cancer are caused by an abnormal apoptosis regulation. Apoptosis is a programmed cell death with specific form and cellular changes. This programed death has two major pathways. i.e., intrinsic and extrinsic pathways. Both of these pathways result in cytochrome-c release and caspase activation.<sup>6</sup> Caspase is a class of cysteinyl aspartate-specific proteases that is not active (zymogens) in healthy cells. Caspase-3 is the most

common caspase that catalyzes the cleavage of specific important cellular proteins. Caspase-3 activation is associated with DNA fragmentation and morphological changes that lead to cell death (apoptosis). Caspase-3 works more efficiently for cell division than other caspases. Higher activation of caspase-3 leads to wider spectrum of division that results in apoptosis.<sup>7,8</sup>

Various immunohistochemical studies were conducted to determine the relationship between caspase-3 with the occurrence of cancer in the last two decades. According to Li et al (2012), caspase-3 activation was detected in normal tissue but could not be identified in peritumoral or squamous cell tissues in oral cancer.<sup>9</sup> Lower expression of caspase-3 in tumor tissue compared with normal tissue indicate that the apoptotic process mediated by caspase-3 did not work and eventually the cells developed into cancer. However, different observation is found in breast cancer. Donovan et al (2003) reported that caspase-3 levels in breast cancer patients were significantly higher than in fibroadenoma as well as normal breast tissue.<sup>10</sup> Caspase-3 expression increase the proliferation rate in malignant breast tissue. The role of caspase-3 in cancer development is still controversial. To date, no research has been done on caspase-3 expression at Sanglah Hospital. Taken into account the high incidence of ovarian tumors, we decided to examine the differences in caspase-3 expression among benign, borderline and malignant epithelial type of ovarian tumors.

## 2. Method

The study was conducted from July 2015 to December 2016 in Obstetric and Gynecology Outpatient Clinic Sanglah

Hospital, Anatomy Pathology Laboratory Faculty of Medicine, Udayana University / Sanglah Hospital and Medical Record Installation Sanglah Hospital, Denpasar. This is a cross sectional study using 40 samples of paraffin blocks.

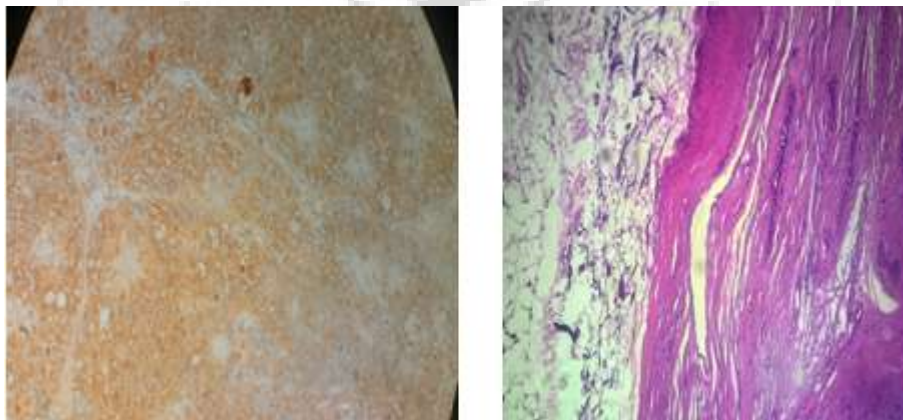
Paraffin blocks of epithelial ovarian tumor was obtained consecutively from patients who had given a written consent and underwent laparotomy for tumor removal from July 2015 to December 2016 at Sanglah Hospital. Paraffin blocks was prepared in Anatomy Pathology Laboratory, Faculty of Medicine, Udayana University / Sanglah Hospital which is examined to define a definite diagnosis of benign, borderline and malignant epithelial ovarian tumors.

The inclusion criteria for this study were 1) paraffin blocks were examined histopathologically and concluded as benign epithelial type ovarian tumor, borderline and malignant; 2) Complete medical records include identity, age, parity, histopathologic diagnosis. While for the exclusion criteria of this study 1) Patients had undergone chemotherapy before surgery; 2) Damaged paraffin blocks. Caspase-3 expression was examined in all three groups using immunohistochemical techniques with *Novocastra TM Lyophilized Mouse Monoclonal Antibody CPP32* (Caspase-3) stain from Leica Biosystem Newcastle Ltd–United Kingdom. The expression is measured semiquantitatively by counting the percentage of malignant cells recorded positive among the 200 malignant epithelium,

observed by Olympus light microscope (400x magnification). Staining is considered positive when the cell nucleus and / or cytoplasm are brown. Scores were obtained based on the percentage of cell nuclei and / or cytoplasm in position (Table 1), with a score range of 0 when no cell nucleus and / or cytoplasm were unbounded, score +1 when the cell nucleus and / or cytoplasm were in less than 1%, the score +2 when a cell nucleus and / or cytoplasm that is covered by 1-10% and score +3 when the cell nucleus and / or cytoplasm are over 10%. Caspase-3 expression is categorized to be negative for a score of 0 and +1, while positive caspase-3 expression for the score of +2 and +3 (Figure 1).<sup>11</sup>

**Table 1:** The interpretation of caspase-3 staining

Patterns of wear	Score	Category
No nucleus cell and / or cytoplasm colored	0	Negative
The nucleus cell and / or cytoplasm smeared less than 1%	+1	Negative
The nucleus cell and / or cytoplasm smeared 1-10%	+2	Positive
The nucleus cell and / or cytoplasm smeared more than 10%	+3	Positive



**Figure 1:** Positive (left side) and negative (right side) expression of caspase-3

The data was analyzed using SPSS 6.0 for Windows. One sample Kolmogorov-Smirnov test for performed to test data normality and Levene's test used for data homogeneity. Mean comparison of each variable was analyzed using One Way Anova test. Chi-Square test used to evaluate the difference in caspase-3 expression among all three groups of tumors.

### 3. Results

From 40 blocks of paraffin obtained, the proportion of benign epithelial ovarian tumor were 7 (17,5%), borderline epithelial ovarian tumors 10 (25%) and malignant epithelial ovarian tumors were 23 (57,5%). There were no significant difference in mean values of age and parity across all three groups (Table 2).

**Table 2:** Distribution of Age and Parity among All Three Groups

Variables	Malignant Tumor (n=23)		Borderline Tumor (n=10)		Benign Tumor (n=7)		P
	Average	SD	Average	SD	Average	SD	
Age (yr)	44,57	11,04	48,40	11,94	34,29	19,16	0,090
Parity	1,74	1,36	2,00	1,70	1,14	1,77	0,516

Chi square test was performed to determine the differences in caspase-3 expression among all three groups. There was a significant difference in caspase-3 expression between benign, borderline and malignant epithelial type ovarian tumors (p = 0,008) (Table 3).

**Table 3:** Caspase-3 expression between benign, borderline and malignant epithelial type ovarian tumor

Epithelial Ovarian Tumor	Caspase-3		$\chi^2$	P
	Negative	Positive		
Malignant	18	5	9,71	0,008
Borderline	5	5		
Benign	1	6		

There were no significant difference in caspase-3 expression between benign and borderline epithelial type ovarian tumors ( $p > 0,05$ ) (Table 4).

**Table 4:** Caspase-3 expression between benign and borderline epithelial type ovarian tumor

Epithelial Ovarian Tumor	Caspase-3		$\chi^2$	P
	Negative	Positive		
Borderline	5	5	2,30	0,304
Benign	1	6		

There was a significant difference of caspase-3 expression between benign and malignant epithelial ovarian tumors ( $p = 0,004$ ) (Table 5).

**Table 5:** Caspase-3 expression between benign and malignant epithelial type ovarian tumor

Epithelial Ovarian Tumor	Caspase-3		$\chi^2$	P
	Negative	Positive		
Malignant	18	5	9,46	0,004
Benign	1	6		

There was no significant difference in caspase-3 expression between malignant and borderline epithelial type ovarian tumors ( $p > 0,05$ ) (Table 6).

**Table 6:** Caspase-3 expression between malignant and borderline epithelial type ovarian tumor

Epithelial Ovarian Tumor	Caspase-3		$\chi^2$	P
	Negative	Positive		
Malignant	18	5	2,64	0,215
Borderline	5	5		

#### 4. Discussion

Ovarian tumors can be classified as benign, borderline and malignant type. About 80% of benign tumors occur in young women between the ages of 20 and 45 years. Borderline and malignant tumors are more frequent among older age between 45 and 65 years. In this study, the mean age in benign, borderline, and malignant group was  $34,29 \pm 19,16$  years;  $48,40 \pm 11,94$  years; and  $44,57 \pm 11,04$  years, respectively. This observation suggests that as the age increases, the incidence of ovarian tumors increases too. In 2009, Ovarian Cancer National Alliance reported that the incidence of ovarian tumors will increase among women older than 45 years and decrease among women younger than 45 years.<sup>12</sup> In 2012, IARC (International Agency for Research on Cancer) reported that in Indonesia, ovarian cancer was the second most prevalent gynecologic cancer after cervical cancer with the incidence rate amounted to be 9,664 cases in 2008. The age group between 41 to 50 years is the largest age group suffering from ovarian tumors as many as 62.7%. It was less prevalent among the age group of 31 to 40 years (10.8%).<sup>13</sup> Another study by Choudhury et

al (2012) obtained an average age of 38,1 years for benign ovarian tumor and 38,2 years for malignant ovarian tumor.<sup>14</sup>

The mean of parity in the benign type epithelial tumor group in this study was  $1.14 \pm 1.77$ , borderline type was  $2.0 \pm 1.70$  and malignant was  $1.74 \pm 1.36$ . Jordan et al (2009) reported that history 2 or 3 births with a history of preterm labor was associated with 60% and 90% increased risk of ovarian cancer, although the observation was not statistically significant.<sup>15</sup>

One sample (2.5%) was negative for caspase-3 expression among the benign group, 5 samples (12.5%) were negative among borderline, and 18 samples (45%) were negative among the malignant group. There was a significant difference of caspase-3 expression between benign, borderline and malignant epithelial ovarian tumors. Budiana, et al (2013) found the same result that 44.4% of caspase-3 positive expression and caspase-3 negative expression were 55.6% in ovarian cancer.<sup>16</sup> Chen W et al (2010) found 93.4% caspase-3 positive expression in benign ovarian tumors and 48.8% in ovarian cancer.<sup>17</sup> This result showed the role of caspase-3 in the mechanism of apoptosis as an execution caspase that the higher caspase-3 expression means the apoptotic mechanism work properly. Similarly, if low expression of caspase-3 indicates a disturbance in the process of apoptosis which later became the cause of an advanced stage of ovarian tumor. It can be explained that caspase-3 is highly expressed in a well function cell immune system, thus caspase-3 has an important role in the regulation of apoptosis in the immune system.<sup>1,18</sup>

In benign epithelial ovarian tumors, we found 1 sample with negative caspase-3 expression (14.3%) and 6 samples (85.7%) with positive expression. In borderline epithelial ovarian tumors we found a similar proportion of negative and positive caspase-3 expression, i.e. 5 samples (50%). There was no significant difference in caspase-3 expression between benign and borderline epithelial ovarian tumors ( $p = 0,304$ ). Unlike invasive ovarian carcinomas, borderline ovarian tumors have nuclear and cytoplasmic atypia (distinguishing part with benign tumors), absent / absent stromal invasion (distinguishing part with malignant tumor), unequal degree of epithelial cell proliferation with stratification cellular features include exceptional atypical architecture and papillary projection formation. The absence of a stromal invasion is a principle criteria rather than a borderline ovarian tumor.<sup>19</sup>

Distinguishing borderline ovarian tumors with benign ovarian tumors is important to avoid overdiagnosis. Hauptmann et al (2017) suggests that according to WHO 2014 classification, most authors agree that more than 10% of histologically borderline cells are actually benign ovarian tumors (e.g. cystadenoma or cystadenofibroma). On the other hand, serous cystadenoma with foci of cells with borderline epithelial characteristics and less than 10% of cell volume is categorized as cystadenoma / fibroma with focal epithelial proliferation. From a multicenter cohort study, it was reported that overdiagnosis of borderline ovarian tumors occurred in 11.5% (92/803) of patients.<sup>20</sup> Kimio Ushijima et al (2015) argues that frozen section results in mucinous borderline tumors often do not accurately reflect histologic

cell structures. Different or discordant diagnosis occurred in 34% of mucinous borderline tumors. Potential factors that affect the accuracy of frozen diagnosis are tumor size greater than 10 cm and borderline elements less than 10%. If the tumor weighs more than 1.360 grams, the discordant rate can be 50%. In most cases (94%), there is a discordant diagnosis in tumor with more than 13 cm.<sup>21</sup>

In this study, 85.7% of epithelial ovarian tumors with positive caspase-3 expression were benign and 50% were borderline epithelial ovarian tumors, although the observation were not significant. The magnitude of caspase-3 positive expression in benign epithelial ovarian tumors signifies that apoptosis still work well and good in positive expression of caspase-3 compared with no caspase-3 expression of the cell. Cells with uncontrolled proliferation due to gene abnormalities will avoid apoptosis. With reduced caspase-3 expression, abnormal cells will continue to proliferate uncontrollably. It will present as cellular atypia and the ongoing process of mitosis produces growth and development of cells with poor differentiation.<sup>22</sup>

In this study, we found inverse pattern of caspase-3 expression between benign and malignant epithelial ovarian tumors. Caspase-3 positive expression was observed in 6 samples (15%) of benign epithelial ovarian tumors and in 5 samples (12.5%) of malignant ovarian tumors. Meanwhile, caspase-3 negative expression was found in 1 sample (2.5%) of benign epithelial ovarian tumor and in 18 samples (45%) of malignant ovarian tumor. There were significant difference in the expression of caspase-3 between benign and malignant types of epithelial ovarian tumor ( $p=0.004$ ).

In ovarian tumors, there is lack of caspase-3 transcripts and reduced expression of caspase-3 protein. Positive expression is higher in the early stages of ovarian epithelial malignant epithelial type (31%) compared advance stage (16.7%).<sup>23</sup> The higher the level of caspase-3 expression, the longer the survival of malignant ovarian tumor cells.<sup>24</sup> Similar observation were also reported by Budiana, et al (2016). They reported that there was a negative relationship between caspase-3 expression and the stage of ovarian cancer. In early-stage ovarian cancer, the rate of negative expression was 4.8% while the negative expression for advanced stage was 47.6%. Positive expression indicates that the apoptotic process still works properly and associated with early stage cancer. Contrary, a negative expression of caspase-3 indicates an impaired apoptotic process. Impaired apoptotic regulation will result in uncontrolled proliferation.<sup>22</sup> Low expression of caspase-3 result in carcinogenesis.<sup>23</sup>

Positive expressions were found in 5 (21.7%) out of 23 malignant samples, and in 5 (50%) out of 10 borderline samples. Negative expression found in 78.3% (18 samples) of malignant samples and in 50% (5 samples) of borderline sample. There was no significant difference of caspase-3 expression between malignant and borderline epithelial ovarian tumors ( $p=0,215$ ). Similar observation was reported by Cabral et al (2016) which found no difference in negative expression of p53 between borderline (16.7%) and epithelial ovarian malignant tumor (29.7%) ( $p=0.560$ ). Negative expression of p53 increased epithelial type of benign ovarian tumor, borderline to malignant. Protein-53 (p53) may stop

the progression of the cell cycle or activate apoptotic pathway if there has been an extension of DNA damage. In normal cells, p53 is constantly degraded by MDM2 on the cell nucleus so that the cell cycle will stop and eventually the cell has a short half life time. When DNA damage has occurred, several factors will cause MDM2 phosphorylation. p53 remains stable as well as cell levels will increase, providing transcription factors for some genes. TP53 mutation is common in overall human cancers including epithelial ovarian type cancer, protein transcription becomes inactive resulting in immunity / resistance to cell cycle degradation. Malignant ovarian tumors show the highest rates of expression when compared with borderline tumors and benign ovarian tumors. This gradual increase in p53 expression can be explained by the difference in life-rates between wild-type proteins (constantly degraded, short lived half-lives) and p53 mutations (immune / degradation resistant, long live half-lives). Although not statistically significant, the increased percentage of p53 negative expression in benign, borderline and malignant epithelial ovarian tumors is consistent with the theory.<sup>25</sup>

Increased negative expression of caspase-3 sin malignant epithelial tumor type (78.3%) compared to borderline type (50%) indicates the formation of high amount of 3-caspase antibodies in malignant tumors in order to induce cell death or apoptosis. Similar observation was reported by Caric et al (2013) who studied the immunoreactivity to specific antibodies in the ovaries. Antibodies against caspase-3 has low reactivity in serous borderline-type ovarian tumors and very strong reactivity in malignant serous type ovarian tumors, although the association was not significant.<sup>26</sup>

## 5. Conclusions and Suggestions

Higher expression of caspase-3 was demonstrated in benign epithelial ovarian tumor and lower expression in borderline and malignant epithelial type ovarian tumor. Further research on caspase-3 expression is needed until caspase-3 can be used as a new biomarker for early detection of epithelial ovarian tumors.

## References

- [1] Busmar, B. 2010. Ovarian Cancer. In: Aziz, MF, Andrijono., Siafuddin, AB, editors. *National Oncology and Gynecology*. First Edition. Jakarta: PT Bina Pustaka Sarwono Prawirohardjo. p. 468-527
- [2] Waruwu, D. 2013. "Relation of Patients With Overview of Ovarian Cancer Histopathology in Medan City 2010-2011" (thesis). Medan: University of North Sumatra
- [3] Jemal, A., Bray, F., Melissa., Ferlay, J., Ward, E., Forman, D. 2011. Global Cancer Statistics. *CA Cancer J Clin*, Vol 61: p. 69-90
- [4] Aziz, MF. 2009. Gynecological cancer in Indonesia. *J Gynecol Oncol*, Vol. 20: p. 8-10
- [5] Karyana, K. 2004. "Ovarian Cancer Profile at Sanglah Hospital Denpasar Period January-December 2002" (thesis). Denpasar: Udayana University
- [6] Le Page, C., Huntsman, DG, Provencher, DM, Masson, AMM 2010. Predictive and Prognostic Protein Biomarkers in Epithelial Ovarian Cancer:

- Recommendation for Future Studies. *Cancers Journal*, Vol 2: p. 913-954
- [7] Xuan Pu., Sarah JS, Z. Yimin., AR Emad., RG Andrew., IO Ellis., GM Stewart. 2017. Caspase-3 and caspase-8 expression in breast cancer: caspase-3 is associated with survival. *Journal of Springer Apoptosis*, Vol 22: p. 357-368
- [8] Khalil, H., Bertrand, MJM, Vandenabeele, P., Widmann, C. 2013. Caspase-3 and RasGAP: a stress sensing survival / demise switch. *Trends in Cell Biology Journal*, Vol 20: p. 1-7
- [9] Li, SX, Chai, L., Cai, ZG, Jin, L., Sun, Z. 2012. Expression of Survivin and Caspase-3 in Oral Squamous Cell Carcinoma and Peritumoral Tissue. *Asian Pacific Journal of Cancer Prevention*, Vol. 13: p. 5027-5031
- [10] Donovan, N., Crown, J., Stunell H. 2003. Caspase-3 in Breast Cancer. *The Clinical Cancer Research Journal*, Vol 9: p. 738-742
- [11] Vranic, A. 2013. Caspase-3 and Survivin Expression in Primary Atypical and Malignant Meningiomas. *ISRN Neuroscience Journal*, Vol 2013: p. 1-5
- [12] Ovarian Cancer National Alliance. Statistic of ovarian cancer. 2009. The National Cancer Institute's Surveillance, Epidemiology and Result Program. Washington DC. (online series). Available from: URL: <http://jco.ascopubs.org/content/21/20/3814.full.pdf+html>
- [13] IARC International Agency for Research on Cancer. 2012. Globocan 2012: Estimate Cancer Incidence, Mortality and Prevalence Worldwide in 2012. Available from: [www.globocan.iarc.fr](http://www.globocan.iarc.fr)
- [14] Choudhury Monisha, Seema Goyal, Mukta Pujani, Meenu Pujani. 2012. A Cytohistological study of p53 overexpression in ovarian neoplasm. *South Asian Journal of Cancer*, 1: 59-65.
- [15] Jordan, SJ, Green, AC, Nagle, CM, Olsen, CM, Whiteman, DC 2009. Beyond Parity: Association of Ovarian Cancer With Length of Gestation and Offspring Characteristics. *American Journal of Epidemiology*, Vol 170, No. 5: p.607-614. DOI: 10.1093 / aje / kwp185
- [16] Budiana, ING 2013. Association of B-Cell Lymphoma Protein-2 and Caspase-3 Expression in Ovarian Cancer. *Indonesian Journal of Biomedical Sciences*, Vol 7, Number 2: p. 67-73
- [17] Chen, W., Peng, P. 2010. Expression and clinical significance of xiap and caspase-3 protein in primary epithelial ovarian cancer. *Xi Bao Yu Fen Zi Mian Yi XueZaZhi* , Vol 26, Number 7: p.673-4
- [18] Lavrik, IN 2013. Systems Biology of Apoptosis. *Springer science*. p.1-204
- [19] Cormio, G., Vera Loizzi, Maddalena Falagarario, Dorian Scardigno, Donatella Latorre, Luigi E Selvaggi. 2013. Borderline Epithelial Tumors of the Ovary. *INTECH*. Chapter 4: p.77-95. <http://dx.doi.org/10.5772/54828>
- [20] Hauptmann, S., Friedrich, K., Redline, R., Avril, S. 2017. Ovarian borderline tumors in the 2014 WHO classification: evolving concepts and diagnostic criteria. *Springer Virchows Arch*, Vol 470: p. 125-142
- [21] Kimio Ushijima, Kawano, K., Tsuda, N., Nishio, S., Terada, A., Kato, H., Tasaki, K., Matsukuma, K. 2015. Epithelial borderline ovarian tumor: Diagnosis and treatment strategy. *Obstetrics and Gynecology Science*, Vol 58 (3); p. 183-187. <http://dx.doi.org/10.5468/ogs.2015.58.3.183>
- [22] Budiana, ING 2016. Caspase-3 expression correlation with cell differentiation grade, stage, and residual tumor size in epithelial ovarian cancer. *Bali Medical Journal (Bali Med J)* , Vol 5, Number 12: p. 158-162. DOI: 10.15562 /bmj.v5i2.259.
- [23] Wong, RSY 2011. Apoptosis in cancer: from pathogenesis to treatment. *Journal of Experimental & Clinical Cancer Research*, Vol 30, No.87: p. 1-14
- [24] Kleinberg, L., Dong, HP, Holth, A., Risberg, B., Trope, CG, Nesland, JM, Florenes, VA, Davidson, B. 2009. Cleaved caspase-3 and nuclear factor-κB p65 are prognostic factors in metastatic serous ovaria n carcinoma. *Elsevier Journal of Human Pathology*, Vol 40: p. 795-806
- [25] Cabral, VD, Cerski, MR, Sa Brito, IT, Kliemann, LM 2016. p14 expression differences in ovarian benign, borderline and malignant epithelial tumors. *Journal of Ovarian Research*. p. 1-7. DOI: 10.1186 / s13048-016-0275-2
- [26] Caric, A., Poljicanin, A., Tomic, S., Vilovic, K., Babic, MS, Vukojevic, K. 2013. Apoptotic pathways in ovarian surface epithelium of human embryos during embryogenesis and carcinogenesis: Close relationship of developm ental plasticity and neoplasm. *Elsevier Acta Histochemica Journal*, Vol 116: p. 304-311