

# Clinicopathological Study of Tumour and Tumour like Lesions of Nose and Paranasal Sinuses

Dr. Swati B. Ghanghurde, Dr. Manjusha Dhawle

**Abstract:** The present study is a prospective study of 50 cases of non neoplastic and neoplastic lesions of the nose and paranasal sinuses, carried out in the department of pathology and ENT, in a tertiary care hospital between oct 2011 and oct 2013. This study was undertaken to study the frequency, age and sex wise distribution, correlate clinical and pathologic findings and to classify neoplastic and non neoplastic lesions of the nose and paranasal sinuses. Among 50 cases, 14 were neoplastic and 36 were nonneoplastic. Among the nonneoplastic lesions, nasal polyp was common, followed by rhinoscleroma; while in benign lesions papilloma was the commonest lesion followed by hemangioma, pleomorphic adenoma and neurofibroma. These benign tumours were seen in the 2<sup>nd</sup>, 4<sup>th</sup> and 7<sup>th</sup> decades of life; while for the malignant neoplasms the peak incidence was seen in the 6<sup>th</sup> and 7<sup>th</sup> decades of life. Nonneoplastic lesions were common in 2<sup>nd</sup>, 3<sup>rd</sup>, 4<sup>th</sup> decades of life. In all the lesions there was a female predominance.

**Keywords:** Polyp, paranasal sinus, papilloma, neoplastic.

## 1. Introduction

The nose is the most important part of the face with substantial aesthetic and functional significance. A variety of neoplastic and nonneoplastic conditions involve the nasal cavity and paranasal sinuses. The presenting feature, symptomatology and advanced imaging technique help to reach a presumptive diagnosis but histopathological diagnosis remains the mainstay of final definitive diagnosis. Although neoplasms of the nose and paranasal sinuses are not common, they are of the interest because of their various types. It has been found that the nose and paranasal sinuses accounts for less than 1% of all malignant tumours and not more than 3% of head and neck region malignancies (1). Careful histological work up is essential for a correct diagnosis and timely intervention of tumour and tumour like lesion of nose and paranasal sinuses (2).

The aim of this clinicopathological study was to find out the incidence of neoplastic and nonneoplastic lesions of the nose and paranasal sinuses, mode of presentation and histological types.

## 2. Materials and Methods

This study was conducted in the department of pathology in a tertiary care hospital. It is a prospective study of three years. The formalin fixed specimen were received with complete clinical and radiological features. Tumours and tumour like lesions were included in the study. Routine gross examination and required number of sections were taken and stained with haematoxylin and eosin. The diagnosis of sinonasal lesions were made on the basis of clinical presentation, gross morphology and light microscopy.

## 3. Results

A total of 50 cases were studied prospectively for a period of 3 years in a tertiary care hospital. The patients admitted to our hospital were selected. Histopathological examination revealed that nonneoplastic cases (36 cases-72%) outnumbered the neoplastic cases(14cases- 28%). Out of the

14 neoplastic lesions 9 cases (64.3%) were benign and 5 cases (35.7%) were malignant. In nonneoplastic lesions 34 cases (68%) were nasal polyps and 2 cases (4%) were of rhinoscleroma. In benign tumours we had 4 cases (8%) of papilloma, 3 cases of hemangioma (6%) and 1 case of pleomorphic adenoma and neurofibroma. (2%). While squamous cell carcinoma 5 cases (10%) constituted all the malignant cases. Tables 1 & 2 shows the distribution of various tumours and tumour like lesions of nasal cavity.

**Table 1:** Showing incidence of tumour and tumour like lesions of nose and paranasal sinuses. (n=50)

Lesion	No. of Cases	Percentage (%)
Tumours	14	28
Tumour Like Lesions	36	72
Total	50	100

**Table 2:** Showing lesion wise distribution of cases (n=50)

S.No.	Lesions	No. of Cases	Percentage
1	<b>Benign Tumours</b> Papilloma	4	8
2	Pleomorphic Adenoma	1	2
3	Hemangioma	3	6
4	Neurofibroma	1	2
5	<b>Malignant Tumours</b> Squamous Cell Carcinoma	5	10
6	<b>Tumour Like Lesion</b> Nasal Polyp	34	68
7	Rhinoscleroma	2	4

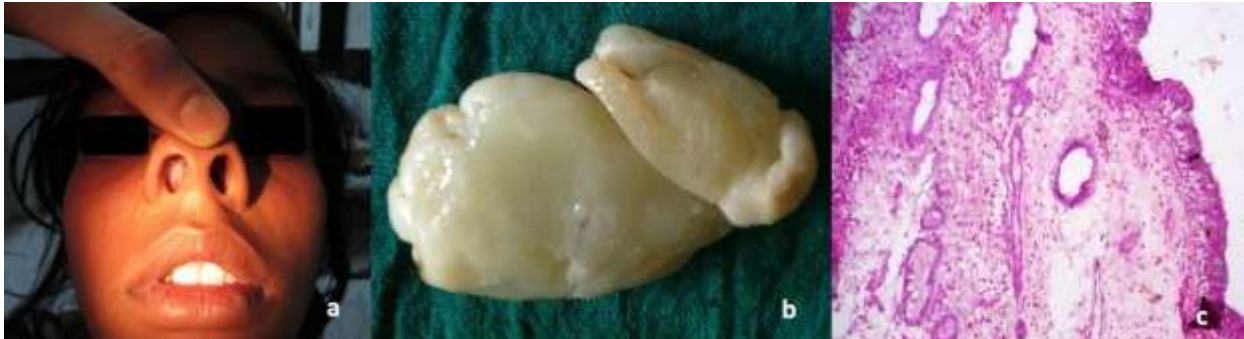The tumour like lesion were common in all the age groups with peak incidence in 2<sup>nd</sup>, 3<sup>rd</sup> and 4<sup>th</sup> decades. While the benign lesions were common in 2<sup>nd</sup>, 4<sup>th</sup> and 7<sup>th</sup> decades. The malignant lesions were common in the 4<sup>th</sup>, 6<sup>th</sup> and 7<sup>th</sup> decades of life

14 cases of tumour like lesions were seen in males (38.9%) and 22 cases (61.1%) were seen in females. (M:F ratio 0.6:1)

In benign neoplasms, 4 cases were males (44.4%) and 5 cases (55.6%) were females (M:F ratio 0.8:1), while all malignant lesions were seen in females 5 cases(100%). So in all these cases there was a female preponderance. (Table 3,4 and 5 shows the distribution of tumour like lesions, benign and malignant neoplastic lesions of nose and paranasal sinuses.)

**Nasal Polyp:** It is the most common tumour like lesion of the nose and paranasal sinuses. This lesion was seen in all age groups. However the peak was seen in the 3<sup>rd</sup> decade (44.1%) followed by 2<sup>nd</sup> and 4<sup>th</sup> decades (20.6%). Most of them were seen in females (64.7%). The most common complaint was blocking of nose(91.1%).Fig 1a shows the clinical photograph of polyp having polypoidal growth in the

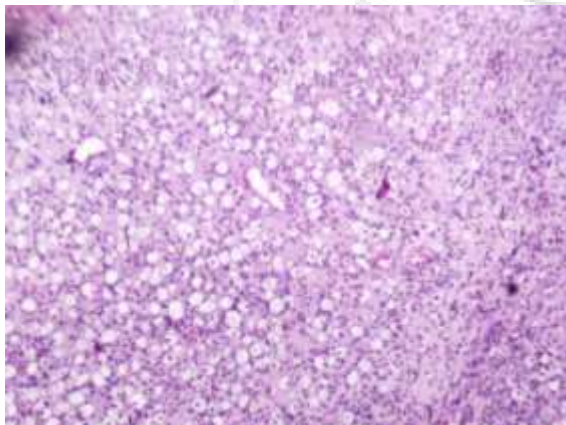
right side of nose. On gross the mass was smooth, shiny bluish gray to pink; polypoid (fig 1b). On microscopic examination the polyps were lined by respiratory or metaplastic squamous epithelium. Underneath the stroma is infiltrated by lymphocytes, plasma cells, few polymorphs and eosinophils. (fig 1c).



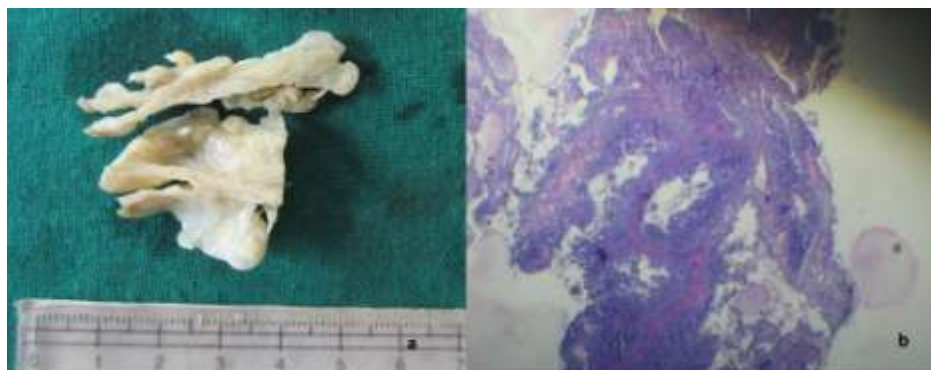
**Figure 1:** Nasal polyp a.Clinical photograph showing polypoidal growth in the right side of nose. Fig b. Gross photograph showing polypoidal mass. Fig c. Microphotograph of Inflammatory Polyp showing lining epithelium, underneath oedematous stroma with inflammatory infiltrate.( H & E 400x)

**Rhinoscleroma:** The peak age of presentation is second decade and were seen in males. The most common presenting complaint was blocking of nose and foul smelling nasal discharge. Microscopic examination showed chronic inflammatory cell infiltrate and typical Miculicz's cells in the stroma (fig 2).

**Papilloma:** Out of 9 benign tumours, there were 4 cases (44.44%) of papilloma. They were common in the 5<sup>th</sup> decade (50%) with female preponderance. They presented with blocking of nose and nasal discharge. On gross they presented with cauliflower or mulberry like bulky mass with firm consistency (fig 3a). On microscopy the epithelium was arranged in papillary fashion with central fibrovascular core.(fig 3b)

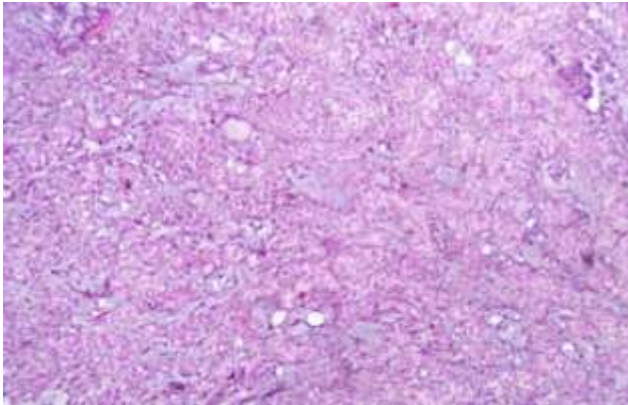


**Figure 2:** Microphotograph of Rhinoscleroma showing chronic inflammatory cell infiltrate and typical Miculicz's cells in the stroma. (H & E 200x)



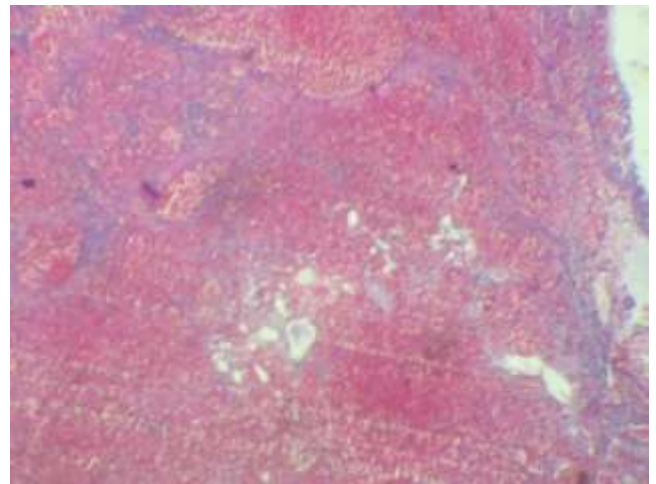
**Figure 3 (a):** Gross photograph of sinonasal papilloma. Fig 3b: Microphotograph of papilloma showing epithelium arranged in papillary fashion (H & E 200x)

**Pleomorphic Adenoma:** We had a single case of pleomorphic adenoma that was seen in the 7<sup>th</sup> decade in a female. It presented with epistaxis, headache and mouth breathing. On gross it presented with multiple greyish white firm masses. Microscopic examination showed strands of myoepithelial and epithelial cells having uniform nuclei surrounded by dense collagen and myxoid material (fig 4).



**Figure 4:** Microphotograph of Pleomorphic adenoma showing epithelial and myoepithelial cells with myxoid material (H & E 200x)

**Hemangioma:** There were 3 cases of hemangioma (33.33%). They were seen in 2<sup>nd</sup>, 4<sup>th</sup> and 7<sup>th</sup> decade of life and common in males (66.67%). The common presenting complaint was blocking of nose, mass in nasal cavity and epistaxis. On gross they presented as dark red coloured masses with smooth surface with variable consistency. On microscopy showed proliferating capillaries containing RBCs in the lumen lined by epithelial cells (fig 5).

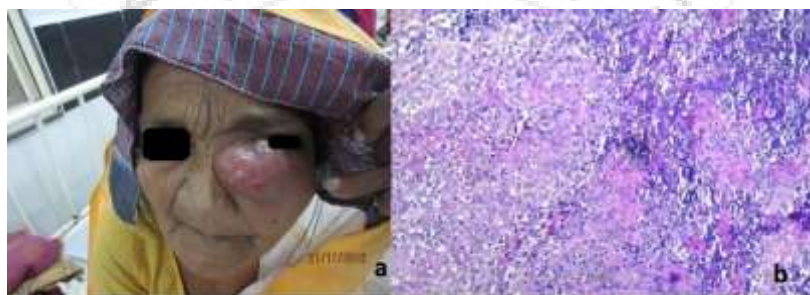

**Figure 5:** Microphotograph of Hemangioma showing proliferating capillaries containing RBCs (H&E 400x)

**NEUROFIBROMA:** There was a single case of neurofibroma seen in the 2<sup>nd</sup> decade in a male. On gross it showed greyish white firm mass. Microscopic examination revealed circumscribed lesion formed by fascicles of spindle cells with spindle nuclei. Collagen formation was seen with no atypia.

#### Squamous Cell Carcinoma

We had five cases of squamous cell carcinoma, which was the only malignant lesion seen in nose and paranasal sinuses. It was commonest in the 7<sup>th</sup> decade (60%) and all these cases were seen in females. They presented with blocking of nose, difficulty in breathing, epistaxis, nasal discharge and ophthalmic symptoms. Fig 6a shows clinical photograph of squamous cell carcinoma with swelling over the inner side of left eye. On gross they presented as broadly implanted polypoid mass having firm to hard consistency. On microscopic examination tumours were composed of round to polyhedral cells with scanty eosinophilic cytoplasm, arranged in sheets with keratin pearls (fig 6b).



**Figure 6:** Squamous cell carcinoma a. Clinical photograph with swelling over inner side of left eye b. Microphotograph showing tumour cells arranged in sheets (H & E 400x)

#### 4. Discussion

The present study of the tumour and tumour like lesion of the nose and paranasal sinuses include 50 cases studied over a period of 3 years. Out of these 50 cases 14 cases (28%) were neoplastic and the remaining 36 (72%) cases were tumour like non neoplastic lesions. These findings were comparable with those of Bhople et al<sup>3</sup> and Zafaret al<sup>2</sup>. Out of the neoplastic lesions, 9 cases (64.3%) were benign and the remaining 5 cases (35.7%) were malignant lesions. The incidence of benign tumours in our study is higher than the

malignant tumour which is similar to Dasgupta et al<sup>4</sup> who reported the incidence of benign tumours as 75.9% and that of malignant tumours are 24.1%. but Bhople et al<sup>3</sup> and Bejerregaard et al<sup>5</sup> reported the incidence of benign tumours as 45% and 38.8% and that of malignant tumours as 55% and 63.2%.

It is important to recognize the range of non neoplastic lesions in this region and to differentiate them from neoplastic lesions because of different treatment modality and emotional burden on patient.

In the present study, amongst 36 tumour like lesions studied, nasal polyp was the commonest. The incidence of nasal polyp in our study was 94.4% which is similar to the observation by Lathiet al<sup>6</sup> and Khan et al<sup>7</sup>. The age range is similar to the findings of Bhopleet al<sup>3</sup>, Dasgupta et al<sup>4</sup>, Dandapeth et al<sup>8</sup> and Drake lee et al<sup>9</sup>. But Friedman<sup>10</sup> reported a peak incidence of nasal polyp in 5<sup>th</sup> to 6<sup>th</sup> decade of life. In our study there was a female preponderance which is similar to the study of Bakaret al<sup>11</sup>. The clinical presentation was also similar to that observed by Zafaret al<sup>2</sup>.

The incidence of Rhinoscleroma in our study was 5.5% which is similar to that of Bejerregaard et al<sup>5</sup>, Khan et al<sup>7</sup> and Zafar et al<sup>2</sup>. All the cases were seen in the 3<sup>rd</sup> decade of life that were similar to Lathi et al<sup>6</sup> and Abouseif et al<sup>12</sup>.

Amongst the benign tumours the incidence of papiloma was 44.4% which is similar to that of Swamyetal<sup>13</sup> while a low incidence was observed by Bhople et al<sup>3</sup> and Dasgupta et al<sup>4</sup>.

While the incidence of capillary hemangioma in our study was 33.3% which is similar to the study of Bhopleet al<sup>3</sup> but higher incidence was noted by Dasgupta et al<sup>4</sup> which was 45.7%.

We had a single case of Pleomorphic adenoma (11.1%). The incidence is similar with that of Khan et al<sup>7</sup> who noted an incidence of 12.5% and a very rare case of Neurofibroma.

Out of the total 14 neoplastic lesions we had 5 cases (35.7%) of malignant lesions. All these cases were squamous cell carcinoma. The incidence in our study is similar to Lathiet al<sup>6</sup> and Fasunal et al<sup>14</sup>. But Bhopleet al<sup>3</sup>, Sharma et al<sup>15</sup>, Friedman et al<sup>10</sup> observed a higher incidence. The peak age incidence was seen in 7<sup>th</sup> decade which is similar to that noticed by Khan et al<sup>7</sup> and all the cases were seen in females which is similar to Bakari et al<sup>11</sup> but in the study of Khan et al<sup>7</sup> it showed a male preponderance.

## 5. Conclusion

Amongst the tumour like lesions, nasal polyp was the commonest lesion followed by rhinoscleroma and these lesions were common in the 2<sup>nd</sup>, 3<sup>rd</sup> and 4<sup>th</sup> decades of life with a female preponderance.

Amongst the benign neoplastic lesions papilloma was common followed by capillary hemangioma. The common age group was in the 2<sup>nd</sup>, 4<sup>th</sup> and 7<sup>th</sup> decades of life with a female preponderance.

While malignant lesions were less as compared to benign lesions, squamous cell carcinoma was the only malignant lesion observed in the 6<sup>th</sup> and 7<sup>th</sup> decades of life with a female preponderance.

## References

[1] Modh SK, Delwadia KN, Gonsai RN. Histopathological spectrum of sinonasal masses- a study of 162 cases. International journal of current research and review 2013;5:83-1.

- [2] Zafar U, Khan N, Afroz n, Hasan SA, Clinicopathological study of nonneoplastic lesions of nasa cavity and paranasalsinuses.indian and pathol Microbial 2008; 51(1):26-9.
- [3] Bhople KS, Rathod R, tumours of nose paranasal sinuses and nasopharynx- a clinicopathological study. Indian medical gazette 1992;177-5.
- [4] Dasgupta A, Ghosh RN, Mukherjee C. nasal polyps – histopathological spectrum, Indian J otolaryngol Head Neck Surg 1997; 106(4): 337-41.
- [5] Bjerregaard B, Okoth-Olende CA, GateiD, Bal IS, JensenH, tumours of nose and maxillary sinus. Ten years survey from Kenya J LaryngolOtol 1992;106(4):337-41.
- [6] Lathi A, Syed MM, Kalakoti P, Qutub D, KishneSp- Clinicopathological profile of sinonasal masses: a study from tertiary care hospital of India. ActaOtorhinolaryngolItal 2011; 31(6):372-7.
- [7] Khan N, Zafar U, Afroz N, Ahmed SS, Hasan SA. Masses of nasal cavity ,paranasal sinus, nasopharynx- a clinicopathological study. Indian J of Otolaryngol Head Neck Surg 2006;58(3):259-63.
- [8] Dandapeth A, Banerjee Dk, Sanyal S, Roy M, Bhattacharya A, Basu A. Nasal polyp: A clinicopathological study. Indian j of Otolaryngol Head Neck Surg 1993;45(4),219-22.
- [9] Drake-lee A, Nasal polyps in identical twins, Jlaryngol Otol. 1992;106(12):1084-5.
- [10] Friedman I, Osborn DA, Pathology of granulomas and neoplasms os nasal and paranasal sinuses, Edinburg:Churchill Livingstone;1982.
- [11] Bakari A, Afolabi OA, Adoga AA, Kodiyi AM, Ahmad BM. Clinicopathological profile of sinonasal masses: an experience in national ear care centre Kaduna, Nigeria. BMC Res Notes 2010;3:186.
- [12] Abou-seif SG, Baky FA, El-E brashy F, Gaafar HA, Scleroma of the upper respiratory passages: a CT study J LaryngolOtol 1991;105(3):198-202.
- [13] Swamy N, Gowda BV. A clinical study of benign tumours of nose and paranasal sinuses. Indian J of Otolaryngol Head Neck Surg 2004;56(4):265-8.
- [14] Fasunala AJ, Lasisi AO, sinonasal malignancies: a 10 year review in a tertiary health institution, J Natt Med Assoc 2007;99:1407-10.
- [15] Sharma S, Sharma SC, Singhal S, Mehra YN, Gupta BD, Ghoshal S et al. carcinoma of the maxillary antrum- a 10 years experience. Ind J of Otolaryngol 1991;43(4):191-4.