International Journal of Science and Research (IJSR)
ISSN (Online): 2319-7064
Index Copernicus Value (2016): 79.57 | Impact Factor (2015): 6.391

Computed Tomography Evaluation of Pathological Lesions and Normal Variants of Paranasal Sinuses

Shreya P. Desai[1], Mona Shastri[2]

[1]Resident, Department of Radiodiagnosis, SMIMER Medical College, Surat, C-901, Sangini Residency, City Light, Surat – 395007

[2]Professor & Head, Department of Radiology, SMIMER Medical College, Surat 44, Meharnagar, Adajan Gam cross road, Surat - 395009

Abstract: ***Pathological lesions of the paranasal sinuses include a wide spectrum of conditions ranging from inflammation to neoplasms both benign and malignant. Since clinical assessment is hampered by the surrounding bony structure, diagnostic radiology is of paramount importance. CT demonstrates the anatomical details and true local extent of the disease, which is essential in choosing the appropriate treatment modality.***

Keywords: Paranasal Sinuses (PNS), Osteomeatal complex(OMC), Infundibulum, Hiatus, Meatus, Concha

1. Introduction

Pathological lesions of the paranasal sinuses include a wide spectrum of conditions ranging from inflammation to neoplasms both benign and malignant.[1] These sinuses are in close anatomical relationship with orbit, cranial fossa and pterygopalatine fossa. Hence early involvement of these areas is an important feature.

Since clinical assessment is hampered by the surrounding bony structure, diagnostic radiology is of paramount importance. While conventional plain radiography readily demonstrates maxillary and frontal sinus disease they provide limited views of the anterior ethmoid cells, the upper two thirds of the nasal cavity and the frontal recess.

CT imaging provides detailed information of the paranasal sinuses and is now well established as an alternative to standard radiographs. CT demonstrates the anatomical details and true local extent of the disease, which is essential in choosing the appropriate treatment modality[1].

2. Aims and Objectives

- To diagnose accurately the pathological lesions and anatomical variations of the paranasal sinuses.
- To diagnose accurately the site and extension of lesion into the surrounding structures and to assess bony involvement.
- To correlate clinical diagnosis with CT diagnosis.
- To help the surgeons before functional endoscopic sinus surgery and to avoid known hazard of the same.
- To establish the efficacy of CT in detection and treatment of various PNS lesions.

3. Materials and Methods

The study was conducted at a tertiary care hospital of south Gujarat from December 2014 to July 2015 where in 50 patients referred to the department of Radio diagnosis of SMIMER with clinically suspected diseases involving the paranasal sinus. The computed tomographic scans were done on the 16 slice ultrafast Philips CT machine.

The patient was positioned supine for axial sections and prone for coronal sections. The angulation was made parallel to hard palate for axial sections and perpendicular to hard palate for coronal sections with thickness of 5 mm for both coronal and axial sections.

The extent of imaging for coronal sections was from posterior margin of sphenoid sinus to anterior margin of nasal fossa and study was done in spiral mode, while for axial sections from hard palate to upper margin of frontal sinus were taken. The exposure parameters were 120kVp and 130mAs with 1.5 seconds scan time. Contrast agent Omnicare 350 was used if indicated, at a calculated dose of 300mg/kg weight as a single intravenous bolus injection after serum creatinine level was estimated. Finally clinical diagnosis was correlated with CT diagnosis. While all the patients with clinically suspected paranasal sinus diseases were included in the study, all traumatic conditions requiring paranasal sinus CT were excluded from the study.

4. Observations and Results

Out of the 50 patients included in the study with clinically suspected diseases involving the paranasal sinuses, amongst the normal variants, concha bullosa was the most common (30%), followed by Haller cells (18%), Onodi cells (8%), prominent agger nasi cells(6%), hypoplastic frontal sinus(6%).

There was a spectrum of age of the patients comprising of many decades. The Highest number of patients were in the age group of 21- 30yrs while the least were below 10 years. While the youngest age of the patient recorded was of 7 yrs. The highest recorded age was 59 years old.

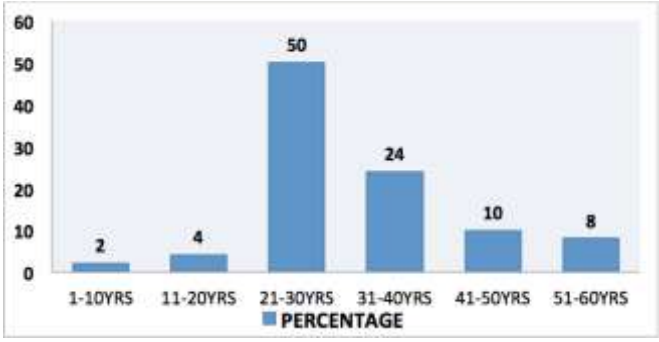

Figure 1: Age spectrum of patients

Out of 50, almost 2/3rd of patients were male (64%) and 1/3rd of patients were female (36%)

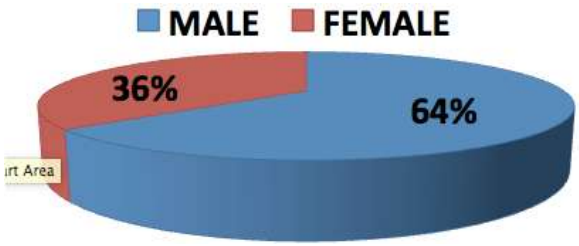

Figure 2: Gender representation of patients

Most of the patients had nasal obstruction (56%) followed by nasal discharge (28%), headache (24%). The least common complaint was sneezing (4%). Out of 46 positive cases, most common diseased sinus was maxillary sinus (95.6%), followed by anterior ethmoid (73.9%), posterior ethmoid (58.6%), frontal (56.5%) and sphenoid sinus (47.8%)

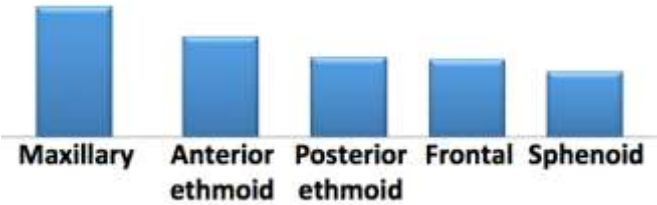

Figure 3: Graphical representation of involvement of sinus

Among the normal variants, concha bullosa was the most common (30%), followed by Haller cells (18%), Onodi cells(8%), prominent agger nasi cells(6%), hypoplastic frontal sinus(6%).

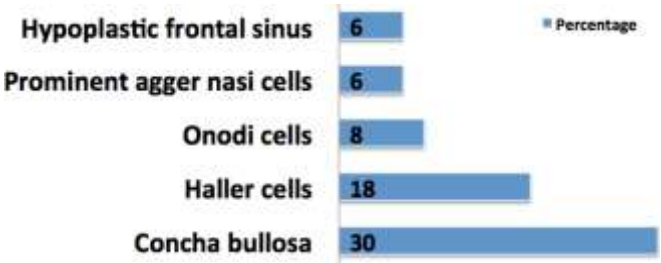

Figure 4: Graphical depiction of normal variants

FESS findings were similar to CT findings in 45 patients and different from CT findings in 1 patient. These different findings were related to fungal disease.

Table 1: Margin specifications

Margin	*A4 Paper*	*US Letter Paper*
Left	18.5 mm	14.5 mm (0.58 in)
Right	18mm	13 mm (0.51 in)

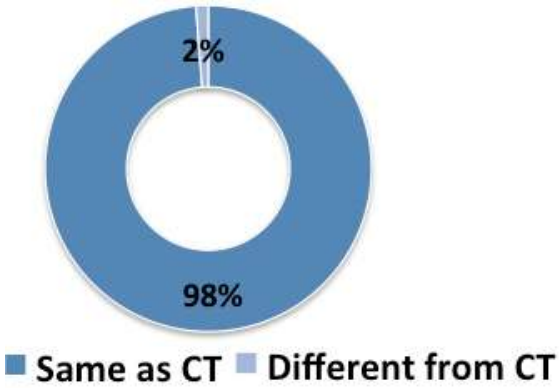

Figure 5: Pie depiction of FESS and CT coherence and incoherence

Biopsies of 46 patients were sent for histopathological examination. Inflammatory polyps were common among them in 21 patients, followed by chronic sinusitis 17 and fungal sinusitis in 3 patients, 1 patient of ethmoid sinus osteoma and 1 patient of nasopharyngeal carcinoma and 1 patient of angiofibroma and 2 patient of papilloma were evaluated.

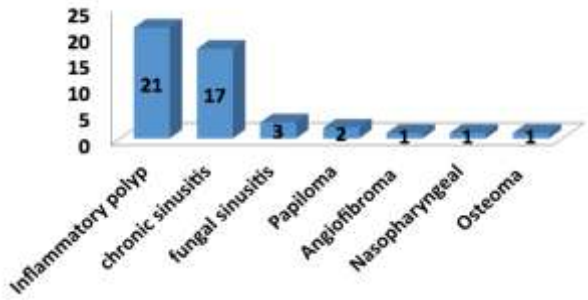

Figure 6: Bar depiction of spectrum of histopathological findings

Out of all cases of chronic sinusitis, 2 patients had pansinusitis. Deviated nasal septum was seen in 60% of patients with more common to right side. After comparing the clinical, CT and final diagnosis, best comparison observed between CT and final diagnosis.

	Chronic sinusitis	Polyp	Fungal sinusitis	Normal	Others
Final	34	42	6	8	10
CT	32	42	4	8	10
Clinical	84	10	2	0	4

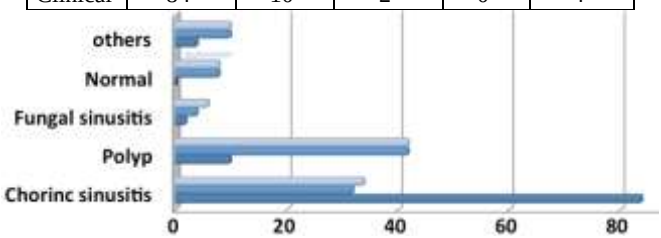

Figure 7: Bar depiction of spectrum of PNS findings

5. Discussion

There are four paired paranasal sinuses, one on either side of the midline. They develop from ridges in the lateral nasal wall by the eighth week of embryogenesis and continue pneumatization until early adulthood[2].

Each sinus is named after the bone in which it is located. Numerous variations in the sinonasal anatomy have been described. The paranasal sinuses are broadly divided into two major groups: the anterior sinuses and the posterior sinuses[3]. The anterior sinuses comprise the frontal sinus, anterior ethmoid air cells, and maxillary sinus. These drain into a common area centered in the middle meatus, the osteomeatal unit (OMU).
The posterior sinuses are the posterior ethmoid air cells and the sphenoid sinuses. These drain into the sphenoethmoid recess.

Sinusitis means inflammation of the sinus mucosa. Several forms are described based on the duration of symptoms. Acute sinusitis is almost always sudden in onset and may last up to 4 weeks. Subacute sinusitis is a continuation of the acute process and lasts anywhere between 4 and 12 weeks. Chronic sinusitis is defined as sinonasal inflammation that lasts for 12 weeks and beyond.[4] The disease is termed recurrent acute sinusitis when there are more than four episodes of acute sinusitis. CT is clearly superior to MRI for delineation of the bony anatomy and anatomic variants. CT shows the presence and extent of the sinonasal disease, nature of the sinonasal secretions and presence of any intrasinus calcifications. Hence CT is the preferred technique in preoperative evaluation of the paranasal sinuses and the accepted gold standard for delineation of inflammatory sinus disease due to obstruction.[5] Coronal CT images almost simulate the appearance of the sinonasal cavities at endoscopy and are most preferred by endoscopic surgeons. Contrast CT or MRI have a role to play when there is suspicion of an intraorbital or intracranial extension of the disease.[6]

Polyp : Polyps are the commonest expansile masses in the sinuses and may be solitary or multiple They are generally small but may grow and become very deforming.[7] They result from accumulation of fluid in the deeper lamina propria of the sinus mucosa. Allergic polyps are generally multiple and occur most commonly in the ethmoid air cells.[8] An antrochoanal polyp is usually unilateral, solitary, and seen in young adults. It is a large polyp in the maxillary sinus that expands and fills the antrum and prolapses through the primary or accessory ostium into the nasal cavity. [11]
Juvenile nasopharyngeal angiofibroma is a benign but locally aggressive tumor with a very rich vascular supply from the internal maxillary artery and the ascending pharyngeal artery. It occurs almost exclusively in male adolescents, and patients generally present with epistaxis.[14] The site of origin is the sphenopalatine foramen and pterygopalatine fossa, and the sinonasal space is involved secondarily. They frequently grow to very large sizes and spread into adjacent regions along the skull base and superiorly into the cranial cavity.[9]

Nasopharyngeal carcinoma: Nasopharyngeal carcinomas appear as soft tissue masses most commonly centered at the fossa of Rosen Muller. Following administration of contrast the tumor mass and nodal metastases usually demonstrate heterogeneous enhancement.[11]

Odontogenic cysts and tumors that arise from the maxillary alveolar ridge may extend into the maxillary sinus and present as sinus masses. All of them are very well delineated at CT. The odontogenic cysts of significance to the sinonasal region include the radicular cyst, dentigerous cyst, and odontogenic keratocyst.[12] The radicular cyst is seen in relation to a carious tooth and appears as a well-defined cystic lesion bordered by a thin rim of cortical bone. Dentigerous cysts and odontogenic keratocysts are more common in the mandible. A dentigerous cyst is seen as a well-defined unilocular or multilocular cyst in relation to the crown of an unerupted tooth; the crown of the tooth projects into the cystic cavity.[13]

While sinusitis is generally a bilateral disease, adults with unilateral nasal obstruction must be evaluated carefully for a tumor. In adults, a unilateral nasal mass that obscures the roof of the nasal vault should be imaged before a biopsy is performed to rule out a meningoencephalocele. This is best done with MRI.[10] When appropriate, biopsy is important to determining treatment approach because imaging characteristics are often inadequate to predict a definitive diagnosis. While benign expansile lesions can be destructive, CT and MRI can generally delineate benign from malignant tumors, and most benign tumors today will be managed using endoscopic surgery

References

[1] Aribandi M, McCoy VA, Bazan C, III: Imaging features of invasive and noninvasive fungal sinusitis: A review. Radiographics 27:1283–1296,2007.
[2] Jeon TY, Kim HJ, Chung SK, et al: Sinonasal inverted papilloma: Value of convoluted cerebriform pattern on MR imaging. AJNR Am J Neuroradio 29:1556–1560, 2008.
[3] Reddy UDMA, Dev Bhawna: Pictorial essay: Anatomical variations of paranasal sinuses on multidetector CT–How does it help FESS surgeons. Indian J Radiol Imaging 22(4):317–324, 2012.
[4] Chakrabarti A, Denning DW, Ferguson BJ, et al: Fungal rhinosinusitis: A categorisation and definitional schema addressing current controversies. Laryngoscope 119:1809–1818, 2009.
[5] Hyams V: Papillomas of the nasal cavity and paranasal sinuses: A clinicopathologic study of 315 cases. Ann Otol Rhinol Laryngo 80:192–206, 1971.
[6] Som P: Tumors and tumor-like conditions of sino-nasal cavity. In Som P, Bergeron RT, editors: Head and Neck Imaging, ed 4, St. Louis, 2003, Mosby, pp 261–373.
[7] Momeni AK, Roberts CC, Chew FS: Imaging of chronic and exotic sinonasal disease : A review. AJR Am J Roentgenol 189:S35–S45, 2007.
[8] Nouraei SA, Elisay AR, Dimarco A, et al: Variations in paranasal sinus anatomy: Implications for the

pathophysiology of chronic rhinosinusitis and safety of endoscopic sinus surgery. J Otolaryngol Head Neck Surg 38(1):32–37, 2009.

[9] Som PM, Shugar JMA: Anatomy and physiology. In Som PM, Curtin DC, editors: Head and Neck Imaging, ed 4, St Louis, 2003, Mosby pp 87–148.

[10] Zinreich SJ, Abayram S, Benson ML, et al: The osteomeatal complex and functional endoscopic surgery. In Som PM, Curtin HD, editors: Head and Neck Imaging, ed 4, St. Louis, 2003, Mosby, pp 149–174.

[11] Gillespie MB, Huchton DM, O'Malley BW: Role of middle turbinate biopsy in the diagnosis of fulminant invasive fungal rhinosinusitis. Laryngoscope 110:1832–1836, 2000.

[12] Kazkayasi M, Karadeniz Y, Aarikan OK: Anatomic variations of sphenoid sinus on CT. Rhinology 43(2):109–114, 2005.

[13] Barnes L, Brandwein M, Som PM: Diseases of the nasal cavity, paranasal sinuses and nasopharynx. In Barnes L, editor: Surgical Pathology of the Head and Neck, ed 2, New York, 2003, Marcel Dekker, pp 509–517.

[14] Kantarci M, Karasen RM, Alper F, et al: Remarkable anatomic variations in paranasal sinus region and their clinical importance. Eur J Radiol 50(3):296–302, 2004.