

The Aesthetic in Prosthetic – A Case Series

Dr. Vasanta R Digole¹, Dr. Divya Devidas Naik², Dr. Nitesh Kumar Srivastava³

¹MDS, Endodontics, Govt. Dental College and Hospital, Nagpur, Maharashtra, India
^{2,3}MDS, Prosthodontics, Govt. Dental College and Hospital, Nagpur, Maharashtra, India

Corresponding Author

Dr Nitesh Kumar Srivastava

Phone: +91-9860108980, Email ID: nitesh17061980[at]gmail.com

Abstract: Laminate veneers are now a commonplace procedure in many practices due to their broad range of indications such as correction of alternations in tooth shape or position, changes in tooth colour, changes in morphology of teeth with microdontia or tooth transposition, presence of diastemas and/or poor incisal embrasures, repair of incisal fractures, extensive anterior dental restorations, enamel alterations (abrasion, attrition, abfraction).

Keywords: abrasion, attrition, abfraction, laminate veneers, esthetic rehabilitation

1. Introduction

In the current era, the layman is more conscious of his appearance than ever before. The rise in the demand for cosmetic rehabilitation or enhancement is a testimony to the heightened attention that 'beauty' is currently receiving.

The advent of composite resins by Bowen in 1958, followed by Fusayama and Nakabayashi's work in making adhesiveness a reality and finally the success found by Rochette in employing porcelain laminates conditioned by acid were the milestones along the way that has now culminated into a present where mimicking nature has almost become a reality.¹ Adhesive restorations meant greater preservation of natural tooth structure, higher patient compliance, lesser complications, better aesthetics and this directly translated into preference for composite and porcelain laminates over full coverage crowns.^{2,3,4} A number of clinical studies have concluded that bonded laminate veneer restorations delivered good results over a period of 10 years and more.⁵⁻⁸

Ceramic laminate veneers are now a commonplace procedure in many practices due to their broad range of indications such as correction of alternations in tooth shape or position, changes in tooth colour, changes in morphology of teeth with microdontia or tooth transposition, presence of diastemas and/or poor incisal embrasures, repair of incisal fractures, extensive anterior dental restorations, enamel alterations (abrasion, attrition, abfraction).⁹

This clinical report presents two cases of esthetic rehabilitation using ceramic laminates and composite.

2. Case Report

Case 1: Prosthetic Rehabilitation using Porcelain Laminates

A 34-year-old male patient complaining of discoloured teeth since childhood arrived at the Department of Prosthodontics, requesting correction. Clinical examination revealed yellowish-brown discoloration of all teeth in a mouth with an otherwise good oral hygiene, which was much more pronounced with the maxillary anterior teeth. (Fig. 1) Keeping the patient's aesthetic zone and monetary constraints in mind, prosthetic rehabilitation of the maxillary anterior teeth along with both premolars with porcelain laminates was done.

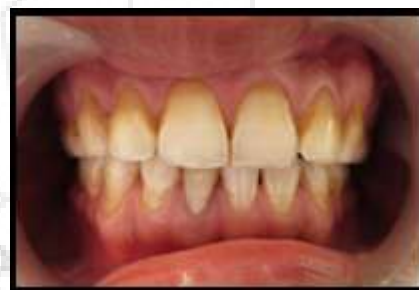

Figure 1: Intraoral anterior view of teeth before treatment.

A complete clinical and radiological examination was done and photographic documentation collected. Diagnostic impressions were made in irreversible hydrocolloid (Neocolloid; Zhermack) and poured in Type III gypsum product (Kalabhai Kalstone; Kalabhai Karson Pvt. Ltd., Mumbai). The models were mounted onto a semi-adjustable articulator which was programmed using a protrusive record obtained from the patient using aluwax (Aluwax, Aluwax Bite (Figure 2). A Preliminary wax mock-up was done on the diagnostic models and demonstrated to the patient. After appropriate modifications, a silicone index (Aquasil® Soft Putty – Regular Set, Dentsply®) was made as a guide during the subsequent tooth preparations. (Figures 3(a) and 3(b)).

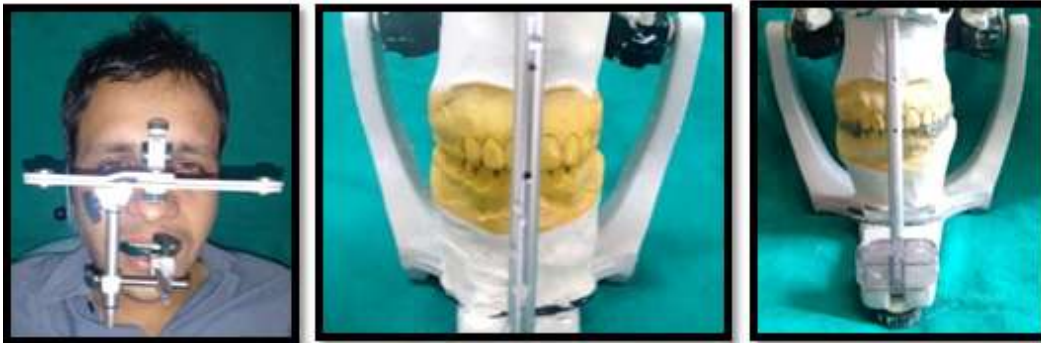


Figure 2: (a) Face bow transfer. (b) cast articulated in centric relation with programming the articulator using protrusive record

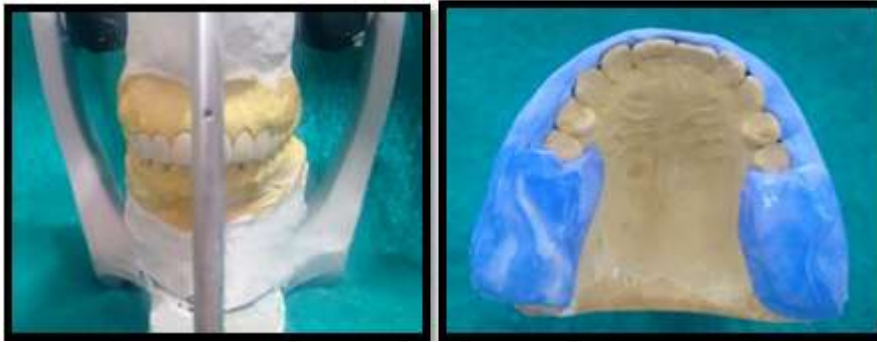


Figure 3: (a,b) Frontal view of the mock-up and Silicone index

The least invasive preparation with maximal preservation of enamel was performed. Pre-operative gingival retraction was done using #00 retraction cord (Ultrapak, Ultradent) for 8-10 minutes. Equigingival chamfer margins were placed on the labial surfaces of maxillary anterior teeth and the preparation was extended onto the proximal surfaces, stopping just short of the contact point. The silicone guide fabricated on the wax mock-ups was placed intraorally from time to time to judge the amount of reduction done and the amount still required (Figure 4). Once a clearance of approximately 0.5 mm was obtained, the preparations were finished and polished and isolated. Gingival retraction was performed again for about 8-10 minutes.

A double step, double impression was made using an addition silicone material (Aquasil® Soft Putty – Regular Set and Aquasil® LV Type III Light Bodied consistency, Dentsply®). The first stage putty impression was made keeping the retraction cord in place and using a cellophane sheet as a spacer. Following this, the spacer was removed and the retraction cord was removed from the sulci. Light body impression material was loaded onto the putty impression and at the same time, it was injected into the retracted sulcus using intraoral tips on the automix syringe, following which the loaded impression tray was placed back in the mouth (Figure 5). The final impression was poured in Type IV dental stone (Ultrarock; Kalabhai Karson, Mumbai, India)

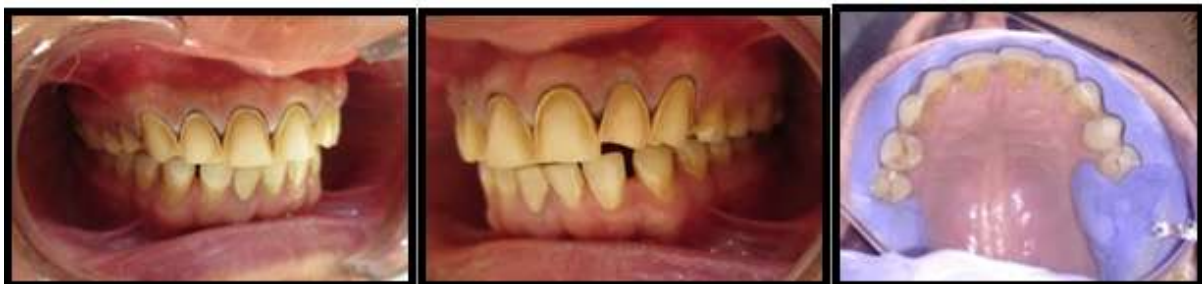

Figure 4: Preparation of teeth and verification by using silicone index

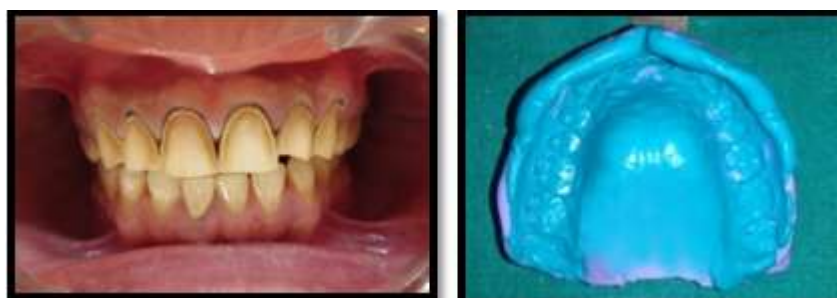


Figure 5: Ultrapak retraction cord in situ and final impression

A Bisque stage try-in was done. The teeth were cleaned with pumice and dried and the laminates were placed on the prepared teeth using a minimal quantity of petroleum jelly on the intaglio surface. The marginal adaptation was

checked both visually and with an explorer. Interferences were noted and appropriately reduced.

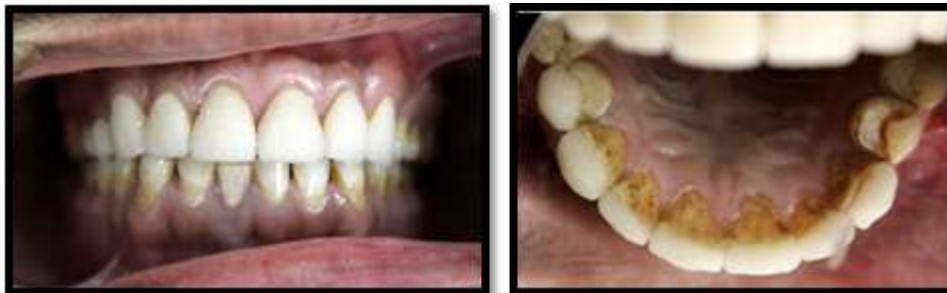

Figure 6: Evaluation of fit in bisque-stage trial

The final glazed porcelain laminates were tried in the patient's mouth and subsequently luted using a dual cure resin luting cement. Etching was done using 5% hydrofluoric acid (IPS Ceramic etching gel) for 10 seconds and rinsed for 10 seconds. A silane coupling agent (Monobond-S, Ivoclar vivadent) was used to facilitate the creation of high bond strength to the cement. A coat of bonding agent (Adper single bond 3M ESPE USA) was applied to the inner surface of the restorations and cured. The prepared teeth were subjected to etching with 37% phosphoric acid (3M ESPE, St. Paul, MN, USA) for 10 seconds followed by thorough rinsing for 10 seconds. After drying of the teeth and thorough isolation, bonding agent (Adper single bond 3M ESPE USA) was applied and after a period of 10 seconds, cured for 20 seconds.

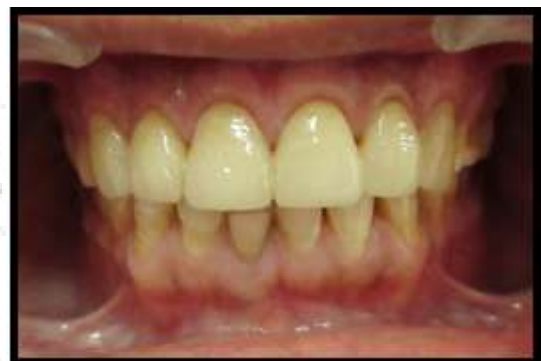

Figure 7: Postoperative intraoral view

A thin layer of the resin luting agent (Variolink II, Ivoclar vivadent, Liechtenstein) was dispensed onto the inner surface of veneers and each laminate was slowly seated on its respective tooth preparation while applying adequate pressure to ensure adaptation and flow of the luting agent. A flash cure of 5 seconds was done to gain stability and enable removal of excess luting agent using a sickle scaler. Subsequently a prolonged light curing was performed at palatal, facial and incisal surfaces for 40 seconds each. Following polymerization, any residual remnants of cement were removed with the help of a number 12 surgical blade and a dental probe and dental floss was used to confirm patency at the contact points (Figure 7)

Case 2: Minimally Invasive Aesthetic Rehabilitation using composite resin

A 27-year-old male patient arrived at the Department of Prosthodontics complaining about discoloured upper and lower anterior teeth. On clinical examination it was noted that the maxillary and mandibular anterior teeth had a hypoplastic appearance with horizontally running discoloured pitted groove across the crowns. As the defects were minimal and concentrated on a relatively small area on the crowns, aesthetic rehabilitation using composite resin with minimal tooth preparation was planned. Oral prophylaxis was performed in the pre-prosthetic phase. Shade matching for the composite material was done by first using a shade guide (Vitapan Classic Shade Guide, VITA). The closely matching shades were applied on one of the teeth in question and the exact shade was selected using digital photography with a grey card.

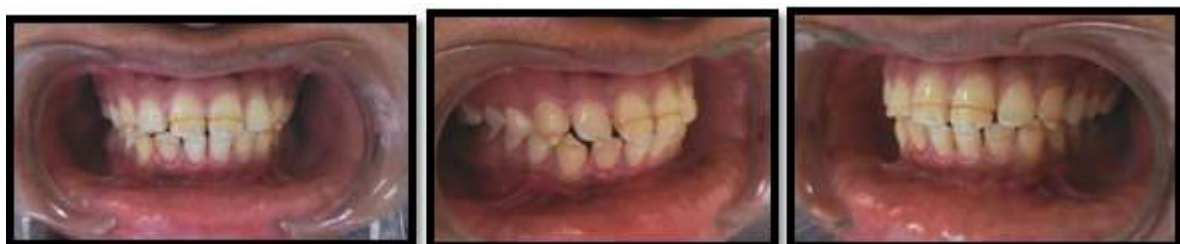

Figure 1: Preoperative intraoral view

The teeth in question were prepared in a highly conservative manner so as to only provide infinite bevels at the junction with the normal tooth structure. Etching was performed with 37% phosphoric acid (3M ESPE, St. Paul, MN, USA) for 10

seconds after which the teeth were rinsed for 10 seconds and dried.

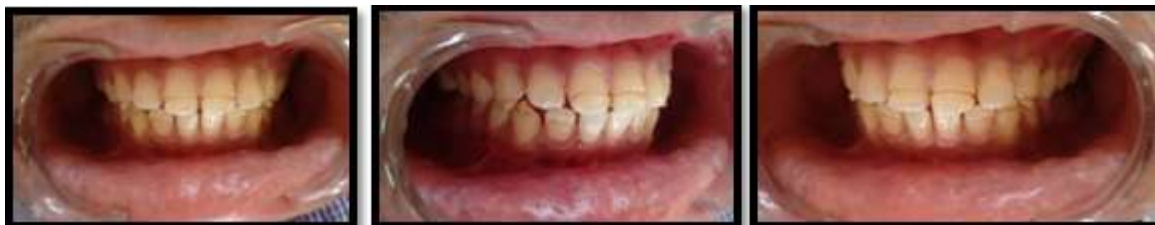

Figure 2: Preparation of teeth

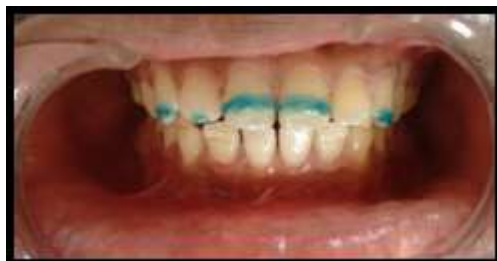

Figure 3: Etching of teeth

Two coats of bonding agent (Adper single bond 3M ESPE USA) were applied for 10 seconds, air dried and then cured. The selected shade of composite material (Filtek™ 3M, ESPE) was applied incrementally and cured. After gross restoration of the teeth in question, finishing and polishing procedures (SHOFU Composite Finishing and Polishing Kit, SHOFU) were carried out so as to achieve a superior aesthetic result and avoid chances of future discolouration.

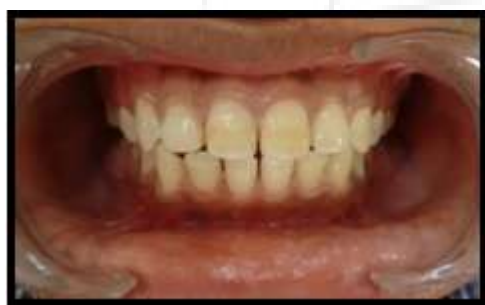

Figure 4: Postoperative intraoral view

3. Discussion

Aesthetic dentistry is an art and science that is more than a one-treatment-for-all modality. Thorough clinical and radiographic examination coupled with a clinician's expertise and patient demand and compliance all contribute towards determining the ideal treatment plan for a particular case. While localised defects such as Ellis Class I and Class II defects, localised areas of discolouration, minor pitting of the of the surfaces can all be managed easily with composites, larger areas of coverage may be better served by indirect restorations.

Composite resins, although technique sensitive, provide an excellent means of restoring aesthetics with minimal preparation of the original tooth structure. However, they have limitations such as the stringent moisture control required over extended lengths of time, the eventual discolouration seen over a period of time and post-operative sensitivity that all too often accompanies composite resin restorations. Nonetheless, composite resins have, undoubtedly, been very successfully used directly as

laminates and even for procedures as extensive as full mouth rehabilitations.

Indirect restorations, however, do have a distinct advantage when a more exhaustive treatment modality is planned. Greater control over the form and texture of the restoration as well as a better aesthetic result in terms of the shade variation, characterisation and replication of incisal translucency, justifies the attention that porcelain laminates have received in recent years. The recent advancements in porcelain clubbed with the ability to etch porcelain using hydrofluoric acid, as demonstrated by Simonsen and Calamia, have taken aesthetic dentistry a step closer to mimicking nature.

The presented cases demonstrate aesthetic rehabilitation by both, the conservative composite restorations and the indirect porcelain laminates.

Case 2 described the rehabilitation of minor pitting of the crown surfaces of teeth using a shade matched composite restoration. The edges of the pitted groove were minimally prepared to provide infinite bevels. This helps in making the composite restoration as indiscernible as possible. Rigorous finishing and polishing procedures were carried out so as to achieve maximum aesthetics and prevent future discolouration.

Case 1 described the aesthetic rehabilitation of more severely discoloured teeth using indirectly fabricated porcelain laminates. A minimal preparation with an incisal overlap was done to gain structural durability. Three basic types of incisal preparation have been described in the literature namely, the window or the intra-enamel preparation, the overlapped incisal edge preparation and the feathered incisal edge preparation. In the presented case, an overlapping incisal edge preparation, which has generally found favour with a number of authors.¹¹ A conservative thin chamfer margin placed equi-gingivally and gingival retraction with a retraction cord aided in replication of margins in the addition silicone impressions. The presented clinical report describes porcelain laminate veneers as an excellent option for effective, conservative, and aesthetic treatment.

In a nutshell, all of the treatment sequences are ruled by the same plan i.e. taking a detailed case history, diagnostic impressions, radiographs and mock-ups, proper clinical protocols along with consideration of adhesive systems, ceramics, ceramic etching, light curing, resin cements, and the correct photographic protocol.

4. Conclusion

Aesthetic rehabilitation of two cases, one using composite resin and the other using porcelain laminates was described in detail.

References

- [1] Benetti AR, Miranda CB, Amore R, Pagani C. Porcelain laminate veneers—esthetic alternative. *J Bras Dent Estet* 2003;2:186-194.
- [2] J. L. Ferracane, “Resin composite—state of the art,” *Dental Materials*, vol. 27, no. 1, pp. 29–38, 2011.
- [3] M. Peumans, B. Van Meerbeek, P. Lambrechts, and G. Vanherle, “Porcelain veneers: a review of the literature,” *Journal of Dentistry*, vol. 28, no. 3, pp. 163–177, 2000.
- [4] Pincus, C.R. (1938) Building Mouth Personality. *Journal of the California Dental Association*, **14**, 125-129.
- [5] B. LeSage, “Establishing a classification system and criteria for veneer preparations,” *Compendium of Continuing Education in Dentistry*, vol. 34, no. 2, pp. 104–117, 2013.
- [6] D. M. Layton and T. R. Walton, “The up to 21-year clinical outcome and survival of feldspathic porcelain veneers: accounting for clustering,” *The International journal of prosthodontics*, vol. 25, no. 6, pp. 604–612, 2012.
- [7] D. M. Layton, M. Clarke, and T. R. Walton, “A systematic review and meta-analysis of the survival of feldspathic porcelain veneers over 5 and 10 years,” *The International journal of prosthodontics*, vol. 25, no. 6, pp. 590–603, 2012.
- [8] Radz, G. (2011) Minimum Thickness Anterior Porcelain Restorations. *Dental Clinics of North America*, **55**, 353-370.
- [9] Friedman, M.J. (1998) A 15-Year Review of Porcelain Veneer Failure—A Clinician’s Observations. *Compendium of Continuing Education in Dentistry*, **19**, 625-628.
- [10] Simonsen RJ, Calamia JR. Tensile bond strength of etched porcelain. *Journal of Dental Research* 1983;62:297 Abstract 1154.
- [11] Christensen GJ. Have porcelain veneers arrived? *Journal of the American Dental Association* 1991;122:81