

Evaluation of Endometrial Layer Changes in Perimenopausal Women with Amenorrhea on Tamoxifen

Kawakeb N Abdulla¹, Saba J Alheshimi², Hanan Dh. Skheel Aljebory³, Hayder A. Fawzi⁴, Anas K. Awn⁵

¹Lecturer of Gynecology, Iraqi National Cancer Research Center, Baghdad University

²Lecturer of Gynecology, head of the Department of Gynecology & Obstetric, Maysan University

³Assistant Professor, College of Medicine Al Mustansyria University, Consultant Gynecology & Obstetrics

⁴B.Pharm, RPh, FICMS (candidate), The High Institute for Infertility Diagnosis and Assisted Reproductive Technologies, Al Nahrain College

⁵MBChB, Iraqi National Cancer Research Center / Baghdad University

Abstracts: ***Aim:** To evaluate the usefulness of vaginal ultrasonography in screening for endometrial disease in perimenopausal women with amenorrhea on tamoxifen. **Patients & Method:** 50 breast cancer patients with amenorrhea on tamoxifen were selected to study their endometrial thickness by using vaginal ultrasound, an endometrial thickness of > 5mm used as an abnormal result, and those sent for histopathological examination to see if their endometrium was normal or abnormal and what was the type of the abnormality. Patients with abnormal uterine bleeding excluded from the study. **Results:** From the 50 studied women, ten were having an endometrial thickness of >5mm (20%). Three cases were having endometrial adenocarcinoma (30%), and the rest with endometrial hyperplasia and polyp (70%). High body mass index was a risk factor for increase endometrial thickness and abnormality with a p-value of 0.007. **Conclusion:** Regular vaginal ultrasound examination of asymptomatic women with breast cancer on tamoxifen therapy is a valuable tool to follow the endometrium, and send the patient for histopathological examination for the endometrium if the thickness is > 5mm.*

Keywords: tamoxifen, endometrial thickness, breast cancer, vaginal ultrasound

1. Introduction

Worldwide, breast cancer is the most common cancer in women. It affects about 12% of women worldwide.⁽¹⁾ Breast cancer rates in Iraqi females represent number one of the ten leading cancers that affect women, with an incidence of 34% according to the Iraqi Cancer Registry.⁽²⁾

Tamoxifen is a medication that is used to prevent & treat breast cancer in women,⁽³⁾ which is a nonsteroidal agent with potent antiestrogenic properties which compete with estrogen for binding sites in breast and other tissues.⁽⁴⁾ It is indicated for the treatment of positive estrogen receptor (ER) breast cancer in pre- and postmenopausal women. It's commonly used for the management of breast cancer and as prophylactic in high-risk pre- and postmenopausal women.⁽⁴⁾ Tamoxifen as selective estrogen-receptor modulator adjuvant therapy, has side effects include menopausal symptoms, increased risk of thromboembolism, and a higher rate of endometrial hyperplasia, polyps, cancer.^(5, 6)

Tamoxifen may lead to a range of histological alterations in the endometrium, including cystic atrophy, endometrial polyp, hyperplasia, atypical hyperplasia, endometrial adenocarcinoma^(7, 8).

Up to one-half of breast cancer patients who treated with Tamoxifen may develop an endometrial lesion within 6-36 months. Although potential benefit of Tamoxifen treatment in breast cancer patients outweighs its risk; all patients

receiving Tamoxifen should undergo regular gynecologic evaluations⁽⁹⁾.

Ultrasound is sensitive, but not specific, for evaluating endometrial abnormalities. The normal postmenopausal endometrium appears as a single echogenic line and should not exceed 5 mm as a bilayer thickness^(10, 11).

The aim of the current study to evaluate the effectiveness of vaginal ultrasound as a screening tool for endometrial changes in patients on tamoxifen.

2. Patients and Methods

The current study was a retrospective study carried during the period from January 2016 to October 2016. All data collected from AL Sader hospital in Maysan province, Iraq. Fifty perimenopausal women with breast cancer from the stage (I – IV), with amenorrhea after using tamoxifen for the period between 6 - 48 months were selected for the study.

Data regarding age, their body mass index, parities, duration of tamoxifen use, any vaginal bleeding, history of diabetes mellitus, hypertension, family history of cancer, Her2 positive, endometrial thickness measurement were all obtained from the medical records of the patients.

Endometrial thicknesses were measured using transvaginal ultrasound for all patients. Any patient with abnormal uterine bleeding excluded from the study. Any patient with endometrial thickness > 5 mm were sent for diagnostic

curettage (D&C) to take an endometrial biopsy for histopathological examination and the result was registered. Number and their percentage or mean standard deviation used when appropriate, chi-square test, t-test (if both follow a normal distribution with no significant outlier) and binary logistic regression analysis were used. SPSS 20.0.0, GraphPad Prism 7.0 software used, the level of significant was < 0.05 .

3. Results

Demographic data illustrated in table 1. The age of the selected group range between 38-52 years with a mean 45.02 ± 3.76 years. The mean for BMI is 28.92 kg/m^2 , parity 3.7, duration of treatment 24.7 months. Vaginal ultrasound showed that 40(80%) patients with endometrial thickness of $\leq 5\text{mm}$, and 10(20%) with thickness $> 5\text{mm}$.

Table 1: demographic data

Variable	Value
Age (years) ^s	45.02 ± 3.76 (38 – 52)
BMI (kg/m^2) ^s	28.92 ± 3.97 (21 – 39)
Parity ^s	3.7 ± 1.7 (0 – 8)
Another disease	18 (36%)
Family history of cancer	20 (40%)
Her2 positive	22 (44%)
Duration of treatment (months)	24.7 ± 15.6 (6 – 48)
US (Endometrial thickness)	
$\leq 5\text{mm}$	40 (80%)
$> 5\text{mm}$	10 (20%)
Metastasis	6 (12%)
^s Mean \pm SD (range)	

Figure 1 and 2 showed that most of our selected patients were with breast cancer stage T₂ (52%, 26), and N₁ (66%, 33).

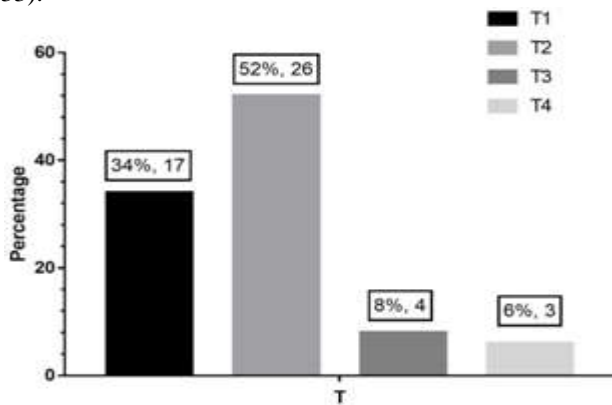


Figure 1: T staging of the patients

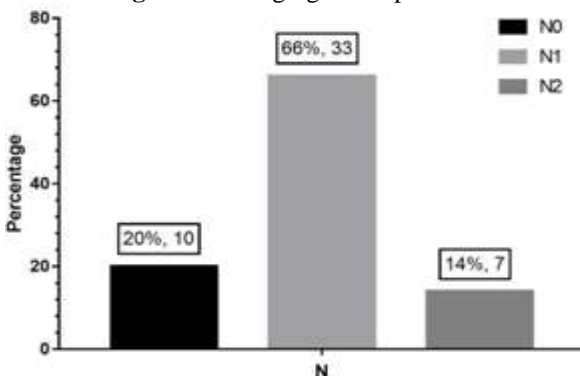


Figure 2: N staging of the patients

Table 2 showed that 10 out of the 50 studied group were having endometrial thickness $> 5\text{mm}$ and that BMI was significantly higher in these patients, with a p-value of 0.007, as illustrated in table 2.

Table 2: Comparison of different variables using US findings

	$\leq 5\text{mm}$	$> 5\text{mm}$	P value
Number	40	10	-
Age	44.8 ± 3.4	45.9 ± 5.2	0.537
BMI	28.2 ± 3.5	31.9 ± 4.4	0.007
Parity	3.8 ± 1.5	3.1 ± 2.3	0.234
Duration of Tx	24.0 ± 15.1	27.6 ± 17.9	0.519
Fx of cancer	17 (42.5%)	3 (30%)	0.470
T staging			
Stage T1	14 (35.0%)	3 (30.0%)	0.393
Stage T2	22 (55.0%)	4 (40.0%)	
Stage T3	2 (5.0%)	2 (20.0%)	
Stage T4	2 (5.0%)	1 (10.0%)	
N staging			
Stage N0	7 (17.5%)	3 (30.0%)	0.123
Stage N1	29 (72.5%)	4 (40.0%)	
Stage N2	4 (10.0%)	3 (30.0%)	
Metastasis	5 (12.5%)	1 (10%)	1.0
Her-2 positive	19 (47.5%)	3 (30%)	0.319

High BMI increases the risk of having an endometrial thickness above 5 mm with a p-value of 0.01. The presence of other diseases increases the risk of having an endometrial thickness above 5 mm by six folds, as illustrated in table 3.

Table 3: Association between different variables and US endometrial thickness $> 5\text{mm}$

Variables	OR (95%CI)	P value
Age	1.085 (0.895-1.315)	0.406
BMI	1.343 (1.059-1.705)	0.015
Parity	0.757 (0.478-1.197)	0.233
Other disease	6.152 (1.352-28.131)	0.019
Duration of Tx	1.015 (0.971-1.060)	0.511
Fx of cancer	0.580 (0.131-2.575)	0.474
Bleeding	28.249 (4.249-191.172)	0.001
T staging		
T1	0.429 (0.029-6.409)	0.539
T2	0.364 (0.026-5.026)	0.364
T3	2.000 (0.090-44.350)	0.661
T4	Reference	
N staging		
N0	0.571 (0.076-4.297)	0.587
N1	0.184 (0.030-1.142)	0.069
N2	Reference	
Metastasis	0.778 (0.080-7.518)	0.828
Her-2 positive	0.474 (0.107-1.098)	0.325
OR: odd ratio, 95%CI: 95% confidence interval		

4. Discussion

This study tried to evaluate the usefulness of vaginal ultrasound as a screening tool to detect endometrial disease in perimenopausal women with tamoxifen treatment for 6-48 months, and to compare the result of the ultrasound with the results of histopathology from the patients with an endometrium thickness $> 5\text{mm}$. As shown in the results we found that vaginal ultrasound is a useful tool to detect endometrial abnormality, and this findings is in agreement with a study done by Robert *et al.* (12), but in another study

of transvaginal ultrasonography, 300 asymptomatic postmenopausal women had no hyperplasia or cancer despite increased endometrial thickness, especially in heavier women(13).In our study, a high BMI is a risk factor for having an increase in endometrial thickness.

From the ten patients with endometrial thickness >5mm and in whom endometrial biopsy sent for histopathological examinations there werethree patients diagnosed as endometrial adenocarcinoma and the rest with endometrial hyperplasia and polyp mostly benign, and this result is in agreement with a study done by Burkart *et al.*(14).

5. Conclusion

Transvaginal ultrasound is a useful tool to screen women on tamoxifen to detect anabnormality in the endometrium and to send any patient with endometrial thickness> 5mm for histopathological examination of the endometrium even if the woman was asymptomatic.

References

- [1] McGuire A, Brown JA, Malone C, McLaughlin R, Kerin MJ. Effects of age on the detection and management of breast cancer. *Cancers*. 2015;7(2):908-29.
- [2] Registry IC. Iraqi Cancer Board, Ministry of Health, Republic of Iraq. 2011.
- [3] Fagerlin A, Dillard AJ, Smith DM, Zikmund-Fisher BJ, Pitsch R, McClure JB, et al. Women's interest in taking tamoxifen and raloxifene for breast cancer prevention: response to a tailored decision aid. *Breast Cancer Res Treat*. 2011;127(3):681-8.
- [4] Jordan VC. Fourteenth Gaddum Memorial Lecture. A current view of tamoxifen for the treatment and prevention of breast cancer. *British Journal of Pharmacology*. 1993;110(2):507-17.
- [5] Fisher B, Costantino JP, Redmond CK, Fisher ER, Wickerham DL, Cronin WM. Endometrial cancer in tamoxifen-treated breast cancer patients: findings from the National Surgical Adjuvant Breast and Bowel Project (NSABP) B-14. *J Natl Cancer Inst*. 1994;86(7):527-37.
- [6] Barbara L. Hoffman, John O. Schorge, D K. Breast disease. In: Werner CL, editor. *Williams Gynecology study guide*. 3rd ed. New York: McGraw-Hill Education; 2016.
- [7] Sesti F, Patrizi L, Ermini B, Palmieri G, Orlandi A, Piccione E. High-Grade Endometrial Stromal Sarcoma after Tamoxifen Therapy for Breast Cancer. *Gynecologic and Obstetric Investigation*. 2005;60(2):117-20.
- [8] Mbatsoho B, Le Bouëdec G, Michy T, Bourdel N, Fouilloux G, Dauplat J. Endometrial cancers arising in polyps associated with tamoxifen use. *Gynecology, obstetric&fertility*. 2005;33(12):975-9.
- [9] Ascher SM, Imaoka I, Lage JM. Tamoxifen-induced uterine abnormalities: the role of imaging. *Radiology*. 2000;214(1):29-38.
- [10] Ganz PA, Coscarelli A, Fred C, Kahn B, Polinsky ML, Petersen L. Breast cancer survivors: psychosocial

concerns and quality of life. *Breast Cancer Res Treat*. 1996;38(2):183-99.

- [11] Granberg S, Wikland M, Karlsson B, Norström A, Friberg LG. Endometrial thickness as measured by endovaginal ultrasonography for identifying theendometrial abnormality. *American journal of obstetrics and gynecology*. 1991;164(1 Pt 1):47-52.
- [12] Langer RD, Pierce JJ, O'Hanlan KA, Johnson SR, Espeland MA, Trabala JF, et al. Transvaginal Ultrasonography Compared with Endometrial Biopsy for the Detection of Endometrial Disease. *New England Journal of Medicine*. 1997;337(25):1792-8.
- [13] Andolf E, Dahlander K, Aspenberg P. Ultrasonic thickness of the endometrium correlated to body weight in asymptomatic postmenopausal women. *Obstetrics and gynecology*. 1993;82(6):936-40.
- [14] Burkart C, Wight E, Pok J, Kernen B, Traber M, Haller U, et al. [Ultrasound endometrium follow-up during tamoxifen treatment: Really not reliable or useful after all?]. *Ultraschall in der Medizin (Stuttgart, Germany : 1980)*. 2001;22(3):136-42.