

Colonic Carcinoma Presenting with Axillary Lymphadenopathy-A Very Rare Clinical Entity

Dr R. Ramesh Reddy¹, Dr. Pranabandhu Das^{2*}, Dr N Rukmangadha³, Dr B. Manilal⁴, Dr. T. C. Kalawat⁵,
Dr. A. Y. Lakshmi⁶

¹Junior Resident, Department of Radiation Oncology, Sri Venkateswara Institute of Medical Sciences, Tirupati, Andhrapradesh.
²Assistant Professor, Department of Radiation Oncology, Sri Venkateswara Institute of Medical Sciences, Tirupati, Andhra Pradesh, India
³Assistant Professor, Dept. of Pathology, Sri Venkateswara Institute of Medical Sciences, Tirupati, Andhra Pradesh, India
⁴Assistant Professor, Dept of Surgical Oncology, Sri Venkateswara Institute of Medical Sciences, Tirupati, Andhra Pradesh, India
⁵Professor, Dept of Nuclear Medicine, Sri Venkateswara Institute of Medical Sciences, Tirupati, Andhra Pradesh, India
⁶Professor, Dept of Radiodiagnosis, Sri Venkateswara Institute of Medical Sciences. Tirupati, Tirupati, Andhra Pradesh, India

Corresponding Author: Dr. Pranabandhu Das

Abstract: *The most common sites of colon cancer metastasis are regional lymph nodes, liver and lungs. Axillary lymph node metastasis from colon cancer is an extremely rare clinical event being encountered in oncology practice. This scarcity of reports in English literature is therefore poses challenges in understanding its pathogenesis and thus hinders in implementation of appropriate management. We present here a case of right sided colonic carcinoma in a middle aged male patient presented with left sided axillary lymphadenopathy. FNAC showed metastatic adenocarcinomatous deposits. Following ultrasonography of abdomen and later colonoscopy guided biopsy of polypoidal growth at right hepatic flexure of colon was confirmed as signet ring cell carcinoma of colon. Patient underwent palliative hemicolectomy and was offered palliative chemotherapy and was treated later with palliative radiotherapy to the painful left axillary and supraclavicular swelling. He had achieved symptomatic relief from pain and tightness after radiotherapy and advised supportive and symptomatic care at home.*

Keywords: colonic cancer, axillary lymphadenopathy

1. Introduction

Metastasis to locoregional lymphnodes and liver from colon cancer are a common finding in the clinical practice. Other common sites of metastasis are lungs, peritoneum and ovary. Distant sites such as axillary and supraclavicular lymphnodes are extremely rare with only four cases have been reported so far in English literature review⁽¹⁻⁴⁾. Here we report a middle aged man who presented to our institute with enlarged left axillary lymphnodes associated with extensive lymphedema of left arm and chest wall. He was later diagnosed as right sided colon cancer, underwent right extended hemicolectomy, received palliative chemotherapy and palliative radiotherapy and later died of disease progression.

2. Case Report

A 40 year-old-male patient presented with loss of appetite, generalised weakness and frequent loose stools after food intake which was persisting since three months for which he had consulted local hospital and received symptomatic treatment and was referred to our hospital outpatient department for further evaluation and management. He was severely anaemic and received five units of packed cell transfusion before presenting to us. He had complaints of dyspnoea on exertion, dyspepsia and left sided neck and axillary swelling and tightness noticed for last one month duration which was painless and not associated with fever, cough, chest pain or hemoptysis. He was not a known diabetic, hypertensive, tuberculosis, bronchial asthma or angina and no family history of such type of illness. Fine needle aspiration cytology (F NAC) from left axillary swelling was suggestive of metastatic adenocarcinomatous

deposits [Figure-1] and was advised to look for the primary such as GIT, Thyroid, Lungs. Ultrasonography of abdomen showed features suggestive of carcinoma hepatic flexure of colon with metastatic lymphadenopathy. Colonoscopy revealed polypoidal friable growth of about 5x4 cm lying 10 cm distal to caecum possibly in ascending colon. Colonoscopy guided biopsy revealed moderately differentiated adenocarcinoma of colon. Final diagnosis of adenocarcinoma colon with secondaries in neck and axilla which is cT3N1M1 (stage IV) was made. Patient underwent right extended hemicolectomy with ileo-transverse bypass surgery. Histopathology revealed adenocarcinoma of signet ring cell type [Figure-2] which showed alcian blue positivity for mucin [Figure-3] with tumor free proximal, distal margins, omentum and retroperitoneum. Later he received 12 cycles of palliative chemotherapy of FOLFOX. The axillary swelling was clinically found to progress in size and became tender and painful and patient was referred for palliative RT for symptomatic pain relief. Post chemotherapy follow up ultrasonography of abdomen showed normal study of abdomen. ¹⁸F FDG PET-CT [18 fluoro deoxy glucose positron emission tomography] scan of whole body revealed no metabolically active disease in primary operated site. Low grade metabolically active left axillary lymphadenopathy and non FDG avid left cervical lymphadenopathy was noted. Non FDG avid right femur and right iliac bone lesion was noted. metabolically active [soft tissue density lesion in lower chest was noted posteriorly suggestive of metastasis [Figure-4]. Patient was taken up for palliative radiation to left axillary swelling and left side neck and supraclavicular region to a dose of 39Gy in 13 fractions, 3Gy per fraction, 5 fractions per week. Patient had achieved symptomatic relief from pain and tightness following RT, with clinically significant regression of size of axillary and

Volume 6 Issue 8, August 2017

www.ijsr.net

Licensed Under Creative Commons Attribution CC BY

neck swelling. Patient was advised to be on best supportive and symptomatic care management after being discharged. Patient died two months after discharge at home which may be due to disease progression.

3. Discussion

A predictable locoregional metastatic spread exists in patients with carcinoma colon. Initially spreads to locoregional lymphnodes. But there is no obvious literature stating the mechanism or process of the metastatic spread of tumor cells to distant non regional lymphnodes in patients with colorectal cancer. As with other types of malignancies, extracapsular lymphnodal spread is related to distant spread and worse prognosis⁽⁵⁾. Extracapsular invasion in pathologically positive lymph nodes is significantly related to nodal spread of tumor cells in colorectal cancer patients and may partially explain the mechanism of dissemination to distant regional lymph nodes like axillary and cervical lymph nodes. Usual pattern of lymph node spread follows vascular distribution of the mesocolon. Colonic tumors spread through lymphatic channels along ileocolic, right colic, middle colic arteries. All these drain into lymph nodes accompanying superior mesenteric artery. Descending colon tumors spread to lymphatics along left colic artery, while tumors of sigmoid colon drain into the nodes accompanying sigmoid artery. Mesenteric nodes drain into preaortic lymph nodes. All colorectal malignancies drain into cisterna chyli that drains into thoracic duct. Statistically most common sites of colorectal tumor spread are local lymph nodes (50%-70%) and liver (35%-50%). Other common sites of are spread are lung (21%), peritoneum (15%) and ovaries (13.1%). Rare distant metastatic sites of colonic carcinoma are central nervous system (8.3%), bone (8.7%), kidney (6.6%), testes, penis, uterus and oral cavity. Very rare metastatic sites like adrenal glands (4.3%), hilar lymph nodes, skin and muscles have been described and occasional cases of metastasis to pancreas, maxillary sinus, thyroid and knee (synovial) have been reported⁽⁶⁾. From the extensive literature, it was evident that apart from locoregional and visceral metastasis, distant metastasis were a possibility. Distant metastasis to non regional lymph nodes like axilla and supraclavicular regions are very rare with four cases of axillary lymph nodes have been reported so far. Outcome was poor and prognosis was worse as in this case. This patient having a signet ring cell variant of adenocarcinoma adds to its further poor prognosis. This case has been presented because of its extreme rare incidence, poor clinical outcome which warrants its early detection through clinico-radiological, endoscopic or through functional imaging that may contribute towards better quality of life and overall survival.

Multi-modality of treatment approach with surgery followed by adjuvant chemotherapy is the standard of care in carcinoma colon. But this approach changes in metastatic set up^(7,8). The aim of therapy in metastatic setting is to improve the quality of life and symptomatic relief. Collaborative information regarding such clinical entities can guide the oncology team for effective management of such rare cases in future.

In conclusion we would say that because of the dismal prognosis of such a rare clinical entity, it would always be wise to undertake a screening of these vulnerable patients for suspected colonic neoplasm in order to prevent it from progressing to an event of poor clinical outcome.

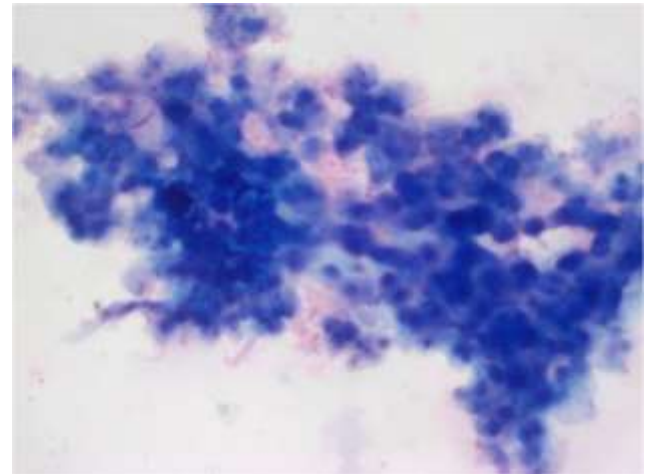


Figure 1: H&Ex20 showing hypercellular smears showing cuboidal cells with pleomorphic vesicular nuclei, arranged in the form of sheets, acinar formation and eosinophilic to vacuolated cytoplasm.

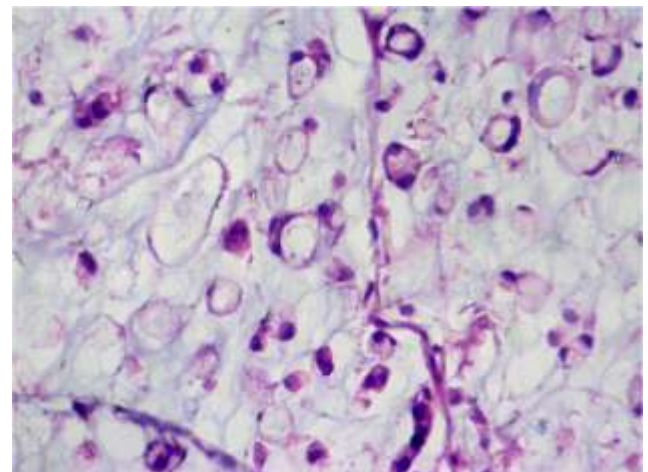


Figure 2: H&Ex40 showing tumor cells with signet ring cell carcinomatous morphology.

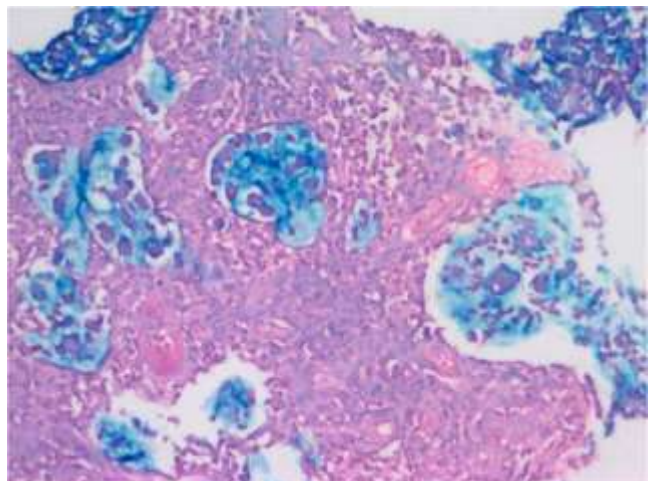


Figure 3: Alcian blue stain showing positivity in tumor cells with mucin suggestive of signet ring cell adenocarcinoma

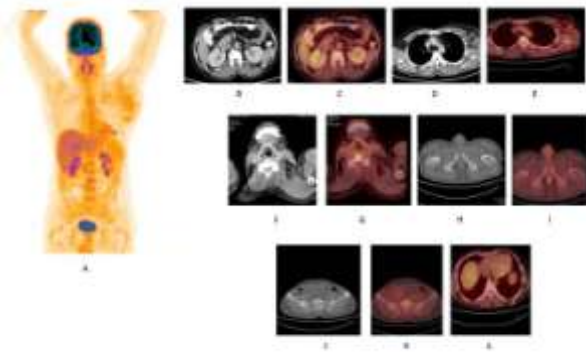


Figure 4: [A]. Maximum intensity projection image showing physiological FDG biodistribution. [B,C]: CT and fused PET/CT images showing no morphological and metabolic abnormality at the treated site in colon. CT and fused PET CT showing Left level III cervical lymph nodes showing no increased FDG concentration. [D,E]: CT and fused PET/CT images showing enlarged Left axillary lymph nodes with increased FDG concentration. [F,G]: Non-FDG avid Lt cervical lymph nodes . [H,I]: CT and fused PET/CT images showing Non-FDG avid sclerotic focus in Rt. femur neck.[J,K]: CT and Fused PET/CT images showing lytic lesion in Rt. Ilium. [L]: fused PET/CT image showing small soft tissue density lesion in the sub cutaneous plane in Left lower chest wall posteriorly with increased FDG concentration.

References

- [1] Gubitosi A, Moccia G, Malinconico FA, et al. Unusual metastasis of left colon cancer: considerations on two cases. *Acta biomed.* 2009;80:80-2.
- [2] Chieco PA, Virgilio E, Mercantini P, et al. Solitary left axillary metastasis after curative surgery for right colon cancer. *J Surg.* 2011;81:846-7
- [3] Perin T, Canzonieri V, Memeo L, et al. Breast metastasis of primary colon cancer with micrometastasis in the axillary sentinel node: a metastasis that metastasized? *Diagn Pathol.* 2011;6:45.
- [4] Suzuli T. Metastasis of Colon Cancer to Axillary Lymph Nodes. *Jikeikai Medical Journal* 2006;53:167-70
- [5] Fujii T, Tabe Y, Yajima R, et al. Process of Distant Lymph Node Metastasis in Colorectal Carcinoma: Implication of Extracapsular Invasion of Lymph Node Metastasis. *BMC Cancer.* 2011;11:216.
- [6] Hess KR, Varadhachary GR, Taylor SH, et al. Metastatic Patterns in Adenocarcinoma. *Cancer.* 2006;106:1624-33.
- [7] Kikuchi I, Nishimura Y, Nishida K, et al. A case report of surgical treatment for axillary lymph node metastasis from descending colon cancer. *GanTo Kagaku Ryoho.* 2012;39:2252-4.
- [8] Gastrointestinal Tumor Study Group. Adjuvant therapy of colon cancer-results of a prospectively randomized trial. *N Engl J Med.* 1984;310:737-43.