

# Assessment of Echocardiographic Imaging in Diagnosis of Heart Failure

Nisreen Haj<sup>1</sup>, Mohamed Yousef<sup>2</sup>, Elsafi Ahmed<sup>3</sup>, Ikhlas Abdelaziz<sup>3,4</sup>

<sup>1</sup>Al-Ghad International College for Applied Medical Science, Medical Imaging Technology Department, Tabuk, KSA

<sup>2</sup>Batterjee Medical College, Department of Radiological Science, Jeddah, Saudi Arabia

<sup>3</sup>Sudan University for Sciences and Technology, College of Radiological Sciences, Khartoum, Sudan

<sup>4</sup>National Ribat University College of Radiological Sciences and Nuclear Medicine

**Abstract:** *The objective of the study was to assess echocardiographic imaging in diagnosis of heart failure. 180 patients (62 female and 118 male) with heart failure sign were enrolled. Their ages ranged between (20 – 85) years. The study was conducted at two hospitals in period from November 2014 to September 2017. The results of the study showed that, 118 cases (65.6%) were male and 62 cases (34.4%) were female. The incidence of the heart failure was high among the age group mean 60.56 that mean the risk of heart failure increase with age. In view of the importance of Ejection fraction by using 2D echo, the results showed that mean EF 38.94 (minimum 15 – maximum 60). The left ventricular ejection fraction volume represents that the maximum was 60% and this was normal value unless the patient had right side failure or diastolic dysfunction which is called heart failure with preserved left ventricular ejection fraction (PLVEF). The hypertension was predominant cause of heart failure in Sudan (36.1%). The common finding of the study was left ventricular systolic dysfunction LVSD which represents about 121 patients 67.7%. The study concluded that the correlation is significant at the 0.01 level. between the left ventricular internal diastolic diameter LVIDD left ventricular internal systolic diameter LVISD and ejection fraction EF equal -.376 (negative)*

**Keywords:** Heart failure, Echocardiographic, Ejection fraction

## 1. Introduction

Heart failure is a syndrome with symptoms and signs caused by cardiac dysfunction. (Hogg et al 2004). In the 1995 World Health Organization definition of heart failure states that “cardiac failure is an inability of the heart to deliver blood (and therefore oxygen) at a rate commensurate with the requirements of the metabolizing tissues at rest or during light exercise. This leads to characteristic systemic pathophysiological responses (neural, hormonal, renal and others), symptoms and signs. (Strobeck J.E et al 1985) Although many conditions can cause heart failure (coronary artery disease, hypertension, cardiomyopathies, valvar and congenital heart disease, arrhythmias, pericardial disease, myocarditis, pulmonary hypertension, and cardio toxic substances—including alcohol), the predominant cause of heart failure in the western world is ischemic heart disease. Fox K F, Cowie M R, Wood D A. *et al*-2001. Echocardiography uses high-frequency ultrasound to evaluate the heart and great vessels. The examination provides a dynamic rendition of cardiac great vessel anatomy and, when combined with the Doppler technique, yields information regarding cardiac and great vessel blood flow (hemodynamics) as well. Because of the high frame rates inherent in ultrasonography, echocardiography can image the heart in a dynamic real-time fashion, so that the motion of cardiac structures can be reliably evaluated. Echocardiography is useful in assessing ventricular function, valvar heart disease, myocardial disease, pericardial disease, intracardiac masses, and aortic abnormalities. With Doppler technology, cardiac chamber function, valvar function, and intracardiac shunts frequently seen in congenital heart disease can be assessed. Combined Doppler echocardiography is a commonly performed procedure

because it is relatively inexpensive and widely available, provides a wealth of information, is noninvasive, has no risk of ionizing radiation, and can also be performed at the bedside in critically ill patients. Furthermore, the results are immediately available because no special post examination image processing is required. However, this technique is technically challenging and requires a great deal of operator expertise. Also, a small percentage of patients have poor acoustic windows that can severely degrade image quality. This disadvantage can be obviated by placing the sonographic probe in the esophagus, a procedure called trans esophageal echocardiography (TEE). Trans esophageal echocardiography yields consistently excellent images of the heart and great vessels, but involves a small amount of discomfort and risk to the patient. More recently, echocardiography has been combined with stress-testing modalities to assess inducible myocardial ischemia using wall motion analysis of left ventricular function (Soongswang J-2000)

## 2. Materials And Methods

This was a descriptive quantitative an observational cross-sectional study of 180 Sudanese patients admitting to all flowing hospitals for Echocardiogram scan, 26(40%) female and male 118(60%) their ages ranged between [20-85] years Their mean age was 60.56 years.

The study was conducted at Khartoum state in Echocardiography department of Omdurman military hospital and Sudan heart center in the period from November 2014 until July 2017. Inclusion criteria: Any patient with heart failure sign. Exclusion criteria of the study cases: Patients with age low than 20 years. Study variables

include (Age, Sex, Clinical history, echocardiogram findings Data was collected using data collection sheet and analyzed using SPSS (Statistical package for Social Sciences). Two-dimensionally and M-mode, echocardiograms were recorded using ultrasound machine HDI 4000 scanner (Philips Medical Systems) equipped with a commercially available 8-13MHz linear transducer with color and power Doppler capability and GE medical system LOQIC5Expert, made by Yocogama medical systems. LTD –JAPAN – model 2302650, serial number 1028924, manufactured April 2005.

### Echocardiogram Techniques

TTE by using the long axis view is obtained by placing the ultrasound transducer in the left apicosternal position and provides detailed images of the left ventricle, aorta, left atrium and mitral and aortic valves. Angling the beam towards the right also allows assessment of the right atrium, right ventricle and tricuspid valves. Rotating the transducer by 90 degrees in the clockwise direction produces the short axis view, which allows assessment of the left ventricle,

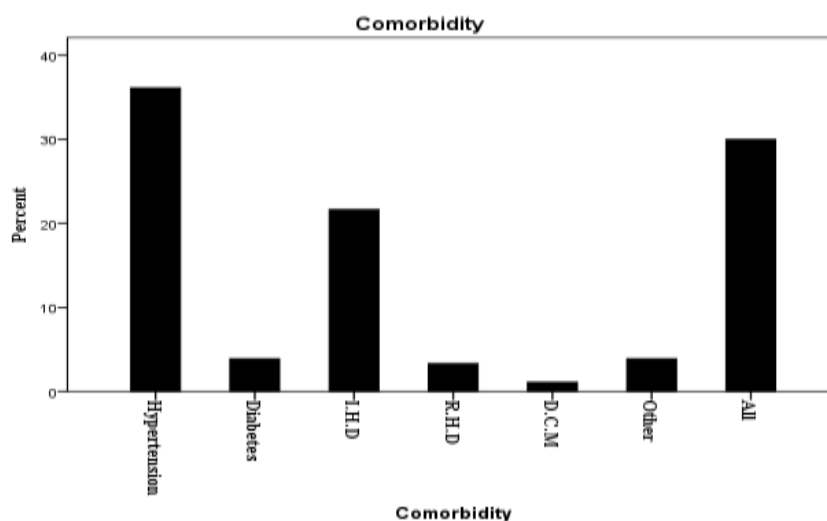
papillary muscle, chodaetendineae and mitral valves. The four-chambers view demonstrates the ventricles, atria and mitral and tricuspid valves. Rotation of the transducer allows two- chambers views of the heart and more detailed assessment of the aorta and aortic valves demonstrated.

The EF and volumes were measured with 2D-biplane Simpson's method, 2D-triplane and 3- dimensional echocardiography (3DE) by two investigators blinded to any clinical data. By using the protocols of echo which was established by British Society of echocardiography Education Committee which state that for viewing the HF along –axis view is used applying of this view was obtained by put the echo transducer (probe) in the left apicosternal position and provides detailed images of many parts of heart specially the left ventricle, aorta, left atrium and mitral and aortic valves.

### 3. Result Presentation

**Table 1:** Mean values of the measured parameters in the whole sample Descriptive Statistics

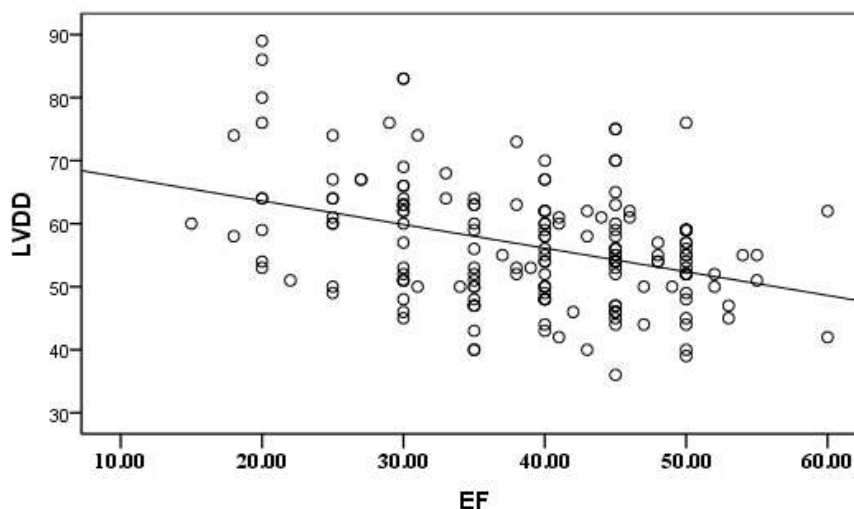
	N	Minimum	Maximum	Mean	Std. Deviation
Age	180	20	85	60.56	13.169
Weight	180	50	107	80.14	10.666
EF	180	15.00	60.00	38.9444	9.55766
LVDD	180	36	89	56.52	9.538
LVSD	180	23	80	42.68	10.410



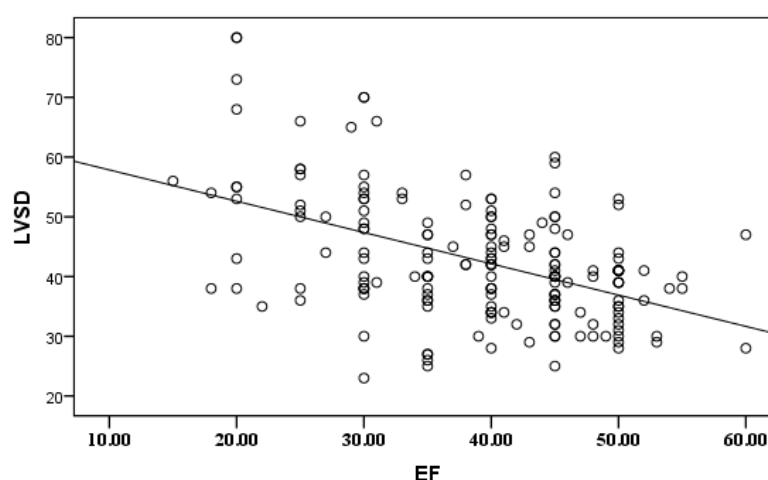
**Table 2:** Correlation between EF, LVDD and LVSD

		EF	LVDD	LVSD
EF	Pearson Correlation	1	-.376**	-.481**
	Sig. (2-tailed)		.000	.000
	N	180	180	180
LVDD	Pearson Correlation	-.376**	1	.910**
	Sig. (2-tailed)	.000		.000
	N	180	180	180
LVSD	Pearson Correlation	-.481**	.910**	1
	Sig. (2-tailed)	.000	.000	
	N	180	180	180

\*\* . Correlation is significant at the 0.01 level (2-tailed).



**Figure 2:** A scatter plot diagram shows the correlations between LVDD and EF in heart failure patients. As the LVDD increases the EF decreases



**Figure 3:** A scatter plot diagram shows the correlations between LVSD and EF in heart failure patients. As the LVSD increases the EF decreases

#### 4. Discussion

The study is conducted on 180 patients with heart failure condition investigated by using echocardiogram, 118 cases (65.6%) were male and 62 cases (34.4%) were female, this agrees with study done by Levy W C, Mozaffarian D, Linker D T. et al Heart failure occurs more frequently in men than in women. The incidence of the heart failure was high among the age group mean 60.56 that mean the risk of heart failure increase with age which was same result with comparable to previous studies, such as the Rotterdam study (prevalence of heart failure being 1% in age group 55–64 years, 3% in age group 65–74 years, 7% in age group 75–84 years, and over 10% in those aged  $\geq 85$  years). (Owan T E, Hodge D O, Herges R M. et al-2006). The hypertension is predominant cause of heart failure in Sudan Although many conditions can cause heart failure (coronary artery disease, hypertension, cardiomyopathies, valvular and congenital heart disease, arrhythmias, pericardial disease, myocarditis, pulmonary hypertension, and cardiotoxic substances—including alcohol), the predominant cause of heart failure in the western world is ischaemic heart disease. Fox K F, Cowie M R, Wood D A. et al-2001

Changes in LV measurements and geometry due to hypertension reflect the dominant underlying hemodynamic alterations associated with blood pressure elevation, Ganau (1992), Matsukubo (1977).

The changes detected by echocardiography showed increase in left ventricular mass which is a consistent feature of hypertension. The justification of those changes is described as structural changes, Berkinst (2001). Heart failure cause changes as cardiac cell hypertrophy but the cardiac myocyte cell number does not increase. In addition hypertension causes considerable interstitial change and fibroblast proliferation Berkinst (2001). The Framingham study showed the hazard for developing heart failure in hypertensive, thus documenting the importance of assessing left ventricular function in hypertensive heart disease. The conventional way of assessing left ventricular function with echocardiography is via the left ventricular ejection fraction, determined by applying Simpson's method of discs Shahgaldi (2009). Figures (3,4) showed the linear Correlation between LVSD, and LVDD with EF, it showed that as the LV measurements increases the EF decreases.

Similarly, Blendea *et al.* (2007) reported that the alterations in left ventricular long-axis systolic and diastolic function could predict the onset of heart failure. Despite the widespread clinical use of the left ventricular ejection fraction, it should be kept in mind that it is a load-dependent systolic index. From this point of view, it is clearly very important to identify the slightest initial impairment of left ventricular function, using additional indices apart from ejection fraction that are not load-dependent.

## 5. Conclusion

This study attempts to describe the echocardiographic features of Left ventricular among heart failure Sudanese patients. Echocardiography itself could be used for heart disease screening in clinical patients. Echocardiography is a significant tool for the evaluation of heart failure patients.

Assessing a heart failure patient echocardiographically does not simply represent adherence to a routine examination procedure that has limited clinical value.

## References

- [1] Arthur Cgyton, M. D. Text book of medical physiology, Eleventh edition (igaku-shon/saunders), 2006, p 150-163
- [2] Carol M. Rumack, Stephanie R. Wilson, J. William Charboneau, and Deborah Levine, Diagnostic ultrasound (2007) 4th edition published by Elsevier
- [3] Berkinst, K. E. and Ball, S. G. 2001. Hypertension essential Hypertension: The Heart And Hypertension *Heart*; 86:467-475
- [4] Blendea, D., Duncea, C., Bedreaga, M., Crisan, S. and Zarich, S. 2007. Abnormalities of left ventricular long-axis function predict the onset of hypertension independent of blood pressure: a 7-year prospective study. *J Hum Hypertens.*; 21: 539- 545
- [5] Doppler Echocardiography at the US National Library of Medicine Medical Subject Headings (MeSH)
- [6] Feigenbaum, H. 1981. *Echocardiography* 3rd edn. Lea & Febiger, Philadelphia
- [7] Fox K F, Cowie M R, Wood D A. *et al* Coronary artery disease as the cause of incident heart failure in the population. *Eur Heart J* 2001;22:228-236. [PubMed] Study documenting the importance of vigorously evaluating patients with heart failure to establish the cause of heart failure.
- [8] Ganau, A., Devereux, R.B, Roman, M.J, de Simone, G., Pickering, T.G, Saba, P.S, *et al.* 1992. Patterns of left ventricular hypertrophy and geometric remodeling in essential hypertension. *J Am Coll Cardiol*; 19:1550e8.
- [9] Hogg K, Swedberg K, McMurray J. Heart failure with preserved left ventricular systolic function; epidemiology, clinical characteristics, and prognosis. *J Am Coll Cardiol* 2004;43:317-327. [PubMed] Excellent review of the epidemiology of heart failure with preserved left ventricular systolic function ("diastolic heart failure").
- [10] Levy W C, Mozaffarian D, Linker D T. *et al* The Seattle Heart Failure Model: prediction of survival in heart failure. *Circulation* 2006;113:1424-1433.
- [11] Matsukubo, H., Matsuura, T., Endo, N., Asayama, J. and Watanabe, T. 1977, Echocardiographic measurement of right ventricular wall thickness. A new application of subxiphoid echocardiography. *Circulation*; 56:278e84.
- [12] Owan T E, Hodge D O, Herges R M. *et al* Trends in prevalence and outcome of heart failure with preserved ejection fraction. *N Engl J Med* 2006;355:251-259. [PubMed] First paper to address trends in prevalence and outcomes for heart failure patients with preserved as well as impaired left ventricular systolic function
- [13] Shahgaldi, K., Gudmundsson, P., Manouras, A., Brodin, L.A. and Winter, R. 2009. Visually estimated ejection fraction by two dimensional and triplane echocardiography is closely correlated with quantitative ejection fraction by real-time three dimensional echocardiography. *Cardiovascular Ultrasound.*; 7: 41
- [14] Soongswang J, Nana A, Laohaprasitiporn D, Durongpisitkul K, Kangkagate C, Rochanasiri W, and Kovitcharoentrakul T. Limitation of transthoracic echocardiography in the diagnosis of congenital heart diseases. *J Med Assoc Thai* 2000; 83:111-117.