

Revascularization of Necrotic Immature Permanent Anterior Tooth (Case Report)

Rabab Kubba¹, Zainab Al-Dahan²

¹BDs, Department of Pedodontics and Preventive Dentistry, College of Dentistry, University of Baghdad

²Professor, Department of Pedodontics and Preventive Dentistry, College of Dentistry, University of Baghdad

Abstract: ***Introduction:** Endodontic regenerative procedures are valuable treatment in immature necrotic teeth that permits continuation of root maturation and apical closure. **Methods:** 9 years-old girl with traumatized upper right central incisor. The clinical and radiographical examinations revealed uncomplicated crown fracture, tenderness, absence of response to cold vitality test and periapical radiolucency with immature root. Revascularization was suggested to treat the tooth, start with irrigation of canal with 5% NaOCl + 3% H₂O₂, followed by 2 weeks of triple antibiotic (metronidazole, ciprofloxacin and minocycline) paste. Then antibiotic paste was removed, bleeding was induced and calcium enriched mixture cement (CEM) was applied over the blood clot. **Results:** In clinical and radiographical examinations in follow up visits the tooth was asymptomatic and functional, periapical radiolucency was healed, and root continued to develop with apical foramen became narrower. **Conclusion:** Revascularization is an effective treatment for immature necrotic teeth. In addition, CEM provides favorable outcomes in revascularization treatment.*

Keywords: Revascularization, immature tooth, open apex, pulp necrotic, CEM cement

1. Introduction

Root maturation and apical closure in permanent teeth need up to 3 years after tooth eruption to be completed [1]. If pulp injury occurs during these years, the clinician will have a challenging case to manage. Selection of either apexogenesis or apexification in management of immature teeth in the past appeared to be definite; teeth with vital pulp tissue can receive apexogenesis, while teeth with necrotic pulp are chosen for apexification [2].

Traditionally, multiple visits apexification with Calcium hydroxide was the treatment of choice for immature necrotic teeth [1], which stimulate hard tissue barrier formation [3]. After that, one-step apexification by artificial apical plug using materials like MTA appeared, and gave the advantage of decreasing the number of visits and time of treatment [4], but both techniques have the disadvantages of permitting the continuation of the root development ending in week root structure [5].

Later on, endodontic regenerative procedures emerged as an alternative modality of treatment that besides healing apical periodontitis, added a goal of promoting normal pulp physiological functions, including root development, immune function and normal sensation [6].

These procedures are based on providing an environment suitable for root maturation through disinfection of root canal and use of antibiotic mixture as an intracanal medicament. In the absence of signs and symptoms in the second appointment, the procedure is continued by washing the paste out and evocation of intracanal bleeding by irritating periapical area [7]. After stable clot formation, the clot is covered with MTA or one of its alternatives [8].

CEM is a water-based cement with the same clinical applications as MTA but they differ in chemical composition [9,10]. CEM biocompatibility and sealing ability are comparable to that of MTA [11-14]. CEM promote

hydroxyapatite formation and may encourage the process of differentiation in stem cells and hard tissue formation [10,15].

2. Case Report

8 years-old girl suffered trauma to tooth #11 several weeks before seeking treatment with a history of pain. On examination, there was uncomplicated crown fracture, tenderness to percussion, and mobility within normal limits, absence of sinus tract and absence of response to cold vitality test. Diagnostic periapical radiograph revealed immature root with a radiolucent periapical lesion. The diagnosis of necrotic pulp with symptomatic apical periodontitis was made. Informed consent was obtained, local anesthesia 2% Lidocaine with 1:80,000 epinephrine was given, rubber dam isolation was performed then access opening was done and working length was determined by inserting a large K-file and taking periapical radiograph. Then the canal was irrigated with 5% NaOCl + 3% H₂O₂ using closed end endodontic needle, keeping its tip 2mm shorter than the apex. The canal was dried with large sterile paper point. Then the pulp chamber walls were sealed with a dentine bonding agent to minimize discoloration caused by minocycline. A freshly prepared triple antibiotic paste [400mg metronidazole (Julphar - U.A.E.), 250mg ciprofloxacin (Acino-Switzerland) and 50 mg Minocyclin (Alfares pharmaceuticals-Syria) mixed with distilled water] was applied into the canal with lentulo spiral, keeping the paste 2mm shorter than apex. Cavity was sealed with glass ionomer filling material and the patient was given an appointment 2 weeks later.

On the second visit, the tooth was without signs and symptoms, 3% Mepivacaine anesthetic solution without vasoconstrictor was injected, rubber dam was applied temporary filling was removed by copious amount of 5% NaOCl + 3% H₂O₂. Then the canal was dried and intracanal bleeding was induced using a sterile #50 K-file which was inserted 2 mm beyond the apical end of the canal. Bleeding

Volume 6 Issue 7, July 2017

www.ijsr.net

Licensed Under Creative Commons Attribution CC BY

was controlled with a cotton pellet 3mm apical to the canal orifice. 15 minutes later, the clot was stable on gentle touch with a cotton pellet Calcium enriched mixture cement (CEM) was applied over the blood clot and the access cavity was filled with Glass Ionomer filling material to give double seal.

The patient was recalled after 1,3and 7 months. There were no signs or symptoms in all followup visits. Apical growth and narrowing of apical foramen was noticed in the 7 months follow up visit.

3. Conclusion and Discussion

Revascularization is a promising procedure that involves hard tissue deposition giving stronger teeth that are more able to tolerate forces without fracture.

The infected root canal seems to contain variety of aerobic and anaerobic bacteria, making the use of any single antibiotic unlikely to give effective sterilization. A paste consists of metronidazole, ciproflaxacin and minocycline has been reported to be effective in sterilizing root canals [16]. After disinfection, a resorbable matrix should fill the canal to promote new tissue growth. Then the canal orifice should be sealed to inhibit reinfection.

Coronal seal is essential factor for successful revascularization [17]. Most reported cases mentioned the use of double seal over the blood clot [17, 19 ,20]. MTA has been used successfully for this purpose, but its difficult manipulation and long setting time restrict it use by specialists [18].

One of MTA alternatives is CEM which has many favorable properties, including biocompatibility when used in vital pulp therapy [21-23], and its biocompatibility, sealing ability and cementogenic properties are the same as MTA [24]. Also it has antibacterial effect [25].

In this study clinical and radiographical outcomes are favorable suggesting that CEM is an appropriate sealing material over blood clot in revascularization procedure.

4. Future Scope

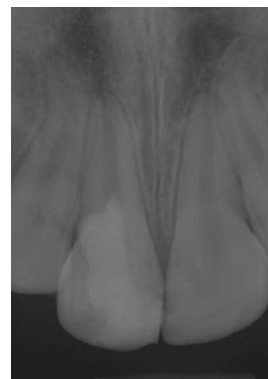
- 1) Longer follow up period is recommended.
- 2) Randomized clinical trials are recommended to compare results of revascularization with apexification.

References

- [1] Rafter M. Apexification: a review. *Dent Traumatol* 2005; 21: 1–8.
- [2] Iwaya SI, Ikawa M, Kubota M. Revascularization of an immature permanent tooth with apical periodontitis and sinus tract *Dent Traumatol*. 2001;17(4):185-7. doi: 10.1034/j.1600- 9657.2001.017004185.x
- [3] American Association of Endodontists. Glossary of endodontic terms, 7th edn. Chicago: American Association of Endodontists; 2003.
- [4] Torabinejad M, Chivian N. Clinical application of mineral trioxide aggregate. *J Endod*. 1999 Mar;25(3):197-205.
- [5] Nosrat A, Homayounfar N, Oloomi K. (2012). Drawbacks and unfavorable outcomes of regenerative endodontic treatments of necrotic immature teeth: a literature review and report of a case. *Journal of endodontics*, 38(10), 1428-1434.
- [6] Diogenes A, Henry MA, Teixeira FB, Hargreaves KM: An update on clinical regenerative endodontics, *Endod Topics* 28:2, 2013.
- [7] Khoshkhounejad M, Shokouhinejad N, Pirmoazen S. (2015). Regenerative endodontic treatment: report of two cases with different clinical management and outcomes. *Journal of dentistry*, 12(6), 460.
- [8] AAE clinical considerations for a regenerative procedure. Revised 6-8-16. Available at: https://www.aae.org/uploadedfiles/publications_and_research/research/currentregenerativeendodonticconsiderations.pdf. Accessed June 4, 2017.
- [9] Asgary S, Shahabi S, Jafarzadeh T, Amini S, Kheirieh S. The properties of a new endodontic material. *J Endod* 2008;34:990–3.
- [10] Asgary S, Eghbal M, Parirokh M, Ghoddusi J, Kheirieh S, Brink F. Comparison of mineral trioxide aggregate's composition with Portland cements and a new endodontic cement. *J Endod* 2009;35:243–50.
- [11] Mozayeni M, Milani A, Marvasti L, Asgary S. Cytotoxicity of calcium enriched mixture cement compared with mineral trioxide aggregate and intermediate restorative material. *AustEndod J* Epub 2010 Oct 24.
- [12] Asgary S, Eghbal M, Parirokh M. Sealing ability of a novel endodontic cement as a root-end filling material. *J Biomed Mater Res* 2008;87A:706–9.
- [13] Asgary S, Eghbal M, Ehsani S. Periradicular regeneration after endodontic surgery with calcium-enriched mixture cement in dogs. *J Endod* 2010;36:837–41.
- [14] Asgary S, Eghbal M, Parirokh M, Ghanavati F, Rahimi H. A comparative study of histologic response to different pulp capping materials and a novel endodontic cement. *Oral Surg Oral Med Oral Pathol Oral Radiol Endod* 2008;106:609–14.
- [15] Asgary S, Eghbal M, Parirokh M, Ghoddusi J. Effect of two storage solutions on surface topography of two root-end fillings. *AustEndod J* 2009;35:147–52.
- [16] Hoshino E, Kurihara-Ando N, Sato I, Uematsu H, Sato M, Kota K, Iwaku M (1996). In-vitro antibacterial susceptibility of bacteria taken from infected root dentine to a mixture of ciprofloxacin, metronidazole and minocycline. *International endodontic journal*, 29(2), 125-130.
- [17] Banchs, F., & Trope, M. (2004). Revascularization of immature permanent teeth with apical periodontitis: new treatment protocol?. *Journal of endodontics*, 30(4), 196-200.
- [18] Parirokh M, Torabinejad M (2010). Mineral trioxide aggregate: a comprehensive literature review—part III: clinical applications, drawbacks, and mechanism of action. *J endod*, 36(3), 400-413.
- [19] Thibodeau B, Trope M. Pulp revascularization of a necrotic infected immature permanent tooth: case report

and review of the literature. *Pediatr Dent.* 2007;29:47–50.

- [20] Petrino J, Boda, K, Shambarger S., Bowles W, McClanahan S. Challenges in regenerative endodontics: a case series. *J Endod.* 2010;36:536–541.
- [21] Asgary, S., Eghbal, M. A clinical trial of pulpotomyvs root canal therapy of mature molars. *J Dent Res.* 2010;89:1080–1085.
- [22] Nosrat, A., Asgary, S. Apexogenesis treatment with a new endodontic cement: a case report. *J Endod.* 2010;36:912–914.
- [23] Nosrat, A., Asgary, S. Apexogenesis of a symptomatic permanent molar with calcium enriched mixture. *IntEndod J.* 2010;43:940–944.
- [24] Samiee, M., Eghbal, M., Parirokh, M., Abbas, F., Asgary, S. Repair of furcal perforation using a new endodontic cement. *Clin Oral Investig.* 2010;14:653–658 (Epub 2009 Nov 4).
- [25] Asgary, S., Kamrani, F.A. Antibacterial effects of five different root canal sealing materials. *J Oral Sci.* 2008;50:469–474.

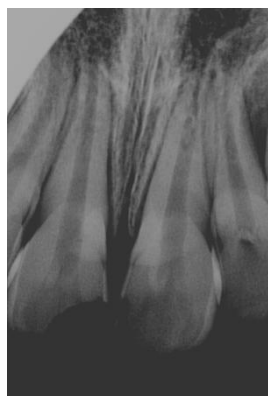

After 7month

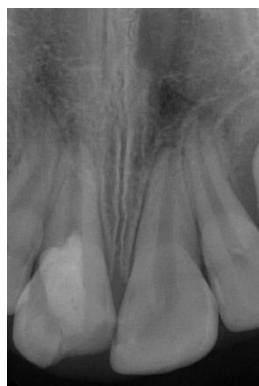Author Profile

Rabab Kubba, MSc, Department of Pedodontics and Preventive Dentistry, College of Dentistry, University of Baghdad.

Zainab Al-Dahan is Professor, Department of Pedodontics and Preventive Dentistry, College of Dentistry, University of Baghdad.



Preopertive X-ray



After 3 months