

A Rare Presentation of Squamous Cell Carcinoma of Maxillary Sinus Involving Orbit - A Case Report

Dr. Ashutosh Patel¹, Dr. Gayathri Mahadevan²

Abstract: Tumors of the paranasal sinuses are rare. Most patients present with an advanced stage of the disease because initial symptoms are often ignored or thought to be due to other less serious conditions that may affect the head and neck region. In the nasal and paranasal sinus regions, squamous cell carcinoma is one of the most common tumor. A rare case of squamous cell carcinoma of maxillary sinus involving orbit is discussed. Patient had undergone complete ophthalmic & endonasal examination. Relevant blood investigation, Neuroimaging (CT plain & contrast) were performed. A Wedge biopsy of mass tissue was sent for histopathological examination & to plan for further management.

Keywords: Neuroimaging (Computed tomography), histopathology, Nasal & paranasal sinus tumor, wedge biopsy

1. Introduction

In the nasal and paranasal sinus regions, squamous cell carcinoma is the most common tumor, followed by adenocarcinoma, malignant lymphoma, sinonasal undifferentiated carcinoma, malignant melanoma, and olfactory neuroblastoma. Malignant tumours of sinonasal tract usually present as advanced disease because early diagnosis difficult. Radical surgical excision remains the mainstay of the treatment. The classic surgical treatment for sinonasal tumours in close proximity to the orbit involved radical excision with orbital clearance or exenteration. After the introduction of orbital preservation surgery, the indications and need for removal of orbital structures have diminished.

2. Objective

To highlight a rare case of squamous cell carcinoma of maxillary sinus involving orbit.

3. Materials & Methods

Case report

A 52 year male patient presented to ENT department complaining of right nasal obstruction which progressed over last 2-3 months & was associated with numbness & pain over right half of face. The patient had experienced intermittent mild epistaxis for 2 weeks prior to presentation. During this period patient was using decongestant nasal drops to relieve obstruction. He is old case of right sided nasal polyposis & had twice undergone polypectomy in past.

No h/o postnasal drip/decreased hearing/visual problem/headache.

No significant medical history or any associated comorbid conditions.

Endoscopic examination revealed a fleshy mass filling the right side nasal cavity, but there was no cheek fullness. An ear examination revealed a dull tympanic membrane in right ear.

Computed tomography of paranasal sinuses showed that the right frontal, sphenoid, ethmoid, & maxillary sinuses were opacified with soft tissue density & expansion of mass, with erosion of right lateral maxillary wall.

Ocular examination-

On examination, his visual acuity of RE was 6/9, no improvement with pin hole, LE was 6/6

Ocular motility – normal ocular movement of BE.

Adnexa- showed edema of right upper lid, diffuse type and non-tender on palpation. proptosis 18mm was recorded on Herthels on right side.

Conjunctiva was normal.

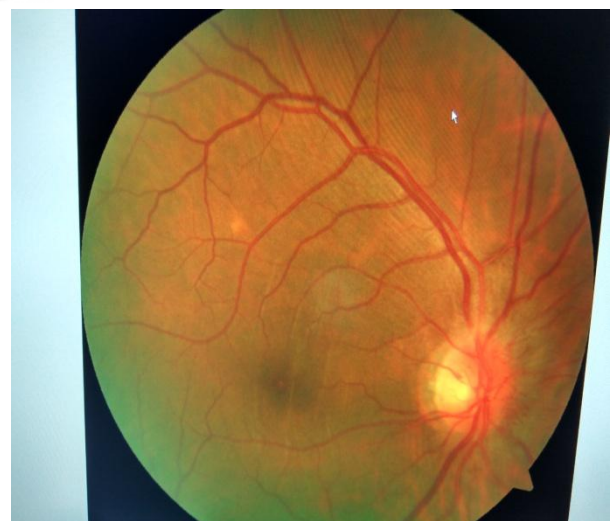Cornea, was clear

AC was normal in depth and contents.

Pupils were brisk and reactive.

Lens revealed grade 1-2 nuclear sclerosis

Fundus – RE



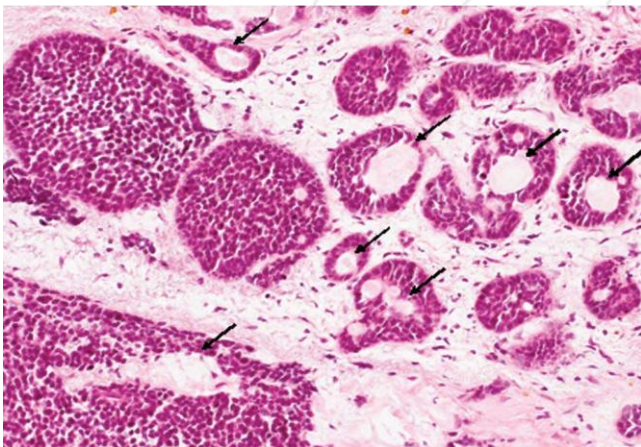
RE proptosis examination-
Inspection- RE eccentric proptosis with diffuse upper lid edema, no visible pulsations.
Palpation- non tender edema of upper lid, proptosis non compressible, non reducible.

Lab Studies CBC shows anemia, low lymphocytes and slightly high neutrophil count Plasma shows low sodium levels

Neuro-images: CT with & without contrast - Large mass in the right facial region involving the right nasal cavity, right orbit and extending intracranially on the right. The mass is also present extracranially and in the right para-orbital region.

Additional neuro-images: MRI of Paranasal sinuses - Heterogeneously enhancing lesion with central necrosis or fluid, extending from the right nasal cavity through the ethmoid cells, right maxillary sinus, right frontal sinus, and right orbit into the right anterior and middle cranial fossa, right temporal fossa and right temporal subcutaneous soft tissues, with extensive osseous destruction.

Surgical biopsy: squamous cell carcinoma (Basaloid Type)



Histopathology of specimen sample shows infiltrative proliferation of solid epithelial nests composed of basaloid cells. Spherical hyalinized materials were present within the tumor nests (arrows; hematoxylin and eosin staining; magnification, $\times 100$). The basaloid cells exhibit hyperchromatic nuclei without conspicuous nucleoli and scant cytoplasm.

Treatment

A diagnosis of squamous cell carcinoma of maxillary sinus confirmed & patient underwent surgical resection of mass & referred to kidwai memorial institute of oncology for post op radiotherapy.

4. Discussion

Squamous cell carcinoma (SCC) is a malignant tumor of the squamous epithelium and the second most common form of skin cancer.⁴ It can occur in many different organs including the lungs, conjunctiva, nasal cavity, mouth, lips and skin. SCC can be "in-situ" meaning it has not broken through the

basement membrane or it can be invasive where it has invaded the underlying tissue. The human papilloma virus has been associated with SCC along with exposure to nickel dust, mustard gas, isopropyl oil, chromium, or dichlorodiethyl sulfide, many of which are found in the furniture-making, leather, and textile industries.^{1,4} SCC accounts for over 80% of all malignancies that arise in the nasal cavity and paranasal sinuses.¹ The presentation can vary depending on the involved organs but SCC originating in the nasal cavity may include a nasal mass or obstruction, rhinorrhea, epistaxis or pain; all of which were symptoms our patient experienced. Long-standing lesions, as in the case of our patient, can alter the patient's facial features causing asymmetry or proptosis of globe. Diagnosis is made by biopsy.

5. Conclusion

SCC is an aggressive and life-threatening condition. Although our patient's tumor was exceedingly large and had invaded multiple sinuses, SCC can present more subtly and involve only the lid, conjunctiva or orbit. Eye care practitioners must be aware of the various ocular manifestations as squamous cell carcinoma, although rare, is the most common conjunctival malignancy. Timely referral is critical for successful treatment.

References

- [1] Tiwari R, Hardillo JA, Mehta D, Slotman B, Tobi H, Croonenburg E, van der Waal I, Snow GB. Squamous cell carcinoma of maxillary sinus. *Head Neck* 2000; 22: 164-169.
- [2] Zaharia M, Salem LE, Travezan R, Moscol A, Pinillos L, Farias C, Pinillos L. Human papillomavirus load and physical status in sinonasal inverted papilloma and squamous cell carcinoma. *Rhinology* 2012; 50:87-94.
- [3] Pilch BZ, Bouquot J, Thompson LDR. Squamous cell carcinoma. World health organization classification of tumours. pathology and genetics of head and neck tumours. In: Barnes L, Eveson J, Reichart P, Sidransky D, editors. Geneva: IARC Press; 2005. pp. 15-17.
- [4] Isaacs JH Jr, Mooney S, Mendenhall WM, Parsons JT. Cancer of the maxillary sinus treated with surgery and/or radiation therapy. *Am Surg* 1990; 56: 327-330.
- [5] Ogawa K, Toita T, Kakinohana Y, Adachi G, Kojya S, Itokazu T, Shinhama A, Matsumura J, Murayama S. Postoperative radiotherapy for squamous cell carcinoma of the maxillary sinus: analysis of local control and late complications. *Oncol Rep* 2001; 8: 315-319.
- [6] Dulguerov P, Jacobsen MS, Allal AS, Lehmann W, Calcaterra T. Nasal and paranasal sinus carcinoma: are we making progress? A series of 220 patients and a systematic review. *Cancer* 2001; 92: 3012-3029.
- [7] Frich JC Jr. Treatment of advanced squamous carcinoma of the maxillary sinus by irradiation. *Int J Radiat Oncol Biol Phys* 1982; 8: 1453- 1459.
- [8] Turner JH, Reh DD. Incidence and survival in patients with sinonasal cancer: a historical analysis of population-based data. *Head Neck* 2012; 34: 877-885.
- [9] Bandoh N, Hayashi T, Kishibe K, Takahara M, Imada M, Nonaka S, Harabuchi Y. Prognostic value of p53 mutations, bax, and spontaneous apoptosis in maxillary

sinus squamous cell carcinoma. Cancer 2002; 94: 1968-1980.

- [10] Konno A, Ishikawa K, Terada N, Numata T, Nagata H, Okamoto Y. Analysis of long-term results of our combination therapy for squamous cell cancer of the maxillary sinus. Acta Otolaryngol Suppl 1998; 537: 57-66.

