

Correlation of Morphological Variants of Soft Palate and Types of Occlusion in Patients Seeking Orthodontic Assessment

Nandhini Subramaniam

Oral medicine and Radiology, Saveetha Dental College

Abstract: ***Aim-**Aim of our study is to investigate the correlation between various shapes of soft palate and types of malocclusion in patients seeking orthodontic treatment. **Material and methods-**The study included 52 patients (male-26, Female-26) seeking orthodontic treatment for malocclusion age ranging from 14 to 28 years. Clinically in all the subjects the type of malocclusion was examined and categorised according to Angle's classification of malocclusion. The morphological variants of soft palate were assessed on digital lateral cephalogram and were allotted to one of the six patterns described by You et al. The differences in the proportion of each type were studied and variation of malocclusion and soft palate morphology between the genders were also assessed. The results obtained were subjected to statistical analysis to find if there is any correlation between variants of soft palate and types of Angle's classification of malocclusion. **Results-**In our study the frequency of rat tail(40.4%) type of soft palate was seen in highest proportion where the frequency of distorted/s shaped and butt shaped(5.8%) soft palate was the least. Angle's class I malocclusion was most common and leaf shaped soft palate was commonly found among them. Patients with class II malocclusion frequently had rat tail shaped soft palate. Among patients with class III malocclusion both leaf and rat tail shaped were equally found. We also found that there is no significant correlation between Angle's malocclusion and variants of soft palate.*

Keywords: soft palate, occlusion,orthodontic assessment, lateral cephalogram

1. Introduction

The soft palate is the posterior fibromuscular part of the palate that is attached to the posterior edge of the hard palate. It is formed by the fusion of 3 components, namely 2 palatal processes and the primitive palate which is formed by frontonasal process. The intramembranous ossification occurs in the mesoderm of the soft palate to form hard palate, where as in the posterior region ossification does not occur and forms the soft palate[2]. It participates in most of the oral functions especially velopharyngeal closure which is related to normal functions of sucking, swallowing and pronunciation. You et al[1] classified soft palate into 6 morphological types(Type 1-Leaf shaped/lanceolate shaped, Type 2- rat tail shaped, Type 3-Butt like shaped,Type 4-straight line shaped,Type5- S shaped/distorted soft palate,Type 6-Crooked shaped)

Malocclusion classified by Angle as follows

- Class I- The mesiobuccal cusp of the upper first molar occludes the mesiobuccal groove of lower first permanent molar along with characteristics such as rotation,diastema,cross bite,deep bite is considered as having Class I
- Class II-The lower first permanent molar mesiobuccal groove occludes posterior to the mesiobuccal cusp of the upper first permanent molar where div 1 is the where upper incisors are proclined and div 2 where they are retroclined while upper laterals have a labial and mesial inclination.
- ClassIII –Malocclusion presenting with mesiobuccal groove of the lower first permanent molar occludes anterior to the upper first permanent molar mesiobuccal cusp.

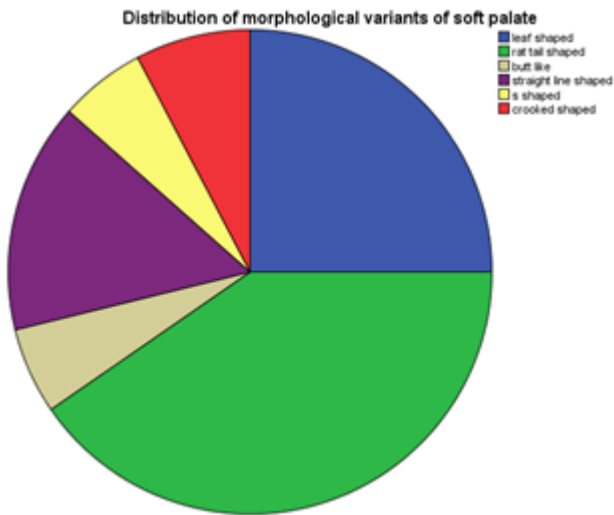
The purpose of our study is to investigate the correlation between various shapes of soft palate and types of malocclusion in patients seeking orthodontic treatment.

2. Materials and methods

The study included 52 patients (male-26,Female-26) seeking orthodontic treatment for malocclusion age ranging from 14 to 28 years. Clinically in all the subjects the type of malocclusion was examined and categorised according to Angle's classification of malocclusion. The morphological variants of soft palate were assessed on digital lateral cephalogram and were allotted to one of the six patterns described by You et al. The differences in the proportion of each type were studied and variation of malocclusion and soft palate morphology between the genders were also assessed. The results obtained were subjected to statistical analysis to find the if there is any correlation between variants of soft palate and types of Angle's classification of malocclusion.

3. Results

Distribution of morphological variants of soft palate and Angle's malocclusion among the study subjects given in graph 1 and 2



In our study the frequency of rat tail(40.4%) type of soft palate was seen in highest proportion where the frequency of distorted/s shaped and butt shaped(5.8%) soft palate was the least

Table 1: Variants of soft palate

		Frequency	Percent	Valid Percent	Cumulative Percent
Valid	leaf shaped	13	25.0	25.0	25.0
	rat tail shaped	21	40.4	40.4	65.4
	butt like	3	5.8	5.8	71.2
	straight line shaped	8	15.4	15.4	86.5
	s shaped	3	5.8	5.8	92.3
	crooked shaped	4	7.7	7.7	100.0
	Total	52	100.0	100.0	

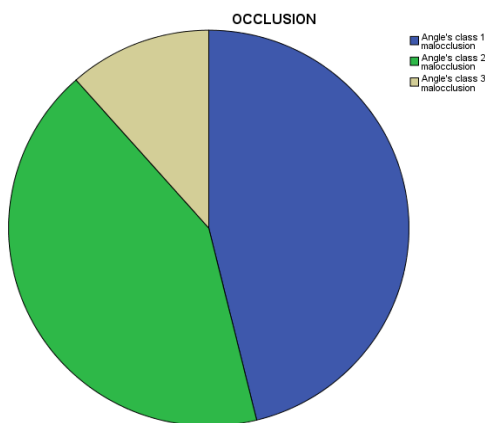


Table 2: Distribution of malocclusion among the subjects

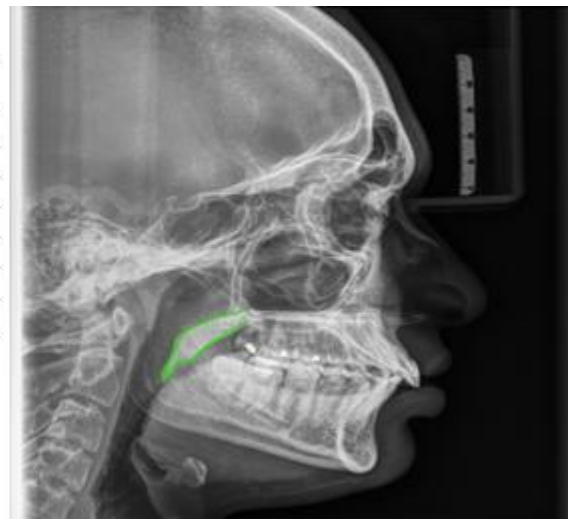		Frequency	Percent	Valid Percent	Cumulative Percent
Valid	Angle's class 1 malocclusion	24	46.2	46.2	46.2
	Angle's class 2 malocclusion	22	42.3	42.3	88.5
	Angle's class 3 malocclusion	6	11.5	11.5	100.0
	Total	52	100.0	100.0	

Angle's class I malocclusion(46.2%) was most common and leaf shaped soft palate was commonly found among them and Class II which is 42.3%

The correlation between both the genders with the shapes of soft palate and types of malocclusion was done using t test and it was statistically insignificant.

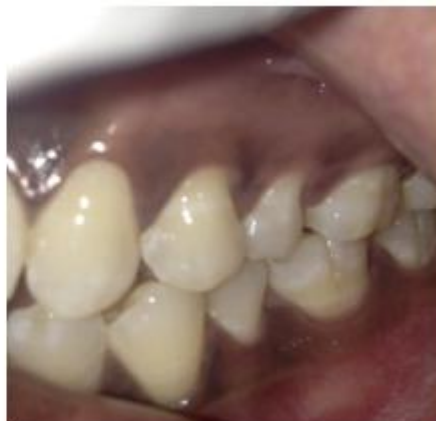Soft palate shapes * GENDER Crosstabulation

Variants of soft palate	Gender		Total
	Male	Female	
leaf shaped	11	2	13
rat tail shaped	10	11	21
butt like	1	2	3
straight line shaped	2	6	8
s shaped	0	3	3
crooked shaped	2	2	4
Total	26	26	52



*Malocclusion * GENDER Cross tabulation*

malocclusion		GENDER		Total
		male	female	
	Angle's class 1 malocclusion	13	11	24
	Angle's class 2 malocclusion	8	14	22
	Angle's class 3 malocclusion	5	1	6
Total		26	26	52



*Soft palate variants*malocclusion Crosstabulation*

		TYPE						Total
		leaf shaped	rat tail shaped	butt like	straight line shaped	s shaped	crooked shaped	
OCCLUSION	Angle's class 1 malocclusion	8	7	1	4	1	3	24
	Angle's class 2 malocclusion	3	12	1	4	2	0	22
	Angle's class 3 malocclusion	2	2	1	0	0	1	6
Total		13	21	3	8	3	4	52

Angle's class I malocclusion was most common and leaf shaped soft palate was commonly found among them. Patients with class II malocclusion frequently had rat tail shaped soft palate. Among patients with class III malocclusion both leaf and rat tail shaped were equally found.

We also found that there is no significant correlation between Angle's malocclusion and variants of soft palate.

<i>Correlations</i>			
		Type	Occlusion
Type	Pearson Correlation	1	-.042
	Sig. (2-tailed)		.765
	N	52	52
Occlusion	Pearson Correlation	-.042	1
	Sig. (2-tailed)	.765	
	N	52	52

4. Discussion

The lateral cephalogram is the most common diagnostic radiograph used in orthodontics. Cephalometric analysis is a commonly accepted technique for evaluation of soft palate because of its easy availability, cost effectiveness and relatively good assessment of soft tissue.[7][15]. The dimensional analysis of the soft palate and its surrounding structures especially velar length and width has been discussed in various studies, nevertheless the variation of velar morphology which is the most logic cause of different different dimintions of soft palate.[14][8]

In our study ,Type II shaped soft palate was the most frequent type(40.4%) while a previous study by You M et al described leaf shaped soft palate to be the classic velar morphology. This variation may be due to the fact that most of our study cases had malocclusion requiring orthodontic treatment.

Angle's class I malocclusion was most common and leaf shaped soft palate was commonly found among them. Patients with class II malocclusion frequently had rat tail shaped soft palate. Among patients with class III malocclusion both leaf and rat tail shaped were equally found. We also found that there is no significant correlation between Angle's malocclusion and variants of soft palate

Obstructive sleep apnea is characterised by the recurrent occlusion of the upper airways resulting from the inspiratory collapse of the pharyngeal wall during sleep.[12] There is an increased incidence of OSA in middle aged adults. It was found that pharyngeal morphology is not immutably established during childhood and adolescence, but changes throughout adult life. There is a tendency toward longer and thicker soft palate and narrower oropharynx during adulthood, which may explain the possible increased incidence of OSA and related disorders occurring later in life. Pepin et al found 'hooked' shaped soft palate patients are indicated as high risk for OSAS. You et al. described this hooked appearance as S shaped soft palate.

5. Conclusion

Knowledge of varied spectrum of velar morphology may help in successful functional and structural repair of soft palate and may also be used in future research into the cause of OSA and related disorders. But the pattern of soft palate does not play any role in management of different malocclusions

References

[1] You M, Li X, Wang H, Zhang J, Wu H, Liu Y, Miao J, Zhu Z. et al. Morphological variety of the soft palate in normal individuals: a digital cephalometric study. Dentomaxillofacial Radiology 2008; 37: 344-9.

- [2] Moore KL, Agur AMR. Essential Clinical Anatomy (2nd edn). Philadelphia, PA: Lippincott, Williams and Wilkins, 2002.
- [3] Johns DF, Rohrich RJ, Awada M. Velopharyngeal incompetence: a guide for clinical evaluation. *Plas Reconstr Surg* 2003; 112: 1890–8.
- [4] Subtelny JD. A cephalometric study of the growth of the soft palate. *Plast Reconstr Surg* 1957; 443–4.
- [5] Satoh K, Wada T, Tachimura T, Fukuda J, Shiba R, Sakoda S, et al. Comparison of the nasopharyngeal growth between patients with clefts (UCLP) and those with non-cleft controls by multivariate analysis. *Cleft Palate Craniofac J* 1997; 34: 405–9.
- [6] Johnston CD, Richardson A. Cephalometric changes in the adult pharyngeal morphology. *Eur J Orthod* 1999; 21: 357–62.
- [7] Taylor M, Hans MG, Strohl KP, Nelson S, Broadbent BH. Soft tissue growth of the oropharynx. *Angle Orthodontist* 1996; 66: 393–400.
- [8] Kollias I, Krogstad O. Adult craniocervical and pharyngeal changes – a longitudinal cephalometric study between 22 and 42 years of age. Part II: morphology of the uvulo glossopharyngeal changes. *Eur J Orthod* 1999; 21: 345–55.
- [9] Maltais F, Carrier G, Cormier Y, Series F. Cephalometric measurements in snorers, non-snorers, and patients with sleep apnoea. *Thorax* 1991; 46: 419–23.
- [10] Randall P, La Rossa D, McWilliams BJ, Cohen M, Solot C, Jawad AF, et al. Palate length in the cleft palate as a predictor of the speech outcome. *Plast Reconstr Surg* 2000; 106: 1254–9.
- [11] Lu Y, Shi B, Zheng Q, Xiao WL, Li S. Analysis of the velopharyngeal morphology in adults with velopharyngeal incompetence after the surgery of a cleft palate. *Annals Plast Surg* 2006; 57
- [12] Pepin JL, Veale D, Ferretti GR, Mayer P, Levy PA. Obstructive sleep apnea syndrome: hooked appearance of the soft palate in awake patients – cephalometric and CT findings. *Radiology* 1999; 210: 163–70.
- [13] Saunders Jr RS, Samei E. A method for modifying the image quality parameters of digital radiographic images. *Med Phys* 2003; 30: 3006–17.
- [14] Hoopes JE, Dellon AL, Frabrikant JI. Cineradiographic definition of the functional anatomy and the pathophysiology of the velopharynx. *Cleft Palate J* 1970; 7: 443–54.
- [15] Simpson RK, Austin AA. A cephalometric investigation on the velar stretch. *Cleft Palate J* 1972;