

Comparison of Two Different Lateral Incisions for Postoperative Surgical Wound Condition of Calcaneum Fractures- A Randomised Study of Closed Intra Articular Joint Depression Type of Calcaneal Fractures Treated with Locking Plate in 58 Non Smokers Patients - Original Article

Dr. Shah Himanshu D¹, Dr Chavali V.H², Dr Daveshwar R.N³

Abstract: ***Introduction:** Calcaneum fractures contribute to majority of fractures affecting adult foot. The frequent mode of trauma is fall from height. Closed joint depression type of calcaneum fractures are managed by open reduction and internal fixation using calcaneum plate from lateral approach. **Materials and Method:** 58 Closed joint depression type of calcaneum fractures in non smoker patients were randomized into two groups A and B. Group A patient were subjected to conventional modified Kocher's incision (extensile lateral) and B group patients were subjected to Seligson's approach. All patients were followed for wound conditions on 3rd, 6th, 9th and so on postoperative days till 3 months. **Results:** Out of 29 patients in group A, 9 developed superficial surgical skin necrosis and one of 29 patients in group B developed superficial surgical skin necrosis which is statistically significant. **Conclusion:** Seligson's incision is better for behavior of surgical wound conditions postoperatively than standard extensile lateral incision in open reduction of calcaneum through lateral approach.*

Keywords: calcaneum fractures, open reduction, lateral approach, wound complications

1. Introduction

Calcaneal fractures account for approximately 2% of all fractures with displaced intra articular fractures comprising 60-75% of these injuries (1). Intra articular joint depression type of calcaneal fractures requires open reduction and internal fixation with calcaneal plate. Open reduction and internal fixation of displaced calcaneal fractures has been shown to be superior to no operative treatment in healthy patients (2). Open reduction and internal fixation of calcaneum using lateral approach is prone for surgical wound complications including superficial skin necrosis to deep infections. Calcaneal surgery is infamous for its post operative surgical wound complications leading to prolonged hospital stay and secondary procedures. Some studies identified covariates associated with an increased risk of wound complications such as a higher body mass index (BMI), smoking and drug abuse. Intra operative risk factors are surgical experience and a single layered closure technique. Surgical timing is also another independent factor for surgical wound complications. (3).

Lateral approach of calcaneum is most commonly used for internal fixation. The complications of an extensile lateral approach have been reported extensively in the literature with surgical wound complication rates varying from 1.8 to 27%. (3). The incidence of osteomyelitis has been reported to be approximately 2.5% (3). Seligson described similar incision considering the anatomy of vascular supply of lateral calcaneal flap. (1). We present a randomized study of surgical wound complication rate in 58 closed joint depression type of calcaneal fractures treated by using two different lateral calcaneal approaches using extensile lateral

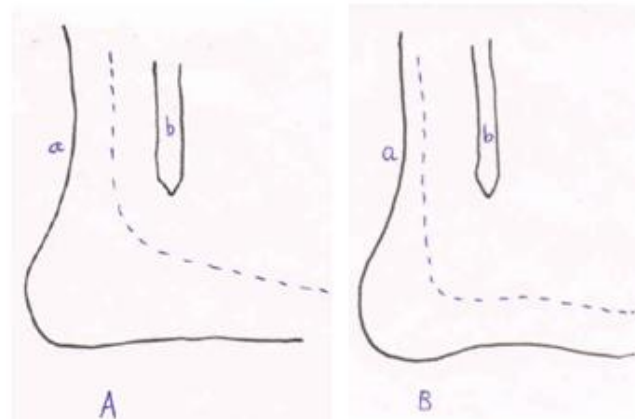
approach and Seligson's approach. The aim of this study was to compare two different surgical incisions using lateral approach for surgical wound complications including superficial wound necrosis to deep infection. Thorough search of literature has not revealed us any study comparing surgical incisions for the wound complications postoperatively as in our study in which all patients were operated by single experienced orthopaedic surgeon with avoiding confounding factor of smoking (risk factor for Peripheral vascular disease) which can lead to wound healing complications.

2. Materials and Method

From December 2013 to October 2015, 72 patients with closed intra articular joint depression type of calcaneum fractures from age group of 18-60 years were admitted in the hospital. Out of 72 patients, 14 patients with history of smoking and signs of peripheral vascular disease of the affected foot (claudication, diminished dorsalis pedis and posterior tibial pulsations) were excluded from the study. Out of 58 patients, randomization was done according to the chronology of admission of patients to the hospital in to the two groups of A and B. i.e. first patient was included in the group A, second patient was included in group B, third consecutive admitted patient to group A and forth was in the group B again. Group A patients were operated by conventional approach named as modified Kocher's approach (extensile lateral). Group B patients were operated by Seligson approach.

All patients were taken for surgery after appearance of wrinkling sign and after thorough foot preparation a day

before surgery including savlon bath. All patients were operated under pneumatic tourniquet control with pressure 100 mm Hg more than systolic B.P.. Modified Kocher's approach was used in patients with incision made halfway between the fibula and Achilles tendon and starting three fingerbreadth proximal to the tip of lateral malleolus. This was extended around the malleolus, following the course of sural nerve and small saphenous vein towards fifth metatarsal base. After identification of sural nerve, full thickness flap was developed. Seligson's approach was used in patients with incision made just lateral to the Achilles tendon and carried vertically to the superior pole of a calcaneus. After skin incision in upper limb of the incision proximal to the tip of lateral malleolus, the subcutaneous tissue and deep soft tissue were dissected thoroughly without damaging the tiny vessels. The incision was then curved gently following a line where the thinner skin of the lateral side of the hindfoot met the skin of the heel pad up to the base of fifth metatarsal. Skin, subcutaneous tissue and periosteum were elevated as a single layer in distal limb of incision distal to tip of lateral malleolus. After elevation of flap, peroneal tendons were retracted using cut Kirschner wires in to the talus and lateral malleolus. Intra articular fracture reduction was done after opening lateral wall of the calcaneum. Locking calcaneum plate was used in all patients using locking screws. Reduction and plate placement confirmation were done by image intensifier. Surgical wound was closed over negative suction drain by subcutaneous and skin sutures. Postoperatively, patients were kept on elevation and anti oedema drugs with analgesics and intravenous antibiotics for 3 days followed by oral therapy. Dressing of surgical wound was done on 3rd, 6th, 9th and at 3 days interval postoperatively along with surgical wound condition. Negative suction drain was removed on 3rd postoperative day. Patients were discharged from ward after clear dressing. In anytime dressing, if superficial skin necrosis is found, swab culture and sensitivity was sent and intravenous antibiotics were continued for 7 days. Sutures removal was done in outpatient department after second week of surgery. All patients were protected by below knee splint and non weight bearing mobilization from 3rd postoperative day for 1 month. During follow up, surgical wound condition was assessed after 1st, 2nd and 3rd month along with xrays to detect signs of union. Minimum 3 months of follow up was done for each patient. Surgical time was noted from skin incision to skin closure. Surgical wound condition was graded according to the criteria of guidelines of surgical site infection.



3. Results

Out of 58 patients, minimum age at presentation was 18 years and maximum was 60 years. All patients were male and non smokers. All had closed intra articular joint depression type of calcaneal fractures. Only one patient out of 58 was diabetic and was randomized to group B. 50 patients had sustained injury due to fall from height and 8 had road traffic accident as mode of trauma. Average age of presentation was 33.9 years in group A and 34.1 years in group B. 33 patients had left sided involvement and 25 patients had right sided involvement. Average Trauma surgery interval in group A was 8 days, 7.13 days in group B. All patients were operated under tourniquet control with using locking calcaneal plates.

Total surgical time was noted from skin incision to skin closure which was 29.1 minutes in group A and 31.5 minutes in group B.

Superficial surgical wound necrosis was noted at angle of surgical incision in 9 out of 29 patients in group A at 3rd postoperative day out of which 8 superficial surgical wound necrosis at angle at 6th and 9th postoperative day which resolved subsequently and average suture removal time was 20 days in group A. out of 29 patients in group B, only one patient had superficial surgical skin necrosis on 3rd, 6th and 9th postoperative day and resolved subsequently with average suture removal time was 18.5 days.

All patients with superficial surgical wound necrosis were negative for swab culture.

The average union time was 3 months in all patients.

4. Discussion

Surgical wound complications including superficial skin necrosis to deep infection are common complications following lateral approach to calcaneum. Extensile lateral approach to calcaneum is most commonly used approach for lateral calcaneal plate fixation following open reduction. Modified Kocher's approach was described by fernandeze in which incision was made halfway between fibula and Achilles tendon and starting three finger breadths proximal to the lateral malleolus. Full thickness flap is developed protecting the sural nerve and short saphenous vein (1). Seligson has described lateral approach using vertical limb

of incision just lateral to the edge of tendoachilles with curving the incision gently following a line where the thinner skin of the lateral side of the hindfoot met the skin of the heel pad up to base of the fifth metatarsal with preserving all veins over vertical limb of incision proximal to the lateral malleolus tip.

Borelli described the arterial blood supply of the subcutaneous tissues of the lateral hindfoot and defined the relationship between these arteries and lateral extensile incision used for ORIF of calcaneal fractures. Three arteries-lateral calcaneal, lateral malleolar and the lateral tarsal artery are found along the lateral aspect of hindfoot. The lateral calcaneal artery appeared to be responsible for the majority of blood supply to the vertical incision which is damaged during the lateral extensile approach (1).

There is a watershed area on lateral aspect of heel between the cutaneous arterial territories of the peroneal artery superiorly and the lateral plantar artery inferiorly. The posterior watershed is between the peroneal artery and the region supplied by posterior tibial artery. This watershed is exploited by the extended lateral approach. This incision probably divides the peroneal artery and makes the posterior skin ischemic.(4)

As per literature, lateral extensile approach leads to up 25% of surgical wound complications due to damage to lateral calcaneal arterial supply to lateral flap (3). In our study out of patients, 9(31%)developed wound complications which are superficial skin necrosis commonly around angle of incision which are culture negative and healed well without deep infections within 1 month, though it led to delayed wound healing, longer hospital stay, increased doses of intravenous antibiotics (though they were negative for culture) and overall increased morbidity postoperatively. Court Brown et al have reported 5% deep infections and 20% of superficial infections following extensile lateral approach in 178 intra articular calcaneal fractures.(5)

Seligson has described modification of standard approach according to the anatomical basis of blood supply to the lateral skin flap. In our study, 1 out of 29 patients (3%), developed superficial wound necrosis with Seligson's approach which was healed subsequently without deep infection. No study has been found in the literature using Seligson's approach for calcaneal fractures and comparing it with standard approach. Even the anatomical approach was also associated with wound complications as the vertical limb of incision could be a risk factor for damage to vascularity of lateral skin flap.

As cause of wound complications following calcaneal surgery are multifactorial (5), there is not only one causative factor associated with wound healing. But as per our study, there was significant difference in the wound complication rates among two different surgical incision methods, incision is also one of the major factors responsible for wound complications following calcaneal open reduction and fixation. The superficial wound complications observed in group A is statistically significant than in group B.

The suture removal time postoperatively was also more in group A as compared to group B in our study though found statistically insignificant.

Smoking is risk factor for peripheral vascular disease which can lead to wound complications (5). So we ruled out the confounding factor of smoking by exclusion criteria for our study. Surgeon's experience was independent risk factor for developing wound complications (5), so all our patients were operated by experienced orthopaedic surgeon as prolonged operating time associated with inexperience surgeon leads to higher wound complication rate. Delay to the surgery with appearance of wrinkle sign was one of the favorable factors for prevention of the development of wound complications. Negative suction drain and elevation postoperatively were also independent favorable factors for prevention of wound complications which we had used in all our patients.

All the patients in two groups in our study had comparable radiological and clinical outcome at three months of follow up without compromising reduction and fixation.

We had excluded all confounding factors which were responsible for development of wound complications and compared two different incision patterns for development of wound complications in this study which revealed that Seligson's approach was associated with lower wound complications than standard extensile lateral approach.

5. Conclusion

The Seligson incision was superior than the extensile lateral approach in superficial wound complications. The suture removal time was also lower in Seligson incision as compared to the extensile lateral incision though statistically insignificant.

References

- [1] Robert Bukoltz, Charles Courtbrown, James Hackman, Paul Tornetta. Rockwood and Green's fractures in adults 2010 7th edi, 3rd volume: 2064-80.
- [2] Ahmed Abdelazeem, Ahmed Khedr, Mostafa Abousayed, Ahmed Seifeldin, Sherif Khaled. Management of displaced intra articular calcaneal fractures using the limited open sinus tarsi approach and fixation by screws only technique. International Orthopaedics 2014; 3:601-06.
- [3] Manouk Backes, Tim Schepers, M.suzan H. Beerekamp, Jan s.k. Luitse, J.Carel Goslings, Niels W. L. Schep. Wound infections following open reduction and internal fixation of calcaneal fractures with an extended lateral approach. International Orthopaedics 2014; 4:767-73.
- [4] Brian J. C. Freeman, Sarah Duff, Patricia E. Allen, and Helen D. Nicholson, Roger M. Atkins. The extended lateral approach to the hindfoot: ANATOMICAL BASIS AND SURGICAL IMPLICATIONS. Journal of Bone and Joint Surgery (Br) 2009; 80 B: 139-42.
- [5] Charles M. Court-Brown a, Matthias Schmidt a, Bernard G. Schutte. Factors affecting infection after calcaneal fracture fixation. Injury; 40:1313-15.