

Management of Chronic Generalized Periodontitis by Adjunctive Use of Diode Laser

Mariya Miteva, Stefan Peev, Ivailo Hristov

Department of Periodontology and Dental Implantology, FDM, Medical University of Varna

Abstract: *The aim of this study was to evaluate the effect of a diode laser with nonsurgical periodontal therapy on chronic periodontitis. Fifteen patients with chronic periodontitis were treated by conventional periodontal treatment using ultrasonic devices and hand instruments and fifteen patients with additional use of diode laser Elexxion claros, fiber 300 µm, pulse output 1,0 W; pulse freq. CW; pulse duration CW; avg. power 1 W. All groups showed statistically significant improvements in terms of clinical attachment level (CAL) gain and periodontal pocket depth (PPD) reduction compared to baseline. The obtained data suggested that SRP and adjunctive laser therapy have significant short-term benefits in the treatment of chronic periodontitis.*

Keywords: Periodontitis, chronic, Diode laser

1. Introduction

Periodontitis is caused by anaerobic bacteria, which form a biofilm on tooth surfaces or in the periodontal pocket. These actions provoke an excessive and aggressive immune reaction in the host, and cause collateral damage to periodontal tissues. Removal of the biofilm and elimination of periodontal pathogens from the periodontal pocket is the main purpose of treatment for this disease. Scaling and root-planing (SRP) is a non-surgical method of mechanical debridement to eliminate calculus, plaque, and contaminated root cementum from the periodontal pocket and usually results in significant clinical improvement. As an adjunct to SRP in inaccessible areas, various other treatment strategies have been evaluated, including the use of lasers. Diode lasers have been shown to be effective modalities in non-surgical periodontal therapy, with clinical effects including detoxification of the root surface, and bacterial lysis.

2. Literature Survey

In vitro studies have tested the efficiency of diode lasers in periodontal debridement using several models: 665-nm AlGeAs (aluminium-germanium-arsenide) laser [1], 810-nm GaAlAs (gallium-aluminium-arsenide) laser [1, 2], 655-nm GaAlAs laser [3] and 980-nm diode laser [4]. In all these studies, there was a minimal increase in temperature of 5 °C above the acceptable limits. The bactericidal effect of these lasers depend on the type of bacteria, the wavelength and the dose [3].

In vitro removal of calculus with a diode laser appears to be consistent and comparable with hand SRP [1, 2, 3, 4].

Other in vitro studies reported no beneficial effect on the attachment of periodontal cells on the root surface after irradiation with GaAlAs diode laser at the point of 1 W for 20 seconds [3] or harmful ultrastructural changes that could affect the synthesis of collagen [5].

In in vivo studies with diode lasers are established large amounts of calculus after treatment and significant structural damage to the root surface [3]. Yilmaz et al. [6] using

GaAlAs laser in a randomized controlled study and they found no beneficial effects in comparison only with SRP.

3. Material

The study included 30 male and female patients aged between 37-63 years, systemically healthy, none-smokers with presence of chronic generalized periodontitis - superficialis or profunda. Patients were divided into two groups - Group 1 (SRP) and Group 2 (SRP +Diode laser).

Supra- and subgingival plaque and calculus are removed (scaling) with ultrasound equipment and tips for supra- and subgingivally instrumentation. After cleaning supragingival tooth surfaces are polished with rubber, brush and an abrasive paste. A rinse solution that contains 0.1% chlorhexidine and inhibits plaque formation was prescribed to the patients bid for 2 weeks. A toothpaste that inhibits plaque formation was prescribed to the patients as well.

On the next visit the pocket depth, gingival margin, furcation involvement and mobility were examined. Debridement of the root surfaces is performed within 24 hours (as per the principle of complete oral cavity disinfection - full mouth disinfection) with manual Gracey curettes with vertical, horizontal and oblique moves to a tactile sense of clean and smooth root surface. During the instrumentation washes with physiological saline solution (0,9% NaCl) are carried out - Group 1. After manual instrumentation in Group 2 the periodontal pockets are treated with Diode laser Elexxion claros, 50 Watt with fiber tip 300 µm, the settings of the laser apparatus in the program "Germ reduction in pockets" - pulse output 1,0 W; pulse freq. CW; pulse duration CW; avg. power 1 W for 15 seconds. The fiber is inserted into the periodontal pocket in depth measured from -1 mm and moves with spiral movements in coronary direction. Patient and staff put protective eyeglasses.

The baseline data were recorded before treatment and at 1,5 and 3 months following treatment. Clinical measurements were taken at six points around each tooth: mesio-lingual, mesio-facial, facial, disto-facial, disto-lingual and lingual. The following clinical parameters were measured: Plaque

Index (PI), Gingival Index (GI), Probing Depth (PD), Clinical Attachment Level (CAL), Gingival Margin (GM).

4. Results

On Figures 1, 2 and 3 are shown the average pocket depth, clinical attachment level and gingival margin by groups and periods

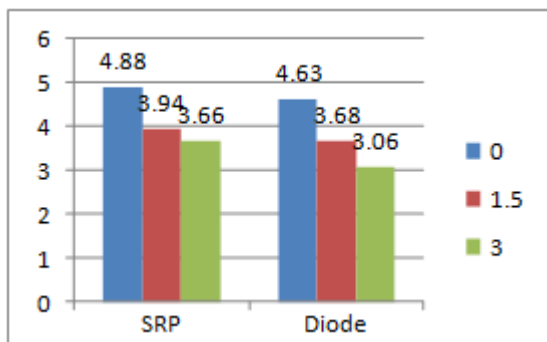


Figure 1: Pocket depth by groups and periods

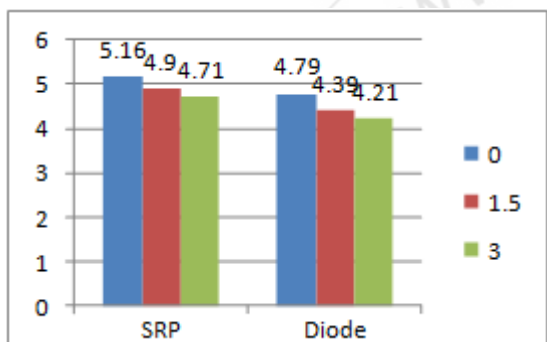


Figure 2: Clinical attachment level by groups and periods

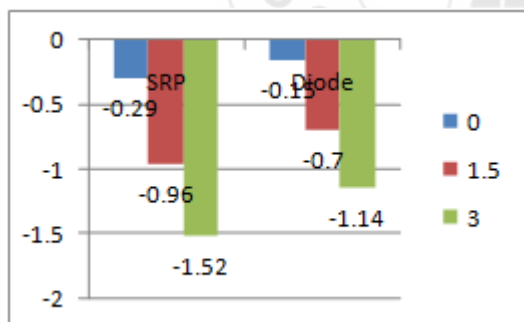


Figure 3: Gingival margin by groups and periods

The mean PD at baseline was 4.63mm, at 6 weeks 3.68 mm and at 3 months 3.06 among the laser treatment group. The mean PD at baseline was 4.88 mm, at 6 weeks 3.94 mm and at 3 months 3.66 mm among the SRP group. The comparison of mean PD at baseline, 6 weeks and 3 months for both the laser treatment group and the SRP group was found to be statistically significant.

The mean PD reduction at 3 months was found to be 1.57 mm among the laser treatment group and 1.69 mm among the SRP group. This implies that although the PD decreased significantly in both treatment groups compared to baseline, SRP was insignificant more effective in reduction of PD

compared to laser assisted pocket therapy at 3 months post-treatment interval.

The mean clinical attachment level (CAL) at baseline was 4.79 mm, at 6 weeks 4.39 mm and at 3 months 4.21 mm among the laser treatment group. The mean CAL at baseline was 5.16 mm, at 6 weeks 4.90 mm and at 3 months 4.71 mm among the SRP group. The comparison of mean CAL at baseline, 6 weeks and 3 months for the laser treatment and SRP group was found to be statistically significant.

The mean CAL gain at 6 weeks was found to be 0.40 mm among the laser treatment group and 0.26 among the SRP group. The mean CAL gain at 3 months was found to be 0.18 mm among the laser treatment group and 0.19 mm among the SRP group. The comparison of mean CAL gain at 6 weeks and 3 months between the laser treatment and SRP was found to be statistically not significant.

This implies that there was significant gain in CAL in both treatment groups compared to baseline, and laser assisted pocket therapy was equally effective in producing CAL gain compared to SRP at both 6 weeks and 3 month post-treatment intervals.

The mean gingival margin (GM) at baseline was -0.15 mm at 6 weeks -0.70 mm and at 3 months -1.14 mm among the laser treatment group. The mean GM at baseline was -0.29 mm, at 6 weeks -0.96 mm and at 3 months -1.52 mm among the SRP group. The comparison of mean GM at baseline, 6 weeks and 3 months for the laser treatment and SRP group was found to be statistically significant.

The mean increase in gingival recession (GR) at 6 weeks was found to be 0.55 mm among the laser treatment group and 0.67 mm among the SRP group. The mean increase in GR at 3 months was found to be 0.44 mm among the laser treatment group and 0.56 among the SRP group.

The comparison of mean increase in GR at 6 weeks and 3 months between the laser treatment and SRP was found to be statistically insignificant. Although not significantly sites treated with laser assisted pocket therapy show less GR when compared to sites treated with SRP alone.

5. Discussion

Gain of attachment level was observed in both groups at 3 months follow-up examination with no statistically significant difference between the groups. Similarly, some studies have shown no significant difference in attachment gain between cases treated with SRP combined with diode laser [7, 8] and those treated only with SRP. These findings are not in agreement with those of some recent randomized clinical trials, which showed that treatment with laser irradiation [9] as an adjunct to conventional SRP have more efficacy in attachment gain than SRP alone. The most probable reason for lack of difference between groups is discontinuity of laser therapy.

The results of the present study are in accordance with those of studies evaluating the effect of photodisinfection alone and in combination with conventional SRP [10, 11]. Assessing 33 patients with chronic periodontitis,

Andersen *et al.* reported a clinical attachment gain of 0.36 ± 0.35 mm in the group treated with SRP alone after 12 weeks. A gain of 0.86 ± 0.61 mm was observed for SRP with adjunctive aPDT. These values are in agreement with those reported in the present study.

The results of the present study showed significant reduction in gingival level in both groups. In fact we expected it because of removal of local stimulating factors and reduction of the severity of inflammation. Also, we don't have statistically significant differences between the two groups which confirm no harmless effect of recommended protocol on gingival tissue.

Borajo et al in 2004 [7] in the evaluation of adjunctive laser therapy with wavelength 980nm and the power of 2 W using 200 μ m fiber in pulsed mode showed a significant reduction on gingival level, however according to the present study there wasn't any significant difference between test and control groups in gingival recession.

6. Conclusion

The aim of the present study was to compare the effectiveness of a Diode laser (980 nm) used as an adjunctive therapy to SRP with that of SRP alone for non surgical periodontal treatment in patients with chronic periodontitis

The use of diode laser as adjunctive therapy to scaling and root planing provided no additional clinical benefit over conventional mechanical treatment

References

- [1] Chan Y, Lai CH. Bactericidal effects of different laser wavelengths on periodontopathic germs in photodynamic therapy. *Lasers Med Sci.* 2003;18(1):51-5.
- [2] Theodoro LH, Haypek P, Bachmann L, Garcia VG, Sampaio JE, Zezell DM, Eduardo Cde P. Effect of ER:YAG and diode laser irradiation on the root surface: morphological and thermal analysis. *J Periodontol.* 2003 Jun;74(6):838-43.
- [3] Kreisler M, Meyer C, Stender E, Daubländer M, Willershhausen-Zönnchen B, d'Hoedt B. Effect of diode laser irradiation on the attachment rate of periodontal ligament cells: An in vitro study. *J Periodontol* 2001;72:1312-1317.
- [4] Romanos GE, Henze M, Banihashemi S, Parsanejad HR, Winckler J, Nentwig GH. Removal of epithelium in periodontal pockets following diode (980 nm) laser application in the animal model: an in vitro study. *Photomed Laser Surg.* 2004 Jun;22(3):177-83.
- [5] Marques MM, Pereira AN, Fujihara NA, Nogueira FN, Eduardo CP. Effect of low-power laser irradiation on protein synthesis and ultrastructure of human gingival fibroblasts. *Lasers Surg Med* 2004;34:260-265.
- [6] Yilmaz S, Kuru B, Kuru L, Noyan U, Argun D, Kadir T. Effect of gallium arsenide diode laser on human periodontal disease: a microbiological and clinical study. *Lasers Surg Med.* 2002;30(1):60-6.
- [7] Borrajo JL, Varela LG, Castro GL, Rodríguez-Nuñez I, Torreira MG. Diode laser (980 nm) as adjunct to scaling

and root planing. *Photomed Laser Surg.* 2004;22(6):509-12.

- [8] Euzebio Alves VT, de Andrade AK, Toaliar JM. et al. Clinical and microbiological evaluation of high intensity diode laser adjunct to non-surgical periodontal treatment: a 6-month clinical trial. *Clin Oral Investig.* 2013;17(1):87-95
- [9] Birang R, Yaghini J, Adibrad M, Kiany S, Mohammadi Z, Birang E. The Effects of Diode Laser (980 nm Wavelength) and Chlorhexidin Gel in the Treatment of Chronic Periodontitis. *J Lasers Med Sci.* 2011;2(4):131-138.
- [10] Braun A, Dehn C, Krause F, Jepsen S. Short-term clinical effects of adjunctive antimicrobial photodynamic therapy in periodontal treatment: A randomized clinical trial. *J Clin Periodontol* 2008;35:877-84.
- [11] Andersen R, Loebel N, Hammond D, Wilson M. Treatment of periodontal disease by photodisinfection compared to scaling and root planing. *J Clin Dent* 2007;18:34-8