

A Study of Common Locations of Placenta in Antenatal Ultrasound

Dr Srinivas Prasad

Department of Radiology and Imaging, East Point Medical College, Bangalore

Abstract: *Ultrasound imaging has become an integral component of routine prenatal medical care. During an obstetrical ultrasound, evaluation of the fetus is chief priority but often, the other component which is also important like the placenta are not given the attention they deserve. This study focuses on the aim to find the most common frequency of placental locations in this part of the world. The association factor of the highest frequency location with the total population has to be found out. This study helps the fellow radiology practitioners to know the most common locations of the placenta and thus helps them to better locate the placenta.*

Keywords: Placenta, Location, Uterus, USG, Imaging

1. Introduction

Ultrasound imaging has become an integral component of routine prenatal medical care. During an obstetrical ultrasound, evaluation of the fetus is chief priority but often, the other component which is also important like the placenta are not given the attention they deserve [1]. Both the American College of Obstetricians and Gynecologists and the American Institute of Ultrasound in Medicine recommended that the standard obstetric sonogram in the second and/or third trimester the morphology and function of the umbilical cord [2,3]. While abnormalities in amniotic fluid volume and umbilical cord Doppler velocimetry are done sonographic assessment of placental location (PL), after exclusion of previa or marginal insertion is often limited to a mere notional description without any link to possible implications on pregnancy. [4-6]. Furthermore, studies of its association with specific obstetric complications have reached contradictory conclusions and no consensus has yet been achieved regarding the relationship between PL and non-vertex fetal presentation (FP) at term [7,8].

This study focuses on the aim to find the most common frequency of placental locations in this part of the world. The association factor of the highest frequency location with the total population has to be found out. This study helps the fellow radiology practitioners to know the most common locations of the placenta and thus helps them to better locate the placenta.

2. Aims and Objectives

To study the common locations of placenta in antenatal ultrasound.

3. Materials and Methods

This study was done in the Department of Radio-Diagnosis and Imaging in East Point College of Medical Sciences and Research Centre at Bangalore.

The study was done using 1548 patients who had come for the routine check – up for their ante – natal care and had been referred to the Department of Radiology for routine second trimester and third trimester scan.

The patients were asked to drink sufficient water and then were asked to lie in supine position. The USG gel was applied sufficiently and the USG abdomen were carried out.

The routine scanning was done to note the health of the baby and also particular importance was given to note the position of the placenta. The area where the placenta was noted in an excel sheet and necessary statistics were done.

4. Report

Table 1: Mean age of the population:

Sample Size	Mean age of the Population
1562	25.61 years

Table 2: The Locations of the Placenta

	Frequency
Fundal	96
Fundoposterior	217
Fundoanterior	65
Posterior Upper	357
Anterior Upper	653 (one twin pregnancy)
Anterior Lower	47
Posterior Lower	45
Right Lateral Wall	40
Left Lateral Wall	38
Partial Previa	3
Complete Previa	1
Total	1562

Image 1: The Locations of the Placenta

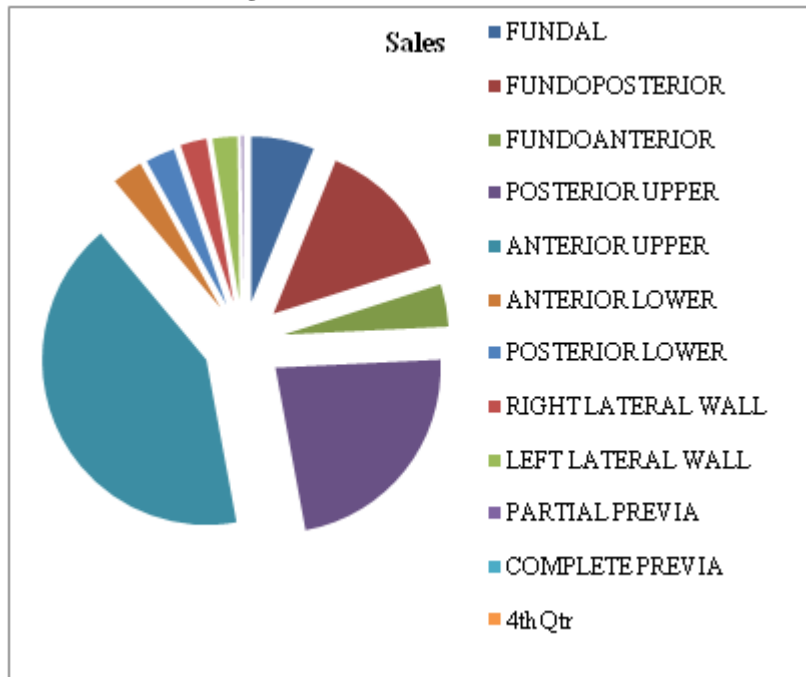


Table 3: Table of Association

Type	P Value	Significance (<0.05)
Anterior Upper	0.034	Sig

5. Discussion

The visualization of in-utero fetal activity during the various stages of gestation may help Perinatologists comprehend the existing relationships between fetal behavior and neurological development and maturation [09]. In the era in which “reducing the primary cesarean delivery rate represents a worldwide priority”, [10,11] an investigation focused on PL and its impact on fetal presentation at term should be considered relevant. A very recent ACOG consensus strongly recommends offering pregnant woman with non-cephalic FP after 36 gestational weeks the option of external cephalic version [12].

Only eutherian mammals possess placenta. The human placenta is discoid, because of its shape; hemochorial, because of direct contact of the chorion with the maternal blood and deciduate, because some maternal tissue is shed at parturition. The placenta is attached to the uterine wall and establishes connection between the mother and fetus through the umbilical cord. The fact that maternal and fetal tissues come in direct contact without rejection suggests immunological acceptance of the fetal graft by the mother. The placenta is developed from two sources. The principal component is fetal which develops from the chorion frondosum and the maternal component consists of decidua basalis. When the interstitial implantation is completed on 11th day, the blastocyst is surrounded on all sides by lacunar spaces around cords of syncytial cells, called trabeculae. From the trabeculae develops the stem villi on 13th day which connect the chorionic plate with the basal plate. Primary, secondary and tertiary villi are successively developed from the stem villi. Arterio-capillary-venous system in the mesenchymal core of each villus is completed

on 21st day. This ultimately makes connection with the intraembryonic vascular system through the body stalk.

Simultaneously, lacunar spaces become confluent with one another and by 3rd-4th week, form a multilocular receptacle lined by syncytium and filled with maternal blood. This space becomes the future intervillous space. As the growth of the embryo proceeds, decidua capsularis becomes thinner beginning at 6th week and both the villi and the lacunar spaces in the abembryonic area get obliterated, converting the chorion into chorion laeve. This is, however, compensated by (a) exuberant growth and proliferation of the decidua basalis and (b) enormous and exuberant division and subdivision of the chorionic villi in the embryonic pole (chorion frondosum). These two, i.e., chorion frondosum and the decidua basalis form the discrete placenta. It begins at 6th week and is completed by 12th week. Until the end of the 16th week, the placenta grows both in thickness and circumference due to growth of the chorionic villi with accompanying expansion of the inter - villous space. Subsequently, there is little increase in thickness but it increases circumferentially till term. The human hemochorial placenta derived its name from hemo (blood) that is in contact with the syncytiotrophoblasts of chorionic tissue.

In our study the highest frequency was found to be the Anterior Lower location. This was the most common site followed by posterior upper and fundoposterior. Our study is in agreement with Salvatore Gizzo et al [13]. The only limitation of the study was that we in the Department of Radiology could not know the progression and the final fate of the specific type of placental locations. This study has a bright future and I sincerely hope that this study may help the Gynecologists also to know the different outcomes of the Maternal and the Fetal Health status. In our study there was a twin pregnancy I which both the placentas were found in the Anterior Lower location of the Uterus.

6. Conclusion

The most common location was found to be Anterior Lower location of the uterus followed by posterior upper and fundoposterior.

care? A large cohort study. *Int J Clin Exp Med.* 2015; 8(8): 13056–13066.

References

- [1] Oyelese Y. Placenta, umbilical cord and amniotic fluid: the not-less-important accessories. *Clin Obstet Gynecol.* 2012;55:307–23.
- [2] American College of Obstetricians and Gynecologists. ACOG Practice Bulletin No. 101: Ultrasonography in pregnancy. *Obstet Gynecol.* 2009;113:451–61.
- [3] American Institute of Ultrasound in Medicine. AIUM practice guideline for the performance of obstetric ultrasound examinations. *J Ultrasound Med.* 2013;32:1083–101.
- [4] Patrelli TS, Gizzo S, Cosmi E, Carpano MG, Di Gangi S, Pedrazzi G, Piantelli G, Modena AB. Maternal hydration therapy improves the quantity of amniotic fluid and the pregnancy outcome in third-trimester isolated oligohydramnios: a controlled randomized institutional trial. *J Ultrasound Med.* 2012;31:239–44.
- [5] Cosmi E, Ambrosini G, D'Antona D, Saccardi C, Mari G. Doppler, cardiotocography, and biophysical profile changes in growth-restricted fetuses. *Obstet Gynecol.* 2005;106:1240–5.
- [6] Yoon SY, You JY, Choi SJ, Oh SY, Kim JH, Roh CR. A combined ultrasound and clinical scoring model for the prediction of peripartum complications in pregnancies complicated by placenta previa. *Eur J Obstet Gynecol Reprod Biol.* 2014;180:111–5.
- [7] Fung TY, Sahota DS, Lau TK, Leung TY, Chan LW, Chung TK. Placental site in the second trimester of pregnancy and its association with subsequent obstetric outcome. *Prenat Diagn.* 2011;31:548–54.
- [8] Witkop CT, Zhang J, Sun W, Troendle J. Natural history of fetal position during pregnancy and risk of nonvertex delivery. *Obstet Gynecol.* 2008;111:875–80.
- [9] Guimarães Filho HA, Araujo Júnior E, Mello Júnior CF, Nardozza LM, Moron AF. Assessment of fetal behavior using four-dimensional ultrasonography: current knowledge and perspectives. *Rev Assoc Med Bras.* 2013;59:507–13.
- [10] Filipov E, Borisov I, Kolarov G. [Placental location and its influence on the position of the fetus in the uterus] . *Akush Ginekol (Sofia)* 2000;40:11–2.
- [11] 28. Fianu S, Václavíková V. The site of placental attachment as a factor in the aetiology of breech presentation. *Acta Obstet Gynecol Scand.* 1978;57:371–2.
- [12] 29. Sekulic SR. Possible explanation of cephalic and noncephalic presentation during pregnancy: a theoretical approach. *Med Hypotheses.* 2000;55:429–34.
- [13] Salvatore Gizzo,¹ Marco Noventa,¹ Amerigo Vitagliano,¹ Michela Quaranta,² Valentina Di Giovanni,¹ Shara Borgato,¹ Carlo Saccardi,¹ and Donato D'Antona¹ Sonographic assessment of placental location: a mere notional description or an important key to improve both pregnancy and perinatal obstetrical