

# A Study of Functional Outcome of Distal Tibial Fractures Treated by Minimally Invasive Percutaneous Plate Osteosynthesis

Dr. Chakravarthy .R<sup>1</sup>, Dr. Pratheesh Mohanraj<sup>2</sup>, Dr. Ramprashanth .K<sup>3</sup>

Meenakshi Medical College & Research Institute

## 1. Introduction

The distal part of tibia is more superficial in nature. The soft tissue coverage and the blood supply to the bone in this area is comparatively less. Injuries to the distal end of tibia produce more morbidity due to the compromised blood supply, variable involvement of the articular surface and soft tissue damage. Intra-articular fractures of the distal tibia are additionally called 'pilon fractures' or 'tibial plafond fractures'. With the recent increase in high velocity injuries, treatment of these have become demanding. Fracture pattern, soft tissue injury, and bone quality critically influence the selection of fixation technique. Various methods of treatment like external fixation, intramedullary nailing, and locking plates have been considered. Among these, intramedullary nailing is not feasible in this region due to the distal nature of the injury because of which the distal screws cannot be placed and to the possibility of rotational misalignment during the course of fracture healing. External fixators can lead to inaccurate reduction, malunion, non-union and pin tract infection. Intramedullary nailing is considered standard for surgically managing tibial fractures, but the distal tibia poses concerns regarding the stability of fixation, the risks of secondary displacement of the fracture on insertion of the nail, breakage of nails and locking screws, and final alignment of the tibia. Classic open reduction and internal plate fixation require extensive soft tissue dissection and periosteal stripping even in expert hands, with high rates of complications, including infection, delayed union, and nonunion. Minimally invasive techniques offer fixation in the biological manner with preservation of the bone's vascularity, soft tissue envelope and containment of the fracture hematoma.

## 2. Aims and Objectives

To evaluate the technique of surgical management distal tibial fractures treated by internal fixation with locking compression plates and screws through MIPPO.

To analyze the functional outcome in terms of –

- Time taken to unite
- Range of ankle motion at the end of union
- Rate of wound infection
- Percentage of skin necrosis
- Amount of angulation at union and
- Associated complications.

- To comment on the efficacy of treatment of distal tibia fractures with Locking compression plates through MIPPO.

## 3. Materials and Methods

We prospectively followed up twenty one patients who presented to the casualty during the period from December 2015 to September 2017. Out of the twenty one study subjects 12 were males and 9 were females showing a male preponderance. All study subjects were adults within the age group of 18 to 65 years with a mean age 45 years. Mechanisms of injuries varied from road traffic accidents to falls and crushing injuries with twelve road traffic accidents forming the major cause, eight self falls and one crushing injury. There were two compound fractures. All fractures were classified under AO/ OTA '43' classification. This included both intra articular (tibialplafond) fractures and extra articular where interlocking intramedullary nailing was not feasible or would produce rotational instability.

### Inclusion criteria

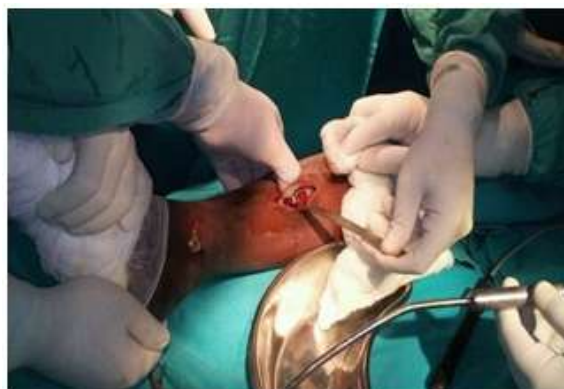- Men or Women aged 18 to 65 years of age.
- All cases of distal tibial fractures.

### Exclusion criteria

- Terminally ill patients with multiple medical comorbidities.
- Poorly ambulatory patients.

Symptoms and functional evaluation was by Tenny & Wiss Criteria

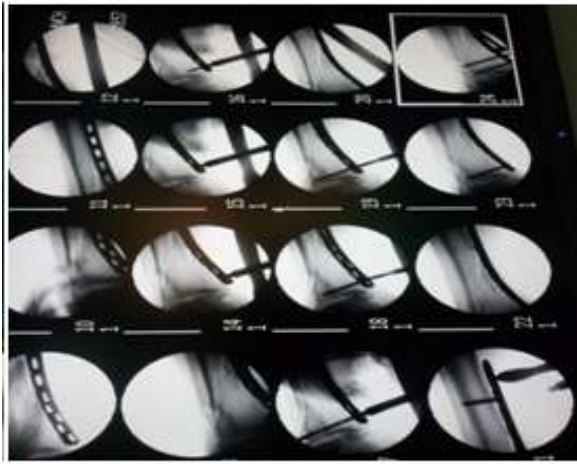
## 4. Intra OP Pictures



Volume 6 Issue 10, October 2017

[www.ijsr.net](http://www.ijsr.net)

Licensed Under Creative Commons Attribution CC BY

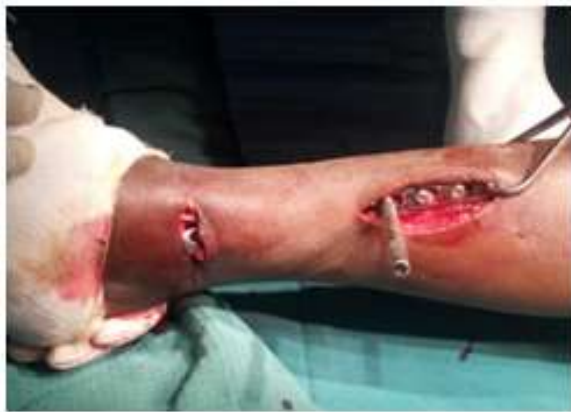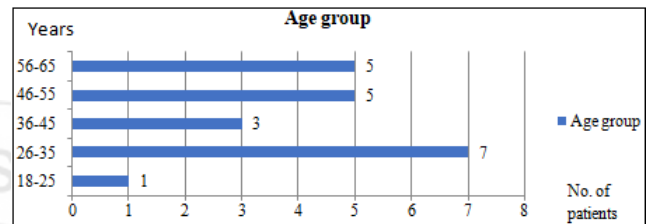


both radiologically and clinically. Radiologically, sign of callus formation is noted and clinically, the improvement in the range of motion and the reduction in pain were noted. All patients were assessed according to Tenny and Weiss scoring system. In patients who requested for the implant to be removed, it was done after consolidation of the callus was noted in the radiographs, usually not before 18 months from surgery.

## 6. Analysis

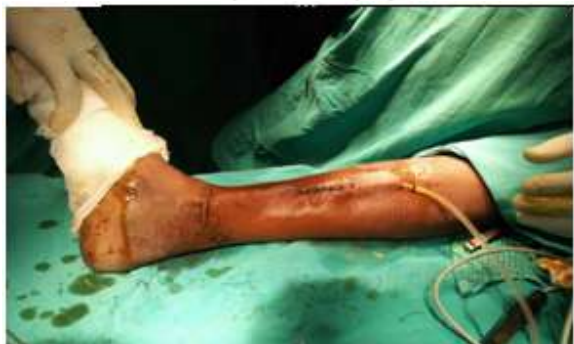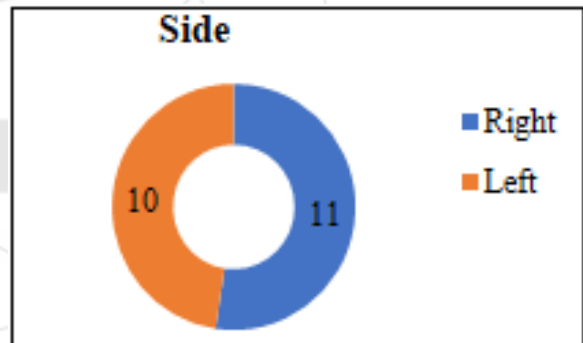
### Age Group

The age of patients in the study ranged from 18 to 65 Years with an average of 44.42 years at the time of surgery.



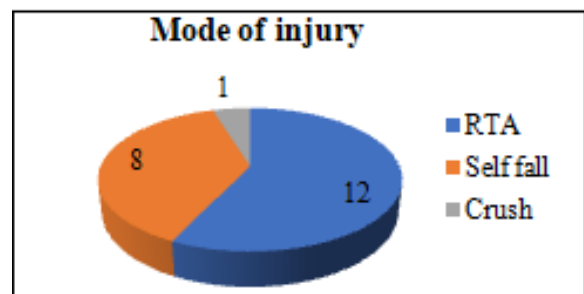
### Side involved

With about 11 and 10 patients with the right and left sides involved respectively both sides appear to be equally involved. The data is shown in the graph.



### Mode of injury

Majority of the patients sustained injury due to RTA. The various modes of injury and the number of patients are shown in the graph.



## 5. Post- Operative Care

Patients were allowed ankle and toe mobilization immediately after the pain subsided. Drains were removed on the 3<sup>rd</sup> post-operative day. Strict limb elevation was maintained until five days from surgery. Non weight bearing crutch walking was allowed from then on. The limbs were maintained in below knee slabs where the patient had associated injuries in the lower limbs. Patients above 50 years were administered with Low Molecular Weight Heparin for three days post operatively. Sutures were removed around the 14<sup>th</sup> day after inspection of the wound. Patient was then discharged from hospital. Outpatient physiotherapy was instituted.

### Follow up

Partial weight bearing was started from 1 month post-operatively. Patients were followed up for a minimum period of 10 weeks. Patients were assessed once in 3 weeks

**Relationship between the mode of the injury and the fracture pattern.**

Among the 21 patients, 15 had extra-articular fractures and 6 intra-articular fractures. Two were compound fractures and 7 patients had associated injuries. This shows that RTA was the major cause for intra-articular fractures.

The following table shows the nature of the injuries and the number of patients.

Fracture pattern	Total No. of patients	No. of patients due to RTA	No. of patients due to Fall	No. of patients due to Crush injury
Extra-articular fractures	15	8	7	
Intra-articular fractures	6	5	-	1
Compound fractures	2	1		1
With associated injuries	7	4	2	1

**Time from injury to surgery**

Patients without any soft tissue complications were operated early and surgery was delayed for those with severe soft tissue damage. Surgery was performed only after the soft tissue status was stable. The table represent the total number of patients and time duration before surgery.

Days	No. of patients	%
<4	5	23.8
4-8	11	52.4
>8	5	23.8

**7. Results**

**Time to union**

85% of the fractures united within 16 weeks with an average of 15.7 weeks. Two delayed unions were observed in patients with compound and intra-articular fracture. The other one was also observed, and to be due to overzealous traction in the limb prior to fixation resulting in distraction at the fracture site. This can be corrected by maintaining apposition at the fracture sites during surgery. But all fractures united at nine months.

Weeks	No. of patients	%
10	2	9.52
11	1	4.76
12	4	19
14	4	19
16	7	33.33
22	2	9.52
38	1	4.76

The following table and graph show the number of patients and time to union.

**Relationship of angular deformities to fibular fixation**

Fibular fractures were present in 20 patients out of the 21 in our study group. We fixed the fibulas in 6 patients for whom there was severe displacement and fracture at the level of the syndesmosis. Though we did not have any clinical

angulations in the immediate and late post-operative period, we had 2 patients with radiological angulations. One patient had 10 degrees of varus, and the other had 10 degrees of recurvatum. Both the patients belonged the group in which the fibula was not fixed. The functional outcomes of both the patients were excellent. None of patients in whom the fibula was fixed experienced radiological or clinical angulations.

Description	No. of patients	%
Patients with fibula fractures	20	95.23
Fibula fractures fixed	6	28.6
Clinical angulations	0	0
Radiological angulations	2	9.5
Angular deformities with fixed fibulas	0	0
Angular deformities with fibula not fixed	2	14

**Movements of the ankle at union**

18 (86%) patients had satisfactory ankle movements leading to normal walking or a minimal limp. The minimal limp was due to some amount of ankle stiffness in the elderly and diabetics. This improved with physiotherapy. 3 (14%) patients had ankle stiffness which produced limping at 22 weeks. This reduced to 2 at 32 weeks, one due to prolonged immobilisation and one due to intra-articular nature of the fracture.

The amount of plantar flexion, dorsiflexion and the number of patients are discussed below.

**Plantar flexion**

Degrees	No. of patients	%
>30 degrees	13	61
11 to 30 degrees	7	33.33
0 to 10 degrees	1	4.8

**Dorsiflexion**

Degrees	No. of patients	%
>15 degrees	11	52.4
11 to 15 degrees	8	38.1
0 to 10 degrees	2	9.5

**Time to full weight bearing**

18 (86%) patients with normal bone union were allowed full weight bearing at or before 18 weeks. The other 3 patients (14%) were allowed full weight bearing at or before 39 weeks.

The table and graph show the number of patients and the time taken to allow full weight bearing **Final outcome**

19 (90%) patients had good and excellent results with fracture union at 23 weeks. Fair results were observed in two patients. One was due to the crushing injury producing associated injuries in the foot, and another due to old age and prolonged immobilisation. The grading was based on Tenny and Weiss scoring criteria for the ankle.



Result	No. of patients	%
Excellent	12	57
Good	7	33.33
Fair	2	9.5
Poor	-	0

### Complications

We had 2 cases with implant impinging the skin for which we performed implant removal at 18 months. 2 patients had ankle stiffness, one due to prolonged immobilization and one intra-articular fracture. We did not experience any infection or wound breakdown in our study.

### 8. Discussion

Minimally invasive locking plate osteosynthesis, as used with our 21 patients, may permit a further advancement in this field of trauma surgery. Redfern et al. and Borg et al. reported good results for MIPPO using closed, indirect reduction and contoured dynamic compression plates for distal tibial fractures. Our study included similar numbers of patients; however we have focused upon fracture healing, need of fibular fixation and complications encountered with regards to our minimally invasive fixation technique.

The management of distal tibia fractures can be challenging because of the scarcity of soft tissue, their subcutaneous nature, and poor vascularity. The surgical treatment of a distal tibial fracture must achieve the necessary amount of mechanical stability without impairing the natural biology (callus formation). The distal tibia is covered only by a very thin layer of soft tissue, so that the treatment of distal tibial fractures is demanding, and complications occur frequently. The fractures are often displaced, so that surgical treatment is inevitable.

Locking plates have the biomechanical properties of internal and external fixators, with superior holding power because of fixed angular stability through the head of locking screws, independent of friction fit. Minimally invasive plating techniques reduce iatrogenic soft tissue injury and damage to bone vascularity, in addition to preserving the osteogenic fracture hematoma. Concomitant fibular fractures should be stabilized with a plate as early as possible, thereby increasing the stability of the tibial reduction, facilitating achieving the correct alignment of the tibia, and preventing a loss of the limb length, as we can show in our patients. We had 20 fibula fractures out of the 21 patients, out of which 6 were fixed. Though we did not have any clinical deformities and the functional outcome was excellent, there was 10 degrees of varus in one and 10 degrees of recurvatum in one. Syndesmotic fractures were fixed. Bridging plate osteosynthesis permits micromotion between the individual fragments, where by the healing process is stimulated, by the formation of callus. The implant selected must be of adequate length to achieve bridging of the fracture site. We preferred to use lengthier plates with minimal cortical purchases. We also had a criterion of having minimal of 4 cortical purchases on either sides of the fracture. In the osteosynthesis we performed, at least three holes at the fracture site were always left unoccupied by screws; plate failure did not occur in any of our cases.

Nevertheless, despite bridging plate osteosynthesis and careful attention to the soft tissues, ankle stiffness and/or delayed unions were observed in 3 of 21 patients which united at 30 weeks. An analysis of these cases revealed a common aetiological factor which was A3, B3 and C3 in AO/OTA '43', and old age with associated injuries. We did not experience any infection or skin breakdown during our study.

### 9. Summary

A total of 21 patients were taken up for study. The age of patients in the study ranged from 18 to 65 Years with an average of 44.42 years at the time of surgery. Among 21 patients 12 were males and 9 were female patients showing a male preponderance. With about 11 and 10 patients with the right and left sides involved respectively, both sides appear to be equally involved. Majority of the patients sustained injury due to RTA. Among the 21 patients, 15 had extra-articular fractures and 6 intra-articular fractures. Two were compound fractures and 7 patients had associated injuries. Intra-articular fractures occurred mainly due to RTA. Patients without any soft tissue complications were operated early and surgery was delayed for those with severe soft tissue damage. Surgery was performed only after the soft tissue status was stable.

85% of the fractures united within 16 weeks with an average of 15.7 weeks. Two delayed unions were observed in patients with compound and intra-articular fracture. Another one was also observed, and to be due to over zealous traction in the limb prior to fixation resulting in distraction at the fracture site. This can be corrected by maintaining apposition at the fracture sites during surgery. But all fractures united at eight months. 18 (86%) patients with normal bone union were allowed full weight bearing at or before 18 weeks. The other 3 patients (14%) were allowed full weight bearing at or before 30 weeks. 18 (86%) patients had satisfactory ankle movements leading to normal walking or a minimal limp.

90% of patients did not have or had <5 degrees of angulation at union. One patient had 10° of varus and one had 10° of recurvatum but with no clinical deformity. Both of these patients belonged to the group of 14 patients where the fibula was not fixed. The functional outcomes in both the patients were excellent. We experienced delayed unions in 3 patients possibly due to excess traction intra-operatively and due to comminution. We did not have any wound infection or skin breakdown during our study. We had 2 cases with implant impinging the skin for which we performed implant removal at 18 months. A minimal limp was observed due to some amount of ankle stiffness in the elderly and diabetics. This improved with physiotherapy. 3 (14%) patients had ankle stiffness which produced limping at 22 weeks. This reduced to two at 30 weeks, one due to prolonged immobilization and one intra-articular fracture.

Based on Tenny and Weiss scoring criteria for the ankle 19 patients (90%) had good and excellent results at 22 weeks with fracture union. Fair results were observed in 2 patients. One was due to the crushing injury producing associated

injuries in the foot, and another due to old age and prolonged immobilisation.

## 10. Conclusion

Minimally invasive locking plate osteosynthesis aims to reduce surgical tissue trauma and help preserve the periosteal vascular integrity and osteogenic fracture haematoma. We have strived to use this as a biomechanically sound method of biological plating for treating closed and open, Peri-articular fractures of the distal tibia.

Based on our study, good and excellent results were obtained in 90% of the cases. 2 fair results were attributed to the crushing nature of the injury in one patient and old age with delayed union in another. Subjects in whom the fibula was fixed did not have any angulation at union. Ankle stiffness was attributed to old age, diabetes, associated injuries and intra-articular fractures which will improve with early mobilization and physiotherapy.

We thus conclude that the use of locking compression plate for intra and extra articular fractures of the distal tibia through minimally invasive technique along with fibular fixation is safe and effective.

## References

### Anatomy

- [1] Greys textbook of anatomy.
- [2] Netter's atlas of anatomy.

### Biomechanics of lcp

- [3] Egol KA, Kubiak EN, Fulkerson E, Kummer FJ, Koval KJ. Biomechanics of locked plates and screws. J Orthop Trauma. 2004 Sep;18(8):488-93.
- [4] Wagner M. General principles for the clinical use of the LCP. Injury. 2003 Nov; 34 Suppl 2: B31-42.

### Classifications

- [5] Rockwood and Green's fractures in adults.
- [6] AO principles of fracture fixation.
- [7] Campbell's operative orthopaedics. Role of fibular fixation.
- [8] Paul M. Morin, Rudolf Reindl, Edward J. Harvey, Lorne Beckman, and Thomas Steffen. Fibular fixation as an adjuvant to tibial intramedullary nailing in the treatment of combined distal third tibia and fibula fractures: a biomechanical investigation. Can J Surg. 2008 February; 51(1): 45-50.
- [9] R. Varsalona and G. T. Liu. Distal tibial metaphyseal fractures: the role of fibular fixation. Strategies Trauma Limb Reconstr. 2006; December; 1(1): 42-50.
- [10] Helfet DL, Shonnard PY, Levine D, Borrelli J Jr. Minimally invasive plate osteosynthesis of distal fractures of the tibia. Injury 1997;28 Suppl 1:A42-8. Percutaneous locking plates for fractures of the distal tibia: our experience and a review of the literature.

- [11] J. Bone joint surg br. 2012; vol. 94-b: no. supp xxxvii 519.
- [12] T.J. Bonner, S.M. Green and I.A. mcmurty. A biomechanical comparison of different screw configurations in distal tibial locking plates. j bone joint surg br. 2012; vol. 94-b: no. supp xv 20.
- [13] N Hosangadi, K Shetty, J Nicholl and B Singh. Tibial locking plates for fractures of distal tibia using mipo technique – results & complications. J Bone Joint Surg Br 2012; vol. 94-b: supp xvi 18