International Journal of Science and Research (IJSR)
ISSN (Online): 2319-7064
Index Copernicus Value (2013): 6.14 | Impact Factor (2015): 6.391

Evaluating the Shape of Foramen Magnum and Overlapping of Occipital Condyle on the Foramen

Faazila Fathima[1], K. Yuvaraj Babu[2]

[1]IBDS, Saveetha Dental College and Hospitals, Saveetha University, Chennai-600 077, India

[2]Assistant Professor, Department of Anatomy, Saveetha Dental College and Hospitals, Saveetha University, Chennai-600 077, India

Abstract: ***Objective**: The objective of this study is to conduct the morphometric analysis of the foramen magnum (FM) and overlapping of occipital condyles on it and also determination of shape of foramen magnum. **Method**: 53 dried human skulls of unknown age and sex were examined from department of Anatomy, Saveetha Dental College and Hospital. Foramen magnum were examined macroscopically for their different shapes. Anteroposterior and transverse diameters was measured using a manual verniercalliper. Also the presence of overlap of occipital condyles was observed. **Result**: The various shapes of foramen magnum observed was egg, oval, hexagonal, pentagonal, circular. Egg shaped foramen was observed in 35.85%, oval shaped foramen in 26.42%, hexagonal shaped in foramen magnum in 20.75%,circular/round shaped foramen in 13% and pentagonal shaped foramen in 3.77%. In 72% of the skull the occipital condyles were observed to protruded into the foramen magnum. The mean antero-posterior and transeverse diameters of the foramen magnum was recorded as 3.822cm and 3.515cm respectively. The mean area of FM was recorded as 11.025 cm2. **Conclusion**: Morphometric analysis of the foramen magnum can be used as supportive findings in estimation of sex of fragmented in- complete or damaged dry human skulls. The knowledge of dimensions of the FM also helpful in determination of malformation (Arnold Chiari Syndrome) and in transcondylar approach to make a safe occipital condyle resection. Though the present study has a limitations as the age and sexes of the skull were not determined, this study may provide an important reference and the measurement may be used as a data for the description of morphological variant of FM.*

Keywords: Foramen magnum, overlapping of occipital condyle, anteroposterior diameter, transverse diameter

1. Introduction

A fundamental knowledge of the normal anatomy of the cranial base, especially the foramen magnum and associated structures, is important to the clinician for accurate diagnosis and treatment of various diseases (1). The foramen magnum is a large opening in the occipital bone of the human skull. This foramen is the largest bony foramen of the skull (2). The foramen magnum is found in the most inferior part of the posterior cranial fossa (3). It is traversed by vital structures. It contains the lower end of the medulla oblongata, meninges, vertebral arteries and spinal accessory nerve; the apical ligament of the dens and the tectorial membrane pass through it to attach to the internal basiocciput.(4) In the midline, the anterior margin is the basion and the posterior margin is the opisthion. Foramen magnum dimensions can be used in the field of forensic identification and anthropology for determination of the gender of the human skulls(5,6,7). The foramen magnum however, shows different morphology in each individual skull, and reportedly, it has different outlines of shapes ranging from round to polygonal or even irregular(8). Anteriorly, the margin of the foramen magnum is slightly overlapped by the occipital condyles which project down to articulate with the superior articular facets on the lateral masses of the atlas(9).

The occipital condyles represent the cranial portion of the craniocervical junction. Craniovertebral junction refers to the occipital bone that surrounds foramen magnum and atlas and axis vertebrae(10).Anomalies of Craniovertebral junction are of interest not only to an anatomist but also to the clinicians because many of these deformities produce clinical symptoms. The occipital bone is the main site of these variations(11).

Distance between anatomic landmarks and the sites where a number of vital structures have their entrance or exits are very important for clinical application. The measurements are helpful for neurosurgeons for performing lateral transcondylar surgical approaches for reaching lesions in the middle and posterior part of cranial base(12). The hypoglossal canal, directed laterally and slightly forwards, traverses deep to each condyle(13).So, most suitable surgical techniques are to be established for a careful planning mainly based on the foramen magnum size to refrain from any neurological injury(14).

The brainstem is vulnerable to compression at two critical sites, which are determined by the neuroanatomical relationship of the meningeal tentorium and foramen magnum to the cerebral hemisphere (supratentorial) and brain stem (infratentorial)(15).

Recent studies report that morphometry is a fast and efficient method for the evaluation of morphological characteristics, such as ethnicity, gender, age, genetic factors, dietary habits, and regional variations which can alter the shape and size of bone structures. These aspects are significantly important in determining the anthropometric changes between different populations and genders(16,17).

Hence, this study aims to conduct the morphometric analysis of the foramen magnum and overlapping of occipital condyles on it and also determination of shape of foramen magnum.

Licensed Under Creative Commons Attribution CC BY

2. Method

53 dried human skulls of unknown age and sex from Department of Anatomy, Saveetha Dental College was examined for the present study.

The parameters measured included the following:

1) Foramen magnum length (FML)/ Antero- posterior diameter: Maximum straight anteroposterior diameter from basion (median point on the anterior margin of the foramen magnum) to opisthion (median point on the posterior margin of the foramen magnum).
2) Foramen magnum width (FMW)/ Transverse diameter: Maximum straight transverse diameter between two points of the foramen magnum on most laterally placed margins.
3) Area of foramen magnum (FMA): The area of Foramen magnum was calculated using formula derived by Radinsky (18). Radinsky's(18)Formula (FMA): 1/4 X 3.14X FML X FMW
   Where, FML = Foramen magnum length and FMW = Foramen magnum width.
4) The different shapes of the foramen magnum were noted macroscopically and classified as oval, egg, pentagonal, hexagonal and circular.

The anteroposterior and transverse diameters were measured by using manual verniercalliper.

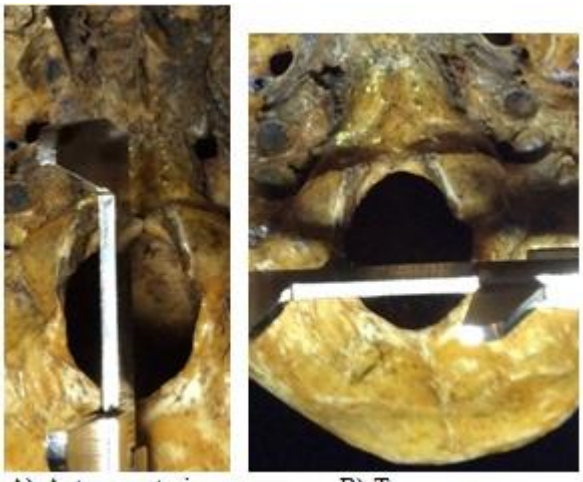

A) Anteroposterior B) Transverse

Figure 1: Showing measurements undertaken in the foramen magnum using verniercalliper A) Anteroposterior B) Transverse

3. Result

For Shape of foramen magnum:



Oval Hexagon Circular Pentagon Egg

Figure 2: Shows the different shapes of foramen magnum

The various shapes of foramen magnum observed was egg, oval, hexagonal, pentagonal, circular. Egg shaped foramen was observed in 35.85%, oval shaped foramen in 26.42%, hexagonal shaped in foramen magnum in 20.75%,circular/round shaped foramen in 13% and pentagonal shaped foramen in 3.77%. The different shapes of foramen magnum observed is shown in figure2 .Figure 3 shows the percentage of occurrence of different shapes of foramen magnum.

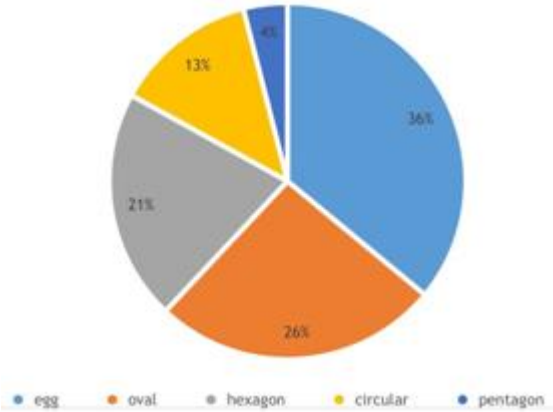

Figure 3: Shows the percentage of occurrence of different shapes magnum in 53 dry skulls.

For Measurements Undertaken in the foramen magnum:
The mean anteroposterior and transverse diameters of the foramen magnum was recorded as 3.822cm and 3.515cm respectively(table 1). The mean area of FM was recorded as 11.025 cm2(table1).

Table 1: Show mean, range measurements of length, width and area of foramen magnum

	LENGTH(in cm)	WIDTH(in cm)	AREA(in cm2)
MEAN	3.8	3.5	11.02
MAXIMUM	5.3	5.2	21.21
MIMIMUM	2.3	2.0	3.61

For Overlapping of occipital condyles:
In 72% of the skull the occipital condyles were observed to protruded into the foramen magnum(Figure4).Figure 5shows A) No overlapping of occipital condyles and B) Overlapping of occipital condyles respectively.

Licensed Under Creative Commons Attribution CC BY

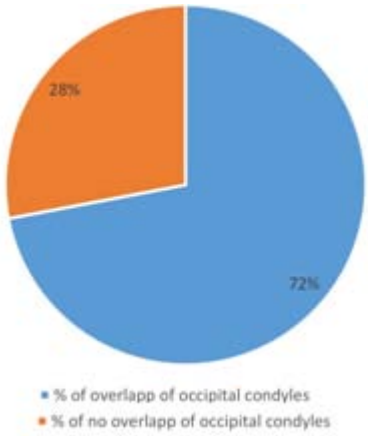

Figure 4: Shows the percentage of overlapping of occipital condyles on foramen magnum in the dry skulls.

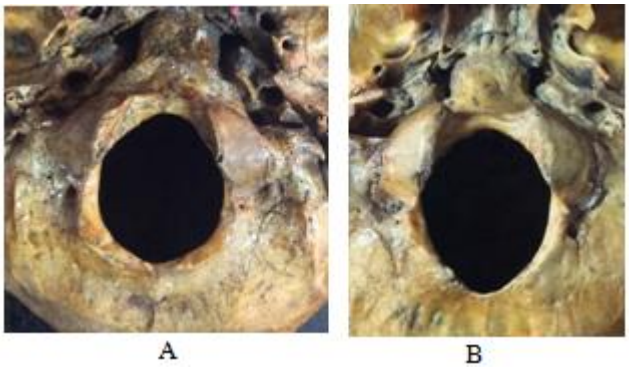

Figure 5: Shows A) No overlapping of occipital condyles and B) Overlapping of occipital condyles respectively.

4. Discussion

The irregular shape of the foramen is seen with the developmental anomalies of the bones and the soft tissues at the craniovertebral junction (19).The shape and morphological variations of foramen magnum are important in neurological interpretation.(20). In table 2 the percentage of different shapes of foramen magnum observed by authors in their study and the percentage observed in the present study is compared. Zaidi et al (21) observed the oval shape in 64% and Sindel et al (22) observed the oval shape in 18.9% of the skulls.

In 72% of the cases the occipital condyle were protruded in to the foramen magnum. This type of morphology can lead to compression of the vital structures passing through the FM.(20)

It is of keen interest to study the morphometry of the FM, from a descriptive and topographical point of view (23).In this study the results were 5.3cm and 5.2cm as maximum anteroposterior and transeverse diameters respectively. The minimum values of anteropostior and transverse diameters are 2.3 cm and 2 cmrespectively. The mean area of the FM was 11.02cm2 in our study which was more than the observations made by Teixeria WR (24) which was 963.73mm2.

The anatomic diameter have been reported to be about 3.82cm for the A-P diameter and 3.51cm for the transeverse diameter. In table 3 the comparison of anteroposterior and transverse diameter of the present study with the study done by other authors is show. These values are similar to F. Burdan(25) and Shikha Sharma(20) for anteroposterior and for transverse diameter it was similar to Shikha Sharma(20) (table3). Uthman et al (26) reported that the foramen magnum area is the best discriminant that could be used to study sexual diamorphism.

The data obtained from the present study was compared with the data reported by other authors. After the comparision, we observed that our findings are almost similar to that of Burdan et al (25).

	ZAIDI et al.	MURSHED et al.	SHIKHA et al.	PRESENT STUDY
Morphological variants of Foramen magnum	Percentage	Percentage	Percentage	Percentage
OVAL	64%	8.1%	16%	26%
HEXAGON	24.5%	17.2%	8%	21%
CIRCULAR/ROUND	0.5%	21.8%	22%	13%
PENTAGON	7.5%	-	8%	4%
EGG	-	-	16%	36%

Table 2 : Shows the comparison of percentage of different shapes of foramen magnum observed by authors in their study to the percentage observed in the present study.

And on comparing the area of FM, was found almost similar to Shikha Sharma (20) which was 970.57mm2 observed by Shikha et al and in the present study it was 11.025cm2.

Licensed Under Creative Commons Attribution CC BY

Table 3: Show the comparison of anteroposterior and transverse diameter of the present study with the study of other authors

AUTHORS	ANTEROPOSTERIOR DIAMETER	TRANSVERSE DIAMETER
Schmeltzer et al 1971	35mm	30mm
Catalina-Herrera 1987	35.2mm	30.3mm
Wanebo and Chicine 2001	36+-2mm	32+-2mm
Murshed et al 2003 (25)	35.9+-3.3mm	30.4+-2.6mm
Tubs et al 2010	31mm	27mm
Burdan et al 2012 (27)	37.06mm	32.98mm
Shikha et al 2015	38.76mm	33.44mm
Present study 2016	3.82cm	3.51cm

5. Conclusion

The mean anteroposterior diameter of FM was 3.82cm and the mean transeverse diameter was 3.51cm. These parameter should be taken during craniovrtebral and cervical spine surgical procedures. (20)Morphometric analysis of the foramen magnum can be used as supportive findings in estimation of sex of fragmented in- complete or damaged dry human skulls. The knowledge of dimensions of the FM also helpful in determination of malformation (Arnold Chiari Syndrome) and in transcondylar approach to make a safe occipital condyle resection(20). Though the present study has a limitations as the age and sexes of the skull were not determined, this study may provide an important reference and the measurement may be used as a data for the description of morphological variant of FM. The FM is taken as the anatomical landmark in transcondylar approach for a safe occipital condyle resection (27). The present study illustrates the morphometric data and the variations in the morphology of the FM with emphasis on their clinical implications.(20) This study is also helpful in medicolegal cases for the identification of unknown individuals.(20) With the advancement of the CT and MRI scans as investigation the anatomy of the FM becomes interesting In the field of medicine (20).

References

[1] Gautam Kanodia, Vijay Parihar, Yad R Yadav, Pushp R Bhatele and Dhananjay Sharma. Morphometric analysis of posterior fossa and foramen magnum. J Neurosci Rural Pract. 2012; 3(3): 261–266.
[2] Avci E, Dagtekin A, Ozturk AH et-al. Anatomical variations of the foramen magnum, occipital condyle and jugular tubercle. Turk Neurosurg. 2010;21 (2): 181-90.
[3] Drake. Gray's Basic Anatomy: with STUDENT CONSULT Online Access, 1e (Grays Anatomy for Students). Churchill Livingstone.
[4] Anil Kumar , Mitesh Dave , Sanam Anwar, MORPHOMETRIC EVALUATION OF FORAMEN MAGNUM IN DRYHUMAN SKULLS.International Journal of Anatomy and Research, Int J Anat Res 2015, Vol 3(2):1015-23. ISSN 2321- 4287.
[5] Tanujkanchan, anadigupta, and kewalkrishan. Craniometric analysis of foramen magnum for estimation of sex. International journal of medical, Health, biomedical and pharmaceutical engineering. 2013; 7(7): 111-113.
[6] Suazo,G.I.C.Russo,P.P.,Zavando,M.D.A.;&Smith, R. L. Sexual dimorphism in the foramen magnum dimensions. Int.J. Morphol., 2009; 27(1): 21-23.
[7] M.J. Thali. Sex determination from the foramen magnum. Journal of forensic radiology and imaging. 2013; 1(4): 186-192.
[8] Vaseemraja G. Shaikh, Pramod. R. Kulkarni,A Morphological study of Shapes, Overlapping of Occipital Condyles and the Anterior Tubercle of Foramen Magnum in Human Skull with Comparison in Adolescent, Adult and Foetal age and in Males and Females.International Journal of Anatomy and Research, Int J Anat Res 2014, Vol 2(4):797-05. ISSN 2321- 4287.
[9] Standarding S. Gray's anatomy. The anatomical basis of clinical practice. 39th ed. London: Elsevier Churchill Livingstone; 2005: 460.
[10] Menezes AH: Congenital and acquired abnormalities of Craniovertebral junction Youmans Neurological surgery 5th edition volume 3.Philodelphia, WB Saunders, 2004; 3331-3344.
[11] Prasada Rao PVV. Median (Third) Occipital Condyle. Clinical Anatomy 2002; 15: 148- 151.
[12] DR. SHWETA SOLAN,Morphmetric Analysis of Foramen Magnum and Occipital Condyles in Human Skull Among Eastern Population - A Case Study.Volume : 5 | Issue : 9 | September 2015 |ISSN-2249-555X.
[13] SanjuktaSahoo, Sanjay Kumar Giri, Sitansu K. Panda, Priyambada Panda, Mahesh Chandra sahu, ChinmayeeMohapatra, Morphometric Analysis of the Foramen Magnum and the Occipital condyles.Int. J. Pharm. Sci. Rev. Res., 33(2), July – August 2015; Article No. 42, Pages: 198-204 ISSN 0976 – 044X.
[14] Muthukumar N, Swaminathan R, Venkatesh G, Bhamumathi SP, Amorphometric analysis of the foramen magnum region as it relates to transcondylar approach. Actaneurochir (Wien), 147(8), 2005, 889-895.
[15] Bozbuga M, Ozturk A, Bayraktar B, Ari Z, Sahinoglu K, Polat G, Surgical anatomy and morphometric analysis of the occipital condyles and foramen magnum. Okajimas Folia AnatJpn, 75, 1999, 329-334.
[16] HUMPHREY, LT., DEAN, MC. and STRINGER, CB. Morphological variation in great ape and modern human mandibles. Journal of Anatomy. 1999, vol. 195, p. 491-513. (part 4).
[17] PRADO, FB. and CARIA, PHF. Comparaciones morfol. gicas entre las mandíbulas de brasileños y de poblaciones de otros continentes. International Journal of Morphology. 2007, vol. 25, no. 2, p. 323-327.

Licensed Under Creative Commons Attribution CC BY

[18] RadianskyL.Relative brain size a new measure. Science. 1967;155:836-838.
[19] Furtado S V, Thakre D J, Venkatesh P K, Reddy K, Hedge A S. Morphometric analysis of foramen magnum diamensions and intracranial volume in pediatric chiari I malformation. ActaNeurochir (Wein) 2010;152:221-227.
[20] Shikha Sharma, Anil Kumar Sharma , Bhawani Shankar Modi , Mohd. Arshad.MORPHOMETRIC EVALUATION OF THE FORAMEN MAGNUM AND VARIATION IN ITS SHAPE AND SIZE: A STUDY ON HUMAN DRIED SKULL,International Journal of Anatomy and Research, Int J Anat Res 2015, Vol 3(3):1399-03. ISSN 2321- 4287.
[21] Zaidi S H, DayalS S. Variations in the shape of the foramen magnum in Indian skulls. AnatAnz Jena. 1988;167:338-340.
[22] Sindel M, Ozkan O, Ucar Y,et al. Foramen magnum'un anatomic varyasyonlari. Akd U Tip FakDergisi. 1989;6:97-102.
[23] Murshed KA, Cicekcibasi AE, Tuncer I. Morphometric evaluation of the foramen magnum and variations in its shape:A study on computerised tomographic images of normal adults.Turk J Med Sci. 2003;33:301-306.
[24] Teixeria WR. Sex identification utilizing the size of Foramen magnum.Am J ForensicMedpathol. 1983;3:203-206.
[25] F. Burdan, J. Szumi O, J. Walocha,L.Klepacz,B. Madej, W. Dworzanski, R. Klepacz, A. Dworzanska, E. Czekajska-Chehab, A. Drop. Morphology of the foramen magnum in young Eastern European adults.Folia Morphol.2012;71(4):205-216.
[26] Uthman AT, Rawi NA and Timimi JA. Evaluation of foramen magnum in gender determination using helical CT Scanning.DentomaxillofacialRadiol. 2012;14:197-202.
[27] Barut N, kale A, TuranSuslu H,Ozturk A, Bozbuga M, Sahinoglu K: Evaluation of the bony landmarks in trans condylar approach. Br J Neurosurg. 2009;23:276-281.

Licensed Under Creative Commons Attribution CC BY