

# An Unexpected Presentation of Child Abuse Case Report and Review of the Literature

Mosa Y. Hakami<sup>1</sup>, Alaa A. Hakami<sup>2</sup>, Magda A. Khazbak<sup>3</sup>

<sup>1</sup>Senior Pediatric Program Resident, Saudi Commission for Health Specialties, Level 4 in Pediatric Department of King Fahd Central Hospital – Jazan at KSA

<sup>2</sup>Senior Pediatric Program Resident, Saudi Commission for Health Specialties, Level 4 in Pediatric Department of King Fahd Central Hospital – Jazan at KSA

<sup>3</sup>Consultant Pediatrician, Saudi Commission for Health Specialties, in Pediatric Department of King Fahd Central Hospital – Jazan at KSA

**Abstract:** *An instance of child abuse discovered accidentally is presented. The step-wise patient evaluation, treatment, protection, reporting of findings, family counseling, legal intervention, and final case resolution are reviewed. The interaction of multiple disciplines and skilled professionals is necessary for positive resolution of all issues. Child Abuse has been defined as an act, or failure to act, on the part of a parent or caretaker that results in the death, serious physical or emotional harm. The clinical presentation of our case with convulsions and fever was a clue to suspect meningoencephalitis. The recurrence of this condition associated with multiple hemorrhagic foci on the brain and many risk factors for non-accidental injuries make shaken baby syndrome with post traumatic epilepsy is the diagnosis by exclusion, which was an unexpected presentation of child abuse.*

**Keywords:** infectious disease, post traumatic epilepsy, child abuse

## Abbreviations

ICH: Intracranial hemorrhage  
CT: Computed tomography  
MRI: Magnetic resonance imaging  
MRA: Magnetic Resonance Angiography  
PICU: Pediatric intensive care unit  
UNCRC: The United Nations Convention on the Rights of the Child  
WHO: The World Health Organization,  
(CDC): Centers for Disease Control and Prevention  
CSF: Cerebrospinal fluid  
ICP: Intracranial pressure

## 1. Introduction

In the absence of known accidental mechanisms or medical causes, children with intracranial hemorrhage (ICH), might be suspected victims of child abuse. In such situations, physicians commonly suspect another medical condition as a possible cause. In addition, because of the legal proceedings associated with cases of potential abuse, physicians might feel compelled to rule out any theoretical possibility of a medical explanation for the child's findings [1-3]

The World Health Organization [WHO] distinguishes four types of child abuse as physical, sexual, or psychological mistreatment or neglect of a child or children, especially by a parent or other caregiver. It may include any act or failure to act by a parent or other caregiver that results in actual or potential harm to a child. [4] The United Nations Convention on the Rights of the Child, or UNCRC, sets out the rights of

children, aged 0 to 18 years, and the responsibilities of parents, governments and children themselves to fulfill those rights. [5-7]

We, here in describe a case of child abuse that was misdiagnosed as dengue fever encephalitis.

## 2. Case Summary

One year ago, a Yemeni infant, was referred from peripheral hospital after two weeks of admission there as case of meningoencephalitis with history of fever, convulsions and change of level of consciousness. physical examination showed drowsy, irritable infant, pupils 2:2 mm bilateral normally reactive to light, hypotonia, hyporeflexia. Other systemic examination was unremarkable. Patient was admitted to PICU at KFCH-Jazan, intubated, sedated on ICP prophylaxis protocol, and treated as a case of hemorrhagic encephalitis secondary to dengue fever for 21 days without significant improvement. CT brain showed: Biparietal hyperdense lesion with significant surrounding edema with mild extension into both temporal lobes suggesting hemorrhagic encephalitis, meningoencephalitis, venous infarction, shaken baby syndrome, or infarction with hemorrhagic transformation. MRI brain: bilateral thalamic abnormal intensities (T1 hypo- and T2 hyper intensities). prominent white matter edema around the bilateral parietal lesions. Bilateral cortical / gyriiform T1 hyperintensities are seen suggestive of hemorrhage. Bilateral regional subcortical T1 hyperintensities are also seen more on right side and are also impressive of hemorrhages.

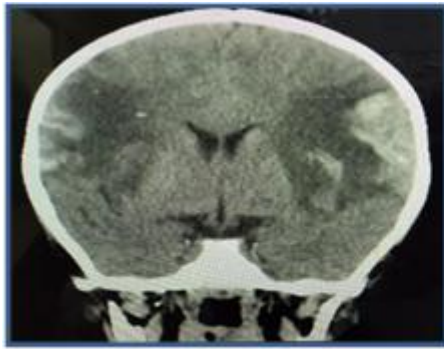


Figure 1: CT brain showed

CT brain showed :Biparietal hyperdense lesion with significant surrounding edema suggest : hemorrhage.

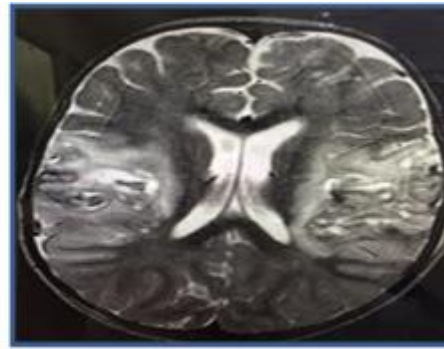


Figure 2: MRI brain showed

MRI brain showed: bilateral cortical hyperintensities suggestive of hemorrhage

Laboratory investigations showed :HGB:7.8 g/dL, RBC:4.62  $\times 10^{12}/L$ , HCT:28.8%, MCV:62.3fL, MCH:19.3pg, RDW:16.1%, PLT:609 $\times 10^9/L$ , WBC:6.33 $\times 10^9/L$ , coagulation profile: normal, protein C: 102% normal, protein S :80% normal, thrombin time: 17.9 sec iron : 4,UMOL/L TIBC : 43UMOL/L, Hb electrophoresis : HbA : 97% Hb F 1% Hb S:--% HbA2:2% which is normal. Reticulocyte count: 2.02%high, peripheral blood smear microcytic hypochromic with reactive neutrophil and thrombocytosis . Dengue fever IgG: negative, Dengue fever IgM: positive, ESR:20mm/hour, C-RP :negative mg/dl, ALT:21U/L AST:39U/L BUN: 1.6mmol/l creatinin: 27 mmol/l sodium:137 mmol/l potassium : 4.3 MMOL/L, lipid profiles : cholesterol:7.1mmol/l high, triglycerides: 1.8 mmol/l normal HDL-cholesterol :1.5 mmol/l normal, LDL-cholesterol :4.8mmol/l normal.

He was discharged home on anti-convulsants with no compliance on medication by parents.

After 1 year, now he is aged 32 months, patient presented with similar manifestations; fever, focal tonic – clonic convulsions affecting RT upper limb lasting for up to 10 minutes, with up - rolling of eyes, associated with decreased oral intake and decreased level of consciousness. History as mentioned by grand mother, as parents never showed up ,included a mild head trauma after falling from bed a couple of days before admission, according to her. No history of sib death. He lives with his poor family: father, mother and two sibs.

His weight was 10 kg on 5<sup>th</sup> percentile, his height was 88 cm on 25<sup>th</sup> percentile and head circumference was 47 cm on 10<sup>th</sup> percentile. No dysmorphism, impaired

level of consciousness [drowsiness], GCS: 9/15, aphasia no neuro-cutaneous stigmata, Rt hemiparesis, power grade 3/6 Fundus examination: No retinal hemorrhage. Other examination was unremarkable. CT brain showed hyperdense lesions in the leaflet of the tentorium cerebelli with perifocal edema and other two hyperdense lesions in the left parietal region also noted ... hemorrhagic foci, mild effacement of the cerebral sulci with ill defined white and gray matter, may represent mild diffuse cerebral edema, bilateral parietal encephalomalacia . MRI/MRA brain showed left temporoparietal , occipital cortical gyri /T/ posterior corpus callosum with DW/T/ADC restriction with effacement of sulci, in keeping with acute infarction in the territories of left PCA/T/MCA. Left temporal, temporo-occipital gyrus, cortical laminar necrosis with superficial siderosis. Cystic changes (encephalomalacia) with siderosis in the previously described haemorrhagic areas was noted on bilateral frontal gyri/T/ with siderosis sylvian fissure showed (liquified hematoma). Other imaging done: skeletal survey: normal. Abdominal U/S :normal.

Laboratory investigations showed :HGB:9g/dL RBC:4.62 $\times 10^{12}/L$  HCT:28.3% MCV:62.3fL,MCH:19.3pg RDW:16.1% PLT:609 $\times 10^9/L$  WBC:11.77 $\times 10^9/L$ , coagulation profile was normal ANA: negative, HIV: negative, dengue fever IGM: positive, dengue fever IGG: negative, dengue fever NS: negative, immunoelectrophoresis IgA: 0.91 g/L normal, IgM :1.14g/L normal, IgG : 8.29 g/L normal

After few days in hospital , the child became fully conscious but he was apprehensive, irritable, resisting examination and avoiding eye contact with others. We were unable to examine other sibs or to council the parents.

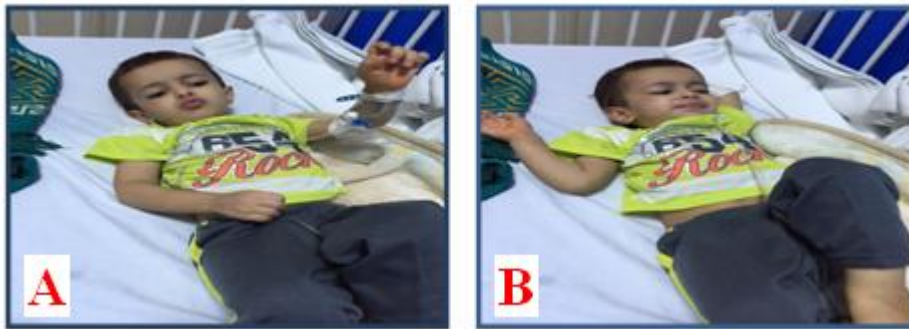

Figure 3 A & B: Our patient (fearful, anxious and depressed)

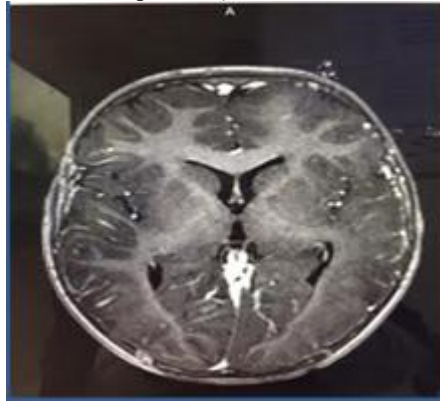

Figure 4: MRA brain

The social worker and physician discussed their findings regarding the reporting of this incident and the relative degree of risk to the child. Taken into account were: the child's age; the psychosocial history.

### 3. Reporting

Telephone and written reports to child protective services were made. These include:

- 1) Demographic information including patient and parent name and address
- 2) Time, day, and date of presentation
- 3) History, including detailed sequence of events, discovery of the injury, and the persons present at the time of injury
- 4) Detailed physical findings, including location, size, color and nature of each individual site
- 5) Results of X ray and laboratory tests
- 6) Conclusion stating that this incident represented non accidental trauma and a potential for re injury to the child .

#### **Family Therapy**

The family was referred to a public assistance social worker for support during periods of financial need.

#### **Consultations**

Neuro – surgery  
Pediatric neurology  
Pediatric hematology  
Pediatric infectious disease  
Ophthalmology  
Psychiatrist  
Social worker  
Child Protection committee

### 4. Discussion

Data from the Centers for Disease Control and Prevention (CDC) and Behavioral Risk Factor Surveillance System corroborate high rates of child abuse. For legal and cultural reasons as well as fears by children of being taken away from their parents most childhood abuse goes unreported and unsubstantiated. [8-10]

This child admitted one year back to PICU as case of meningoencephalitis secondary to dengue fever with history of insignificant trauma, CT-brain findings suggestive of hemorrhagic encephalitis, meningoencephalitis, venous infarction, shaken baby syndrome, or infarction with hemorrhagic transformation. He was discharged after 21 days without significant improvement and post-meningeal sequelae in form of aphasia. After one year, he presented again with same presentation and again hemorrhagic foci on his brain imaging. Dengue fever NS was negative which excluded dengue fever. With this recurrent presentation, it was unlikely to be infectious diseases and many signs suggest non accidental causes of this hematoma ( recurrent presentation, poor socioeconomic status, history of insignificant trauma, in a withdrawn depressed child who was fearful and refused examination during hospitalization, poor compliance on medication at home, intracranial hemorrhage without scalp fractures, absence of vascular malformation, absence of bleeding disorder).

Shugerman et al. reported that 6% of their 93 cases with the diagnosis of child abuse were suspected because of the recurrence of intracranial hemorrhage and the absence of any compatible trauma mechanism related during clinical interview which is a common characteristic of child abuse cases [11-13]

## 5. Conclusion

We here in describe a case of child abuse that was misdiagnosed as dengue fever encephalitis. The incongruence between clinical history and physical findings in child abuse cases defies even the most skilled clinicians. This case reminds us that even though very frequent in our society, child abuse is not the sole cause of incongruence between history and physical exam. Pediatricians should thus always bear in mind the differential diagnosis of this clinical entity.

*The recurrence of intra cranial hemorrhage for no apparent cause, should alert the pediatrician to the possibility of child abuse.*

## References

- [1] Sanger R: Oral facial injuries in physical abuse, in Clinical Management of Child Abuse and Neglect, Sanger R, Brose D, eds. Chicago; Quintessence Pub Co, 1984 pp 37—41
- [2] Evaluating for Suspected Child Abuse: Conditions That Predispose to Bleeding Pediatrics 2013;131:e1357–e1373
- [3] Gardner H. Immunizations, retinal, and subdural hemorrhage: are they related? Med Hypotheses. 2004;64(3):663 138.
- [4] *"Child abuse and neglect by parents and other caregivers"* (PDF). World Health Organization. p. 3. Retrieved 8 March 2016
- [5] Brain and spine injuries in infancy and childhood. In: Barkovich AJ, ed. Pediatric Neuroimaging. 4th ed. Philadelphia, PA: Lippincott Williams & Wilkins; 2005:190–290 139.
- [6] McLean LA, Frasier LD, Hedlund GL. Does intracranial venous thrombosis cause subdural hemorrhage in the pediatric population? AJNR Am J Neuroradiol. 2012; 33(7):1281–1284
- [7] Hymel KP, Abshire TC, Luckey DW, Jenny C. Coagulopathy in pediatric abusive head trauma. Pediatrics. 1997;99(3):371–375
- [8] Talving P, Lustenberger T, Lam L, et al. Coagulopathy after isolated severe traumatic brain injury in children. J Trauma. 2011;71(5):1205–1210
- [9] Boshkov LK. Plasma. In: Goodnight SH, Hathaway WE, eds. Disorders of Hemostasis and Thrombosis, 2nd ed. Lancaster, PA: McGraw-Hill; 2001:495–500
- [10] Sullivan PM, Knutson JF. Maltreatment and disabilities: a population-based epidemiological study. Child Abuse Negl. 2000;24 (10):1257–1273
- [11] Shugerman RP, Paez A, Grossman DC, Feldman KW, Grady S. Epidural hemorrhage: is it abuse? Pediatrics 1996;97:664-668.
- [12] Ewing-Cobbs L, Kramer L, Prasad M, et al. Neuroimaging, physical and developmental findings after inflicted and noninflicted traumatic brain injury in young children. Pediatrics 1998;102:300-307.
- [13] Bach KP, Schouten-van Meeteren AY, Smit LM, Veenhuizen L, Gemke RJ. Intracranial hemorrhages in infants: child abuse or a congenital coagulation disorder? Ned Tijdschr Geneesk 2001;145:809-813.

## Author Profile

**Mosa Yousef Hakami** is a senior pediatric program resident of Saudi Commission for Health Specialties, level 4 in pediatric department of King Fahd Central Hospital – Jazan at KSA.

**Dr. Alaa Abdullah Hakami** is a senior pediatric program resident of Saudi Commission for Health Specialties, level 4 in pediatric department of King Fahd Central Hospital – Jazan at KSA.

**Prof. Magda Khazbak** is a consultant pediatrician at the same department .