

# MRI Study of Level of Termination of Spinal Cord (Conus Medullaris)

Preeti<sup>1</sup>, Manish Chaturvedi<sup>2</sup>

<sup>1</sup>Post Graduate Student, Dept. of Anatomy Gajra Raja Medical College, Gwalior (M.P.), India

<sup>2</sup>Assistant Professor, Dept. of Anatomy Gajra Raja Medical College, Gwalior (M.P.), India

**Abstract:** *The spinal cord is a vital organ of the body. The level of termination of spinal cord (conus medullaris) has been always remained as an area of interest. It is necessary to know the level of termination of spinal cord in order to diagnose a low lying tethered cord in children and important in procedure like spinal anesthesia. In present study MRI of whole spine of 71 adult individuals with age group of 18 years to 65 years of either sex with normal MRI findings were analyzed. In this study we used T1 & T2 weighted sagittal spin echo and SS Myelo MRI sequences of whole spine. Each vertebra was divided into 3 equal portions and the intervertebral disc was defined as a separate region. The position of the conus medullaris were defined as the vertebral segment or intervertebral disc space that will be determined by the line. Max no of spinal cord termination observed around L1 & L2. The present study is an attempt to provide data base for a range of termination of spinal cord. Which is helpful in clinical procedures like lumbar puncture and accurate localization in cranial spinal irradiation & anaesthesiologist practicing regional anaesthesia.*

**Keywords:** Spinal cord, Conus-medullary, Segment, MRI, Termination

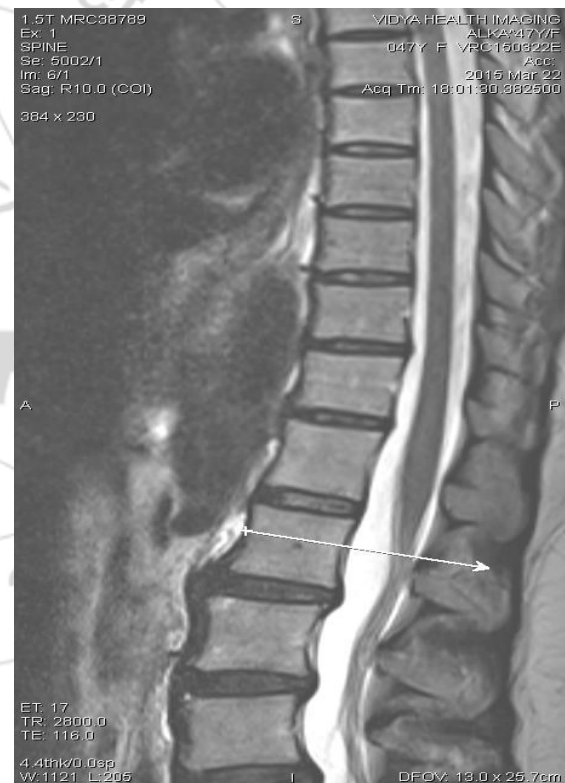## 1. Introduction

The safe and successful performance of a clinical procedure demands a working and specific knowledge of anatomy. The spinal cord is a vital organ that serves as the only communication link between the brain and the various parts of the body. It is vulnerable to traumatic spinal cord injury and various diseases such as tumors, infections, inflammatory diseases and degenerative diseases.[1] The conus medullaris or "medullary cone" is the terminal end of the spinal cord. The level of termination of conus medullaris has been always remained as an area of interest. It is necessary to know the level of termination of medullaris in order to diagnose a low lying tethered cord in children[2] and also important in spinal anaesthesia. It is crucial to point out that in lieu of many publications of conus termination that one accepts that there is no one single normal position of the terminal cord but rather a normal range.[3,4]

Before the invention of modern imaging technique scientists studied the termination of spinal cord and dural sac by actually dissecting cadavers and it is widely accepted that the conus medullaris terminates in the lower third of L1 vertebra[5,6] After the invention of MRI, scientists found that there is wide range of termination of spinal cord and dural sac. Advantages of MRI are it identifies possible disorders and provide wide range in live healthy subjects. Now MRI is the procedure of choice for examination of spinal cord. The present study will be an attempt to provide data base for a range of termination of spinal cord in Indian population on MRI.

## 2. Materials and Methods

In present study MRI of whole spine of 71 adult individuals with age group of 18 years to 65 years of either sex with normal MRI findings were analyzed.



**Figure 1:** Picture showing termination of spinal cord.

And Patients with intervertebral disc diseases and other abnormalities of vertebral column like kyphoscoliosis & spinal cord were excluded from study. Collection of MRI spine film and data of cases were done from Vidhya Health Imaging Centre, Gwalior. MRI of whole spine of patients will be performed on Siemens essenza 1.5 Telsasuper can 16 channel machine. In this study we used T1 & T2 weighted sagittal spin echo and SS Myelo MRI sequences of whole spine on DICOM viewing software in computer with patient in supine position to localize the tip of conus medullaris. Each vertebra was divided into 3 equal portions (upper, middle and lower thirds respectively) and the intervertebral

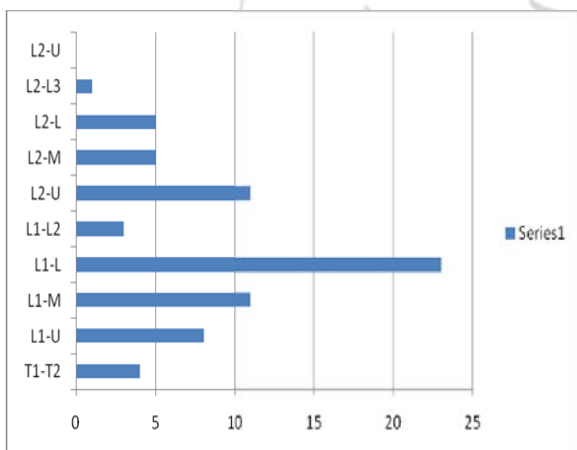
disc was defined as a separate region.[3] The position of the conus medullaris were defined as the vertebral segment or intervertebral disc space that will be determined by the line. This was done by extending a horizontal line will be drawn from most distal part of spinal cord & dural sac on midsagittal image perpendicular to the longitudinal axis of the spine.

### 3. Result & Observation

Total No of 71 cases observed in which max no of spinal cord terminated L1 & L2. After calculating % of individual level 32.3% of spinal cord terminate at L1 lower level which is max. in no. 15.49 % cases terminate at L2- Upper level & at L1 middle level

**Table 1:** Spinal cord termination among study group

Level of spinal cord Termination	Frequency	%
T12-L1	4	5.63
L1-UPPER	8	11.27
L1-MIDDLE	11	15.49
L1-LOWER	23	32.39
L1-L2	3	4.22
L2-UPPER	11	15.49
L2-MIDDLE	5	7.04
L2-LOWER	5	7.04
L2-L3	1	1.40
L3-UPPER	-	-
Total	71	99.99%



Graph No.1 Spinal cord termination among study group

### 4. Discussion

In total No of 71 cases max no of spinal cord termination observed at around L1 & L2. In which 32.3% of spinal cord terminate at L1 lower level which is max. in no. 15.49 % cases terminate at L2- Upper level & at L1 middle level. In a study done by Boonpirak N1 et al[7] in 1994 The site of caudal termination of the spinal cord varied from the middle third of the twelfth thoracic vertebra to the upper third of the third lumbar vertebra. The mean level of cord termination was located opposite the intervertebral disc between the first and the second lumbar vertebrae, and there was no significant difference between the sexes ( $p > 0.05$ ).

Saifuddin et al (1998)[3] The study group consisted of 231 men and 273 women with a mean age 46 years (range, 16-85

years). The mean conus position was the lower third of L1 (range, middle third of T12 to upper third of L3). The variation in conus positions followed a normal distribution. No significant difference in conus position was seen between male and female patients or with increasing age. Conclusions of study was the distribution of conus location in a large adult population was shown to range from the middle third of T12 to the upper third of L3.

Gatonga et al[8] done a study in which the median level of termination of the cord was the upper third of L2, 51.9% of cases terminating below this. There was no statistically significant gender difference in the level of termination of the cord. The intercrystal plane passed through L4/L5 disc (70.9%) and below (29.1%). The TUP corresponded with intercrystal line in 78.2% of subjects. The mean distance of the spinal cord termination from intercrystal line was 99 +/- 24 mm. The spinal cord terminates at or below the upper third of L2. Care should be exercised during lumbar punctures and spinal epidural anesthesia among Africans. Intercrystal line and TUP are safe landmarks to use in location of conus medullaris.

### 5. Conclusion

The results obtained are compared to the previous studies done. The results of present study were differs from previous studies. It might be possible because of many factors like different Ethnic & Racial groups, Genetic factors; Environmental conditions & different age & sex groups. The present study is an attempt to provide data base for a range of termination of spinal cord. Which is helpful in clinical procedures like lumbar puncture and accurate localization in cranial spinal irradiation & anaesthesiologist practicing regional anaesthesia

### References

- [1] Jaehan Koh, Peter D. Scott, Vipin Chaudhary, an automatic segmentation method of the spinal canal from clinical mr images based on an attention model and an active contour model; Proscan Imaging of Buffalo Williamsville, NY 14221, USA.
- [2] Snider KT, Kribs JW, Snider EJ, Degenhardt BF, Bukowski A, Johnson JC. Reliability of tuffiers line as an anatomic landmark. Spine 2008; 33: e161-E165.
- [3] Saifuddin A, Burnett SJ, White J. The variation of position of the conus medullaris in an adult population. A magnetic resonance imaging study. Spine (Phila Pa 1976). 1998 Jul 1; 23 (13): 1452-6.
- [4] McDonald A, Chatrath P level of termination of spinal cord and the dural sac: A MRI study. Clin Anat 1999; 12: 149-52.
- [5] Boonpirak N, Apinhasmit W. Length and caudal level of termination of spinal cord in Thai adults. Acta Anat 1994; 149: 74-8.
- [6] Demiryurek D, Aydingoz U, Asit MD et al. MR imaging determination of the normal level of conus medullaris. J Clin Imaging 2002; 226: 375-7.
- [7] Boonpirak N1, Apinhasmit W. Length and caudal level of termination of the spinal cord in Thai adults. Acta Anat (Basel). 1994; 149(1): 74-8.

- [8] Gatonga P1, Ogeng'o JA, Awori KO. Spinal cord termination in adult Africans: relationship with intercrystal line and the transumbilical plane. Clin Anat. 2010 Jul;23(5):563-5. doi: 10.1002/ca.20963.

