

# Polycythaemia Vera presenting as Cerebral Venous Sinus Thrombosis – A Case Report

A.G. Kulkarni<sup>1</sup>, Jyoti Kharche<sup>2</sup>, Kulin Sheth<sup>3</sup>, Vaibhav Dube<sup>4</sup>

<sup>1</sup> Associate Professor ,MD (General medicine) in the Department of Medicine, Mahatma Gandhi Mission's Medical College and Hospital, Aurangabad, Maharashtra, India

<sup>2</sup> Associate Professor ,MD (General medicine) in the Department of Medicine, Mahatma Gandhi Mission's Medical College and Hospital, Aurangabad, Maharashtra, India

<sup>3, 4</sup>. Resident in the Department of Medicine, Mahatma Gandhi Mission's Medical College and Hospital, Aurangabad, Maharashtra, India

**Abstract:** *Cerebral venous sinus thrombosis although being multifactorial in aetiology, is now being increasingly suspected and diagnosed – clinically and radiologically. Its occurrence with polycythaemia vera is rare. Polycythemia may present clinically due to hypercoagulable state or an additional precipitating factor may bring the patient to the hospital. We report a case of a chronic alcoholism, presenting as complex partial seizures, with radiological imaging suggestive of thrombosis of multiple cerebral sinuses. The patient was then found to have polycythaemia on further investigations. The contributing factors for acute presentation likely include alcohol ingestion and associated dehydration. After institution of appropriate therapy and phlebotomy, the patient showed dramatic improvement, and he was then discharged on appropriate treatment.*

**Keywords:** Cerebral venous sinus thrombosis, seizure, alcohol, polycythaemia vera

## 1. Introduction

Cerebral venous thrombosis should be considered as a differential diagnosis of all unexplained CNS disorders of sudden onset. It is more common in females (with a ratio of 1.29:1)<sup>[1]</sup>. Etiological factors are often subclinical forms of several common thrombophilic states occurring together, rather than rarer causes. Diagnosis is often missed because of heterogeneity in clinical presentation and aetiology. The symptoms and clinical course of this entity are highly variable. The disorder can occur de novo as the first presentation, or can overlap over another existing clinical presentation.

Polycythaemia vera, a clonal stem cell disorder, in which the bone marrow makes excessive red blood cells, produces neurological problems in 50-80% of the patients<sup>[2]</sup>. It is said to be slightly more common in males (on the order of a 1.2:1 male-to-female case ratio). Symptoms are caused mainly by increased blood volume, and thrombotic haemorrhagic complications. Cerebral venous sinus thrombosis has been associated with many hypercoagulable states, like thrombocytosis, polycythaemia vera, and remote infections<sup>[3-5]</sup>.

We report a rare case of chronic alcoholism with polycythaemia vera, presenting as thrombosis of several cerebral venous sinuses.

## 2. Case Report

A 40 year old married male, chronic alcoholic, smoker, non-diabetic, normotensive, having mixed dietary intake, presented to emergency room in a state of active convulsion as evidenced by active tonic clonic movements of all the four limbs, frothing from the angle of mouth, and tongue bite. This was followed by unconsciousness lasting for 3-4 hours.

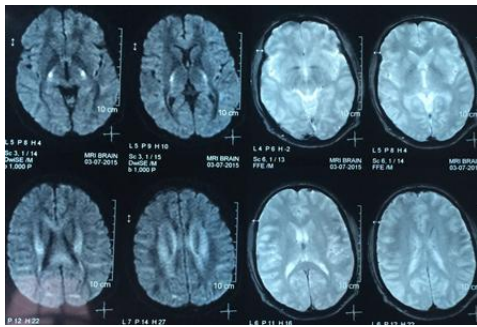
After regaining consciousness, the patient had persistent severe headache. Before admission, the patient had history of two episodes of complex partial seizures followed by headache, in one day. The patient was an alcoholic, consuming 180 ml alcohol per day every day, since past 15 years. He was apparently healthy prior to this illness.

The clinical examination, after regaining consciousness, did not reveal any focal neurological deficit, with bilaterally normally reactive pupils, and signs of dehydration were present. The pulse was 110 beats per minute, regular, and of low volume. The blood pressure was 100/70 mm of Hg in right arm in supine position. The patient had grade 3 clubbing present, without any signs of cyanosis, or jaundice. No other significant abnormality was detected. The clinical examination of other systems was normal.

Investigations revealed a haemoglobin of 19.4 gm% (ref. range 13 – 17 gm%), total leukocyte count of 7400/cu.mm (ref. range 4000 – 10000/cu.mm) , platelet count of 1,54,000/cu.mm (ref. range 150000 – 410000/cu.mm), prothrombin time of 15.0 sec with a control time of 12.0 sec (I.N.R - 1.24), ESR at the end of one hour was 5 mm, serum uric acid was 1.80 mg/dl (reference range 3.4 – 7.2 mg/dl), erythropoietin level was below 0.6 mIU/mL (reference range 4.3 – 29 mIU/mL). His fasting sugars, blood urea, serum creatinine, lipid profile, and serum electrolytes were within normal limits. Kit test for HIV, and card test for HBsAg were negative. Ultrasound of abdomen and pelvis revealed left sided mild hydronephrosis secondary to renal pelvis calculus.

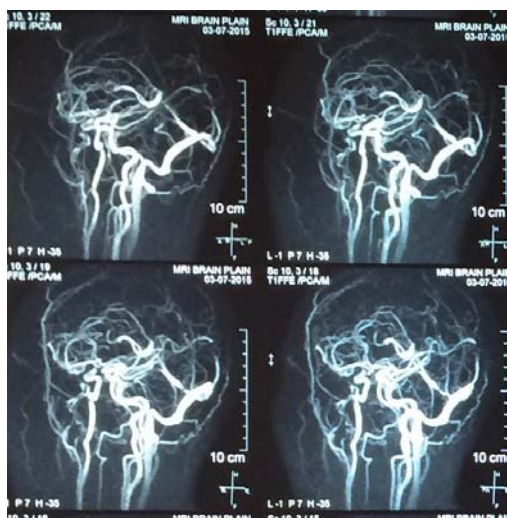
ECG and 2D echocardiography were normal.

MRI scan of brain revealed haemorrhagic areas in bilateral high parietal lobes representing venous infarcts, with thrombosis of the superior sagittal sinus and superficial cortical veins.



**Figure 1:** Haemorrhagic areas in bilateral high parietal lobes representing venous infarcts, with thrombosis of the superior saggital sinus and superficial cortical veins.

MRI venography of the brain revealed thrombosis of superior saggital sinus, right transverse and sigmoid sinuses, jugular bulb and right jugular vein, with thrombosis of superficial cortical veins over high frontoparietal convexity.



**Figure 2:** Thrombosis of superior saggital sinus, right transverse and sigmoid sinuses, jugular bulb and right jugular vein, with thrombosis of superficial cortical veins over high frontoparietal convexity

With elevated haematocrit, low erythropoietin levels, radiological evidence of thrombosis of cerebral venous sinus thrombosis, and with no apparent cause of secondary erythrocytosis, this case was diagnosed as polycythemia vera.

This young male had no significant factors for atherothrombosis. With a high index of suspicion, hypercoagulable state such as polycythemia was thought to be the cause of cerebral sinus thrombosis. After correction of dehydration, he was treated with fondaparinux, phenytoin, and warfarin, along with phlebotomy twice. The patient had satisfactory response to the treatment, there were no episodes of seizures, his headache subsided, and he was comfortable. He was discharged 16 days after admission and was followed up till 15 days after discharge.

### 3. Table

**Table 1:** Laboratory findings

	On admission	On discharge	On follow up
Haemoglobin ( g/dL)	19.4	20.9	17.6
Total Leukocyte Count (/ microL)	7400	8420	7930
Platelets (/microL)	154000	396000	196000
Haematocrit (%)	56.5	59.5	49.5
Prothrombin Time (seconds)	15	32.9	19.7
I.N.R.	1.2	2.6	1.6
Erythropoetin	BELOW 0.6 mIU/mL		
Urea ( mg/dL)	25		
Serum Creatinine (mg/dL)	1		
Serum Sodium (mEq/dL)	138		
Serum Potassium (mEq/dL)	4.3		
Serum Bilirubin (total) (mg/dL)	0.5		
SGOT (U/L)	20		
SGPT (U/L)	22		

### 4. Discussion

Cortical venous sinus thrombosis is not an uncommon cause of stroke in our country. Amongst variety of causes, such as dehydration, antiphospholipid antibody syndrome, hyperhomocysteinemia, Factor V Leiden, malignancies, paraproteinemia, paroxysmal nocturnal hemoglobinuria and certain drugs like oral contraceptives and L-asparaginase, polycythemic states are a contributory factor, but are often overlooked. The prevalence of thrombosis at the time of diagnosis of polycythemia vera ranges between 34 and 39% [6]. CVST most commonly involves superior sagittal sinus (72%) followed by lateral sinus (70%). In 30-40% cases, more than one sinus is involved with or without cortical venous thrombosis [7]. The common clinical manifestations seen in CVST are headache (75-90%), papilledema, focal neurological deficits (75%) and seizures [8]. Rarely, about 4% of patients with SSS thrombosis present with bilateral or alternating lower limb weakness. Unusually, patients present with a “thunderclap headache” mimicking subarachnoid hemorrhage (SAH) [9].

Polycythemia vera is a disorder involving a multipotent hemaopoietic progenitor cells in which phenotypically normal red cells, granulocytes and platelets accumulate in the absence of a recognisable physiologic stimulus. The patients suffering from this commonly present with non-specific symptoms like fatigue, vertigo, dizziness, pruritus, dyspepsia or blurring of vision, or may remain asymptomatic [10]. Thrombotic phenomena are a frequent presentation including cerebral arterial and rarely venous thrombosis. The most likely mechanisms are hyper viscosity and sluggish blood flow. Due to increased haematocrit in polycythemia vera, there is increased blood viscosity and consequently an increased incidence of thrombotic phenomena [11, 12].

With increase in the plasma red cell volume in polycythemia, the viscosity of blood increases, leading to complications of the hypercoagulable state including thrombotic phenomenon such as stroke, cortical sinus thrombosis, acute coronary syndrome, pulmonary embolism, deep vein thrombosis [13].

The aim of treatment in cerebral sinus thrombosis with polycythemia is to prevent further thrombosis by reducing high blood viscosity. Treatment should address both cerebral sinus thrombus management and polycythemia. Phlebotomy serves initially to reduce hyper viscosity by bringing red cell mass to normal range. Periodic phlebotomies thereafter serve to maintain the red cell mass within normal range. Anticoagulants are indicated when a thrombus has occurred. Allopurinol can be used in hyperuricemia. Anagrelide, a phosphodiesterase inhibitor, is tolerated, and is preferential to hydroxylurea because it lacks marrow toxicity and is actually protective against venous thrombosis<sup>[14]</sup>. Pegylated interferon-Alpha produces complete remissions in polycythemia patients and its role is expanding. Allogenic bone marrow transplantation may be curative<sup>[14]</sup>. Most patients with polycythemia vera can be effectively managed without functional impairment by phlebotomy alone.

## 5. Conclusion

Polycythaemia vera, sickle cell anaemia, sickle-Cell disease, and essential thrombocythaemia are the major disorders of formed blood elements causing hypercoagulable state. Special, step-wise screening for occult prothrombotic entities in young patients presenting with cortical venous sinus thrombosis is recommended and for those with no other explanation for recurrent stroke. In patients of polycythemia, transient, acute conditions such as dehydration, alcohol intake, and others may contribute importantly in synergy with other mechanisms and lead to development of a hypercoagulable state, but at present these remain ill-defined. The early detection and treatment of polycythemia vera as the cause of acute thrombotic complications such as cortical venous sinus thrombosis can help guide the further management of the same.

## References

- [1] Ameri A, Bousser MG. Cerebral venous thrombosis. *Neurol Clin.* 1992 Feb. 10(1):87-111
- [2] Newton LK: Neurologic complications of polycythemia and their impact on therapy. *Oncology* 1990; 4: 59 - 64
- [3] Bousser MG, Chiras J, Bories J, Castaigne P: Cerebral venous thrombosis-A review of 38 cases. *Stroke* 1985; 16 : 199-213.
- [4] Murphy MF, Clarke CR, Brearley RL: Superior sagittal sinus thrombosis and essential thrombocythemia (abstract). *Br Med J* 1983;
- [5] Chievitz E, Thiede T. Complications and causes of death in polycythemia vera. *Ada Med Scand* 1962; 172 : 513-23.
- [6] Tefferi A, Elliott M. Thrombosis in myeloproliferative disorders: prevalence, prognostic factors, and the role of leukocytes and JAK2V617F. *Semin Thromb Hemost.* 2007 Jun;33(4):313-20.
- [7] Brousser MG, Barnett HJM. Cerebral Venous Thrombosis. In: *Stroke: pathophysiology, diagnosis and management*, 2nd ed. New York. Churchill Livingstone, 1992;517-37.

- [8] Mehta SR, Swamy AJ, Varadarajulu R, Gupta A. A clinical profile of cortical venous thrombosis - A report of 20 cases. *JAPI* 2002;50:76-7.
- [9] De Bruijn SF, Stam J, Kapelle LJ. Thunderclap headache as the first symptom in Cerebral Venous Sinus Thrombosis. CVST study group. *Lancet* 1996;348:1623-5.
- [10] LINARDI, Camila da Cruz Gouveia; PRACCHIA, Luís Fernando and BUCCHERI, Valeria. Diagnosis and treatment of polycythemia vera: Brazilian experience from a single institution. *Sao Paulo Med. J.* 2008, vol.126, n.1
- [11] Spivak, Jerry L. "The optimal management of polycythaemia vera." *British journal of haematology* 116.2 (2002): 243-254.
- [12] Spivak, Jerry L. "Polycythemia vera: myths, mechanisms, and management." *Blood* 100.13 (2002): 4272-4290.
- [13] Landolfi, Raffaele, et al. "Efficacy and safety of low-dose aspirin in polycythemia vera." *New England Journal of Medicine* 350.2 (2004): 114-124.
- [14] Dennis L. Kasper, Anthony S. Fauci, Stephen L. Hauser, Dan L. Longo, J. Larry Jameson, Joseph Loscalzo - *Harrison's Principles of Internal Medicine* 19/E, 2015 : 671