

# Persistent Deciduous Mandibular Canines as the Cause of Impaction of Permanent Mandibular Canines

Hristina Arnautska, DMD, PhD\*

Assistant Professor, Department of Orthodontics, Faculty of Dental Medicine, Medical University-Varna, Bulgaria

**Abstract:** *Physiological resorption of the deciduous canine is essential for the eruption of permanent canines. Persistent deciduous canine lead to greater medial inclination of the permanent canine germ and deviation in the normal eruption path of the lower permanent canine. The aim of the present paper is to demonstrate the correlation between persistent mandibular deciduous canines and the retention of permanent canines. The axis inclination of the lower permanent canine germ of more than 25 degrees in relation to the median line and the deciduous canine, as well as the delay in resorption of one in relation to the opposite deciduous canine are indications of the altered eruption path even in children with early mixed dentition. In the presented clinical cases early extraction of the deciduous canine leads to improvement and better positioning of permanent canines. The extraction of the persistent deciduous canine in the permanent dentition with a formed root of an impacted tooth makes it harder to alter the path of the canine tooth. Timely diagnosis of impaction likelihood of permanent canines and extraction of temporary ones in early mixed dentition by reserving the space for the permanent canine is seen as a preventive measure for altering eruption paths.*

**Keywords:** impacted lower canine, delayed eruption, persistent deciduous canine, mandibular canine

## 1. Introduction

The process of retention of permanent teeth for as long as one year after their due eruption or after the final development of human teeth and the canine root is referred to as Impaction. Mandibular canine teeth impaction is significantly infrequent in comparison with maxillary canines. Impaction incidences vary from 0.07% as per Chu et al [4], 0.22% according to Grover and Lorton [5] to 0.44% as per Aydin et al [2].

## 2. Literature Survey

In normal development of permanent teeth mandibular canines erupt concomitantly with maxillary first premolars marking the onset of the rather long period of late mixed dentition. The persistence of deciduous mandibular canines is mostly associated with disorder and delay of their root resorption at the time of change with their permanent counterparts. Many authors attribute reduced resorption to a number of factors: follicular cysts, trauma, endocrine disorders, fractures due to dislocation of tooth germ and the more difficult resorption of the compact bone in the lower jaw. [7,10].

Lack of space or genetic predisposition may also be the cause of abnormal position of the bony crypt of the lower canine germ resulting in deviation in the normal eruption of the permanent canine and persistence of the temporary one. Ando et al. [1] suggest that early loss of teeth, lack of space and the large-sized lower canine crown are factors contributing to impacted mandibular canines. In his two studies Joshi [8,9] establishes persistent deciduous canines for 60.5% and 70.8% respectively of his target patients with impacted mandibular canines. Preliminary extraction of temporary canines is an attempt to prevent abnormal eruption and to correct the position of ectopic lower canines.

In a large percentage of cases of retained mandibular canine teeth it is impossible to embark on an orthodontic or orthodontic-surgical treatment, hence most often they are subject to extraction [3,13] or keeping them under close observation, provided there is no complication and that they are positioned horizontally below the apexes of the incisors .

## 3. Aim

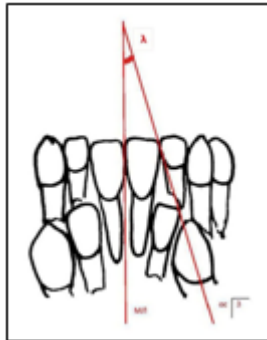
The aim of the present paper is to demonstrate the correlation between persistent mandibular deciduous canines and the retention of permanent canines. Timely diagnosis of impaction likelihood of permanent canines and extraction of temporary ones in early mixed dentition by reserving the space for the permanent canine is seen as a preventive measure for altering eruption paths.

## 4. Material and Methods

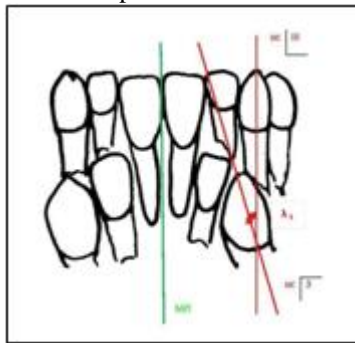
The present paper discusses two cases: one of a nine-year old girl with early mixed dentition having a steep inclination of the right mandibular permanent canine and a persistent deciduous canine (referred to as Case 1) and a second case of a 18- year old girl with a permanent dentition (referred to as Case 2), having an impacted right mandibular canine and a persistent deciduous canine.

Using Panoramic Radiograph (OPG) following Howard methodology angle  $\lambda$  has been measured ( $\lambda$  being the angle between the axis of the tooth germ of the permanent canine and median line). (Fig. 1) Using a modified version of Howard methodology (proposed by us) angle  $\lambda_1$  has been measured ( $\lambda_1$  being the angle between the axes of temporary and permanent canines) for a more detailed defining of the position of the permanent canine tooth in relation to the deciduous third tooth. (Fig. 2)

The increased inclination of the permanent tooth germ in relation to the temporary canine in the lower jaw of more than 31 degrees in late mixed dentition, proposed in this paper, as well as the canine axis inclination of more than 25 degrees in relation to the median line, according to Howard are indicators of retained mandibular canines.



**Figure 1:** Methodology of measuring the angle between the median line and the axis of the permanent canine germ as per Howard



**Figure 2:** Methodology of measuring the axis of the permanent canine germ and the deciduous canine, modified and proposed by author

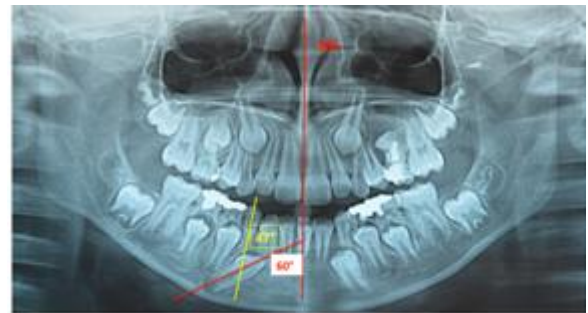The present paper proposes a modified methodology as per Taguchi [11] (Fig. 3) in order to assess the extent of resorption of deciduous canines. The methodology delineates the different phases of resorption during permanent canine eruption.

Rates of resorption				
1	2	3	4	5
No resorption	upto 1/3 of the root deciduous canine	upto 1/2 of the root deciduous canine	upto 2/3 of root deciduous canine	Resorbed deciduous canine

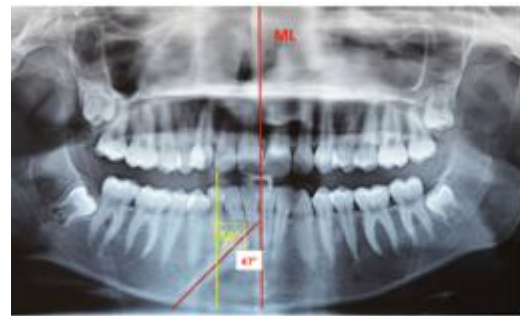**Figure 3:** Rates of resorption of the deciduous lower canine

## 5. Results

Figure 4 and 5 represent the initial orthopantomograms (OPGs) of the two clinical cases.



**Figure 4:** Case 1 - Initial OPG of a 9-year girl with early mixed dentition



**Figure 5:** Case 2 - Initial OPG of a 18-year old girl with permanent dentition

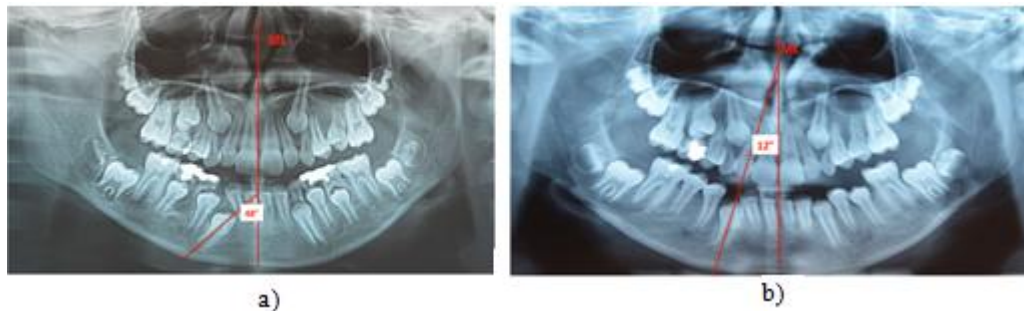
The angle size values and the degree of resorption at the beginning of the treatment are displayed in Table I.

**Table 1:** The value of angle  $\lambda$ , angle  $\lambda_1$  and rate of resorption of deciduous canines at the beginning of treatment

Parameter Patient	Angle axis 3/ Median line ( $\lambda$ )	Angle axis 3/ axis III ( $\lambda_1$ )	Rates of resorption deciduous canine
Case 1	60°	47°	Up to 1/3 of the root Deciduous canine
Case 2	47°	50°	Up to 1/2 of the root Deciduous canine

The data reveal a considerable increase above the average rate values for both angles with both target patients, as well as reduced rate of resorption respectively of the deciduous canines with a tendency of retention. In the first case resorption is a lot less manifested compared to that of the opposite side, whereas in the second case there is a persistence of the right permanent canine and the sprouting left permanent canine. In either cases the step undertaken consisted of extraction of the deciduous canine and for

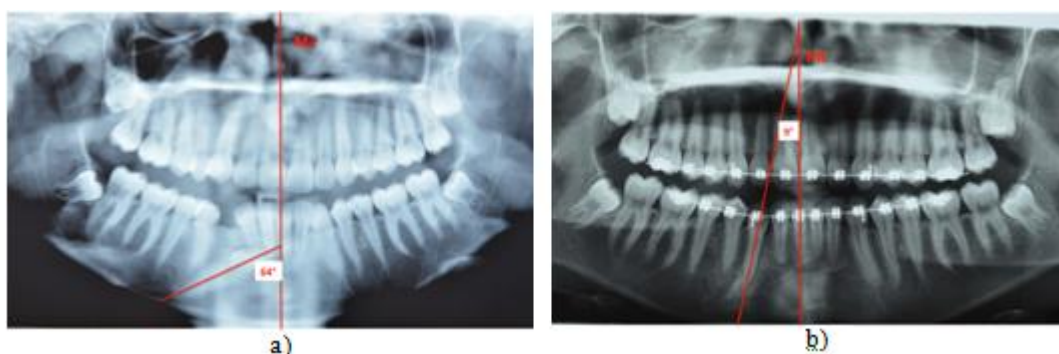reserving the space eruption of the permanent canine. The patients were placed under observation. Eight months later the values of the angle between the axis of the permanent canine and the median line were taken. The patient with mixed dentition exhibited a spontaneous straightening of the canine – angle  $\lambda$  is 48 degree (Fig. 6a) and a year later it erupted by itself (Fig. 6b).



**Figure 6:** Case 1 - a) 8 months after extraction of the deciduous right canine  
 b) 15 months after extraction of the deciduous canine and a spontaneous eruption of the permanent canine

Eight months after extraction of the deciduous canine the patient with permanent dentition exhibited deterioration in the inclination of the permanent canine in relation to the median line- angle  $\lambda$  is 64 degree (Fig.7a). The patient

underwent orthodontic treatment where the impacted canine was revealed and withdrawn into the dental arch. (Fig.7b)



**Figure 7:** Case 2 - a) 8 months after extraction of the deciduous canine  
 b) 1 year after orthodontic treatment

## 6. Discussion

The presented case studies demonstrate that diagnosis of altered eruption path of the mandibular canine in early mixed dentition and the extraction of the deciduous canine leads to spontaneous straightening and eruption of the permanent canine as a result of the eruptive force and the lack of resistance by the root of the deciduous one. The approach presented in the paper maintains the argument supported by Vichi et al [12] who also recommend radiographical monitoring over a period of six months in the cases of delayed eruption of mandibular canines. Early prognosis allows for eruption stimulation. If the inclination increases and the position deteriorates it is necessary to proceed to surgical and orthodontic manipulation as was the protocol for Case 2 (Fig. 7b). The extraction of the persistent deciduous canine in the permanent dentition with a formed root of an impacted tooth makes it harder to alter the path of the canine tooth. In the case presented in this paper we even established increased inclination of the permanent canine which required orthodontic treatment using fixed devices, revealing and withdrawal of the tooth into the dental arch.

The conviction held in the present paper is that early predictor of the ratio between the axes of the deciduous and permanent canines as well as the delay in resorption of one in relation to the opposite deciduous canine are of utmost importance. The persistence of the lower canine tooth and the axis inclination of the permanent tooth in relation to the deciduous one alert about a change in the path of the

permanent lower canine during late mixed dentition. In cases of delayed eruption of permanent lower canines and persistent deciduous ones a number of authors also recommend OPG monitoring of the patient over a period of six months. [12]

Our clinical results confirm Howard's findings [6] that axis inclination of the lower canine tooth of more than 25 degrees in relation to the median line and the deciduous canine is an indication of the altered path of eruption even in children with early mixed dentition. Using the expanded methodology presented in this paper and the introduction of an extra angle  $\lambda_1$  further emphasize the need for early extraction of the deciduous canine. The data obtained and disclosed in this paper give us reason to believe that the extra angle proposed here refines diagnosis. Early prognosis makes it possible to induce eruption, even lingual eruption. In case of increased inclination of the canine in relation to the median line in permanent dentition it is advisable to undertake extraction of the deciduous canine, reveal the permanent tooth and by mounting a fixed device to withdraw the deciduous canine to its normal position into the dental arch. [12,14]

## 7. Conclusion

Physiological resorption of the deciduous canine is essential for the eruption of permanent canine. The persistent deciduous canine leads to greater medial inclination of the permanent canine germ and deviation in the normal eruption



path of the lower permanent canine.

Early diagnosis and timely preventive measures tend to reduce and eliminate the causes leading to impacted lower canines. Early prevention helps preserve the morphological and functional efficiency of permanent dentition. Even in early mixed dentition when deviation in the eruption path is detected, early extraction of the deciduous canine leads to improvement and better positioning of permanent canines. Thus serious surgical interventions and prolonged orthodontic treatment are avoided.

## References

- [1] Ando, S., K. Aizawa, T. Nakashima, Y. Sanka, K. Shimbo, K. Kiyokawa. Transmigration process of the impacted mandibular cuspid.-J. Nihon Univ. Sch. Dent.,6, 1964, 66-71.
- [2] Aydin, U., H. H. Yilmaz, D. Yildirim. Incidence of canine impaction and transmigration in a patient population.-Dentomaxillofac. Radiol., 33, 2004, No 3, 164-169
- [3] Celikoglu, M., H. Kamak, H. Oktay. Investigation of transmigrated and impacted maxillary and mandibular canine teeth in an orthodontic patient population.-J. Oral Maxillofac. Surg.,68, 2010, No 5, 1001-1006.
- [4] Chu, F. C., T. K. Li, V. K. Lui, P. R. Newsome, R. L. Chow, L. K. Cheung. Prevalence of impacted teeth and associated pathologies-a radiographic study of the Hong Kong Chinese population.- Hong Kong Med. J.,9, 2003, No 3, 158- 163.
- [5] Grover, P. S., L. Lorton. The incidence of unerupted permanent teeth and related clinical cases.-Oral Surg. Oral Med. Oral Pathol.,59, 1985, No 4, 420- 425.
- [6] Howard RD. The anomalous mandibular canine.-Br. J. Orthod., 3, 1976, No 2, 117-121.
- [7] Joshi, M. R., N. A. Bhatt. Canine transposition.-Oral Surg. Oral Med. Oral Pathol.,31, 1971, No 1, 49-53.
- [8] Joshi, M. R., S. B. Shetye. Transmigration of mandibular canines: a review of the literature and report of two cases.-Quintessence Int., 25, 1994, No 4, 291-294.
- [9] Joshi, M. R. Transmigrant mandibular canines: a record of 28 cases and a retrospective review of the literature.- Angle Orthod., 71, 2001, No 1, 12-22.
- [10] Mitchell, L. Displacement of a mandibular canine following fracture of the mandible.-Br. Dent. J.,174, 1993, No 11, 417-418.
- [11] Taguchi, Y., S. Hayashi-Sakai, T. Tsuda. Severe cases of ectopically erupting maxillary canine with excessive mesial angulation.-Pediatr. Dent. J., 18, 2008, No 1, 34-42.
- [12] Vichi, M., L. Franchi. The transmigration of the permanent lower canine.- Minerva Stomatol.,40, 1991, No 9, 579-589 (Italian).
- [13] Wertz, R.A. Transmigrated mandibular canines.-Am. J. Orthod. Dentofacial Orthop.,106, 1994, No 4, 419-427.
- [14] Yavuz, M. S., M. H. Aras, M. C. Büyükkurt, S. Tozoglu. Impacted Mandibular Canines.- J. Contemp. Dent. Pract., 8, 2007, No 7, 78-85.

## Author Profile



**Hristina Ivanova Arnautska**, DMD, PhD completed her Master's degree in Dentistry in 1999. She specialized in Orthodontics at the Faculty of Dental Medicine, Medical University - Sofia in 2006, as well as in Health Management at the Medical University - Varna in 2011. Since 2008 she has been an Assistant Professor at the Department of Orthodontics at the Medical University of Varna, Bulgaria. In 2013 she obtained her PhD degree in Orthodontics and presented her research dissertation "Diagnosis and prediction of canine impaction". Her research interests are in the area of ectopic and impacted canine, preventive orthodontics and interdisciplinary treatment approaches. Dr. Arnautska is a member of WFO, EOS, SIDO, BOS and BSCLO.