

Gaucher's Disease: Not a Rare Clinical Entity..!

Dr. Nidhi Dhamecha, Dr. Anuya Chauhan, Dr. Gargi Pathak

Abstract: This is a study of clinical presentation of gaucher's disease in 5 patients diagnosed between December 2010 to December 2014 at a tertiary care centre. All patients were less than 4 years of age and were diagnosed for the first time in our set up. All of them presented with splenohepatomegaly, other features being pancytopenia, neurological involvement and bone involvement. Male to female ratio was 2:3. Diagnosis was confirmed by bone marrow examination in four out of five patients, the rest one was diagnosed by microscopic examination of splenic tissue after splenectomy for hypersplenism. One patient succumbed to death because of neurological involvement in form of persistent seizures at 10 months of age (gaucher's disease type 2). Others were treated symptomatically and were referred to higher centre for enzyme replacement therapy.

Keywords: Gaucher's disease, Beta-glucosidase, Pancytopenia, Crumpled tissue appearance, Enzyme replacement therapy

1. Introduction

Gaucher's disease is a multisystemic lipidosis characterized by hematologic abnormalities, organomegaly & skeletal involvement. It is the most common lysosomal storage disease resulting from deficient activity of the lysosomal hydrolase; acid B-glucosidase encoded by a gene located on chromosome no. 1q21-q31, resulting in accumulation of undegraded glycolipid substrates, particularly glucosylceramide, in cells of reticuloendothelial system leading to various clinical manifestations.

2. Aims and Objectives

To study clinical profile of patients of gaucher's disease in a tertiary care hospital.

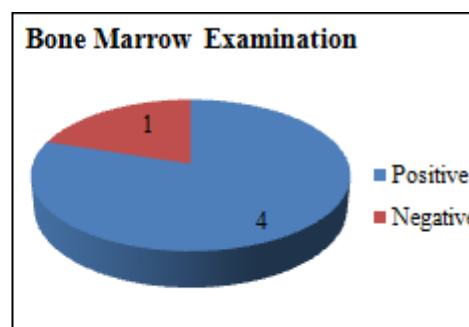
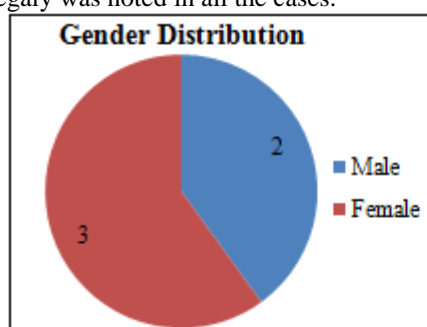
3. Materials and Methods

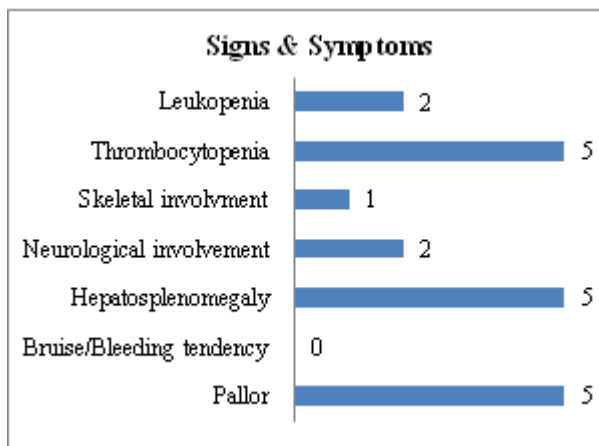
This study was conducted at civil hospital Ahmedabad from December 2010 to December 2014. Total 5 patients diagnosed at our hospital as gaucher's disease were included in the study. Their clinical profile and laboratory reports were analyzed.

4. Observations

- Age of presentation was less than 4 years in all the cases.
- Male: female ratio was 2:3.
- None of them was born out of consanguineous marriage. Two of the patients were siblings.
- All of them had pallor on presentation, none of them had presented with CCF. Blood transfusion was given to one patient in our set up in view of severe anemia.
- None of the cases showed bruising or bleeding tendency.
- Hepatosplenomegaly was noted in all the cases.

- Neurological involvement was seen in two cases, one of them had gross developmental delay, where as the other had microcephaly, nystagmus, gross developmental delay and seizures refractory to antiepileptics.
- Skeletal involvement was seen in one patient in form of Erlenmeyer flask deformity and later on osteomyelitis of tibia.
- Two out of five had leucopenia.
- All of them had thrombocytopenia.
- Bone marrow examination was done in all the cases and 4 of them showed hyper cellular marrow with marked interstitial infiltrates of clusters & sheets of histiocytes with crumpled tissue appearance which was conclusive for gaucher's disease.
- Bone marrow examination was normal in one of our patients. We went for splenectomy in that patient in view of persistent splenomegaly. Microscopic examination of the splenic specimen showed typical gaucher cells and this confirmed our diagnosis as gaucher's disease.
- Enzyme study was done in only one patient which showed reduced B glucosidase activity.
- One other important thing was that, the mother of the two affected sibling underwent amniocentesis for antenatal diagnosis in her third pregnancy. The report from cultured amniotic fluid cells showed low activity of beta-glucosidase (8.1 nmol/hr/mg protein compared to 118-401.5 nmol/hr/mg protein). This test being nearly 99% sensitive & specific, suggested high chances that the fetus is affected with gaucher's disease. This pregnancy was terminated on the medical grounds.
- One patient died of neurological involvement in form of persistent seizures refractory to multiple antiepileptics, where as one patient showed complication in form of septicemia which was treated with proper antibiotics.





5. Discussion

Gaucher's disease is a genetic disease in which fatty substances (sphingolipids) accumulate in the cells & certain organs. Deficient activity of enzyme glucocerebrocidase leads to accumulation of glucosylceramide particularly in white blood cells- most often macrophages and also in various organs leading to disease manifestation.

Gaucher's disease has 3 clinical subtypes:

Type 1 or the adult type is a non neuropathic form and it is most common form of the disease. Onset being from early childhood to late adulthood. Clinical presentation may be bruising from thrombocytopenia, chronic fatigue secondary to anemia, hepatomegaly with or without altered liver function tests, splenomegaly and bone pain. Many have radiological features of bone involvement in form of Erlenmeyer flask deformity of distal femur. Developmental delay due to effects of chronic disease can occur.

Type 2 is less common. It is characterized by rapid neurodegenerative course with extensive visceral involvement and death within the 1st year of life. It presents in infancy with increased tone, strabismus and organomegaly. Failure to thrive and stridor due to laryngospasm is usually present. Psychomotor regression is there. Death occurs secondary to respiratory compromise.

Type 3 presents as clinical manifestations that are intermediate to those in type 1 & 2, with presentation in early childhood & death by age 10-15 years. Subdivided in Type3a having progressive myotonia & dementia and type 3b having isolated supranuclear gaze palsy.

The pathologic hallmark of gaucher's disease is the gaucher's cell in the reticuloendothelial system, esp. in bone marrow, with characteristic wrinkled paper appearance resulting from intracytoplasmic inclusions and strongly positive for PAS (Periodic Acid-Schiff) stain. All suspected cases should be confirmed by determination of acid B-glucosidase activity in isolated leukocytes or cultured fibroblasts. Prenatal diagnosis is also available by determination of enzyme activity or specific mutation in chorionic villi or cultured amniotic fluid cells.

Treatment of type 1 gaucher's disease includes enzyme replacement therapy, with recombinant acid B-glucosidase (Imiglucerase). There are 3 different glucocerebrocidase:

Imiglucerase, Velaglucerase, and Teleglucerase alpha. Most extra skeletal systems (other than neurological) are reversed by enzyme (60IU/kg) administered by intravenous infusion every other week. Enzyme replacement does not alter the neurologic progression of patients with gaucher disease type 2 & 3, can be used as a palliative measure, particularly in type 3 patients with severe visceral involvement. Alternative treatment with agents designed to decrease synthesis of glucosylceramide by chemical inhibition of glucosylceramide synthase are also available for the patients who cannot be treated by enzyme replacement. One such drug is Miglustat. This approach is called substrate reduction therapy.

6. Conclusion

Gaucher's disease is a multisystem disorder with more of hematological involvement than skeletal involvement. A high index of suspicion helps to diagnose it at an early stage. Prognosis of patients with neurological involvement is generally poor where as others can be managed with enzyme replacement and supportive measures.

References

- [1] Gaucher Disease at National Gaucher Foundation. Retrieved June 2012.
- [2] Grabowski GA: Phenotype, diagnosis, and treatment of Gaucher's disease. *Lancet* 2008; 372:1263-1271.
- [3] Itzhaki M, Lebel E, Dweck A, et al: Orthopedic considerations in Gaucher disease since the advent of enzyme replacement therapy. *Acta Orthop Scand* 2004; 75: 641-653.
- [4] Kaplan P, Anderson HC, Kacena KA, et al: The clinical and demographic characteristics of nonneuronopathic Gaucher disease in 887 children at diagnosis. *Arch Pediatr Adolesc Med* 2006; 160:603-608.
- [5] Nelson's textbook of paediatrics., 19th edition
- [6] Thomas AS, Mehta A, Hughes DA (2014). "Gaucher disease: hematological presentations and complications". *Br. J. Haematol.* **165** (4): 427-40. [doi:10.1111/bjh.12804](https://doi.org/10.1111/bjh.12804). PMID 24588457.