

# Mycotic Corneal Ulcer Due to *Curvularia Pallescens* Boedijn

Sagar K, Mangalkar S, Gohel T

<sup>1</sup>3<sup>rd</sup> year Resident, Department of Microbiology, GMC & H, Latur

<sup>2</sup>Associate Professor, Department of Microbiology, GMC & H, Latur

<sup>3</sup>Assistant Professor, Department of Microbiology, GMC & H, Latur

**Abstract:** *The importance of corneal disease as a major cause of blindness in the world today remains second only to cataract, but its epidemiology is complicated and encompasses a wide variety of infectious and inflammatory eye diseases<sup>1</sup>. Ulcers are primarily divided into infectious and noninfectious categories. Bacterial infections (chiefly Pseudomonas and Staphylococcus) are by far the most common, but other microbes include fungi (molds such as Fusarium and yeasts such as Candida), parasites (Acanthamoeba), and viruses (herpes simplex)<sup>2</sup>. The causative fungi of keratomycosis are ubiquitous organisms and they are responsible for 6-53% of all corneal infection worldwide<sup>3</sup> Aspergillus and Fusarium are long recognized as ocular pathogens<sup>4</sup>, but the dematiaceous hyphomycetes have emerged as important opportunists.<sup>5-8</sup> This genus of filamentous fungi colonizes soil and vegetation and spreads by airborne spores<sup>9</sup>. Curvularia species has been reported second commonest agent of mycotic keratitis after Aspergillus species<sup>10</sup>.*

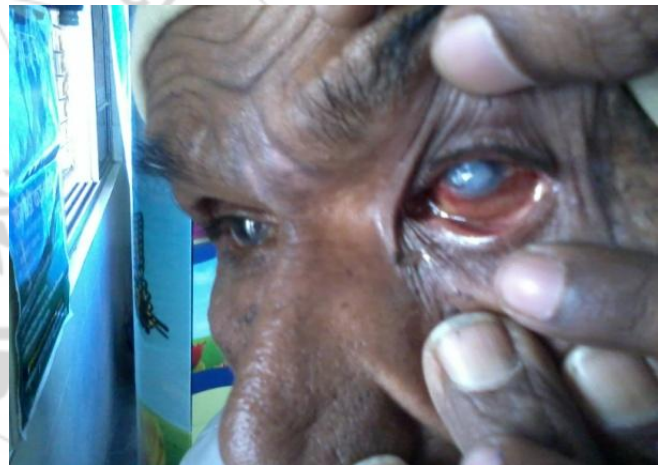**Keywords:** Curvularia, corneal ulcer

## 1. Case Presentation

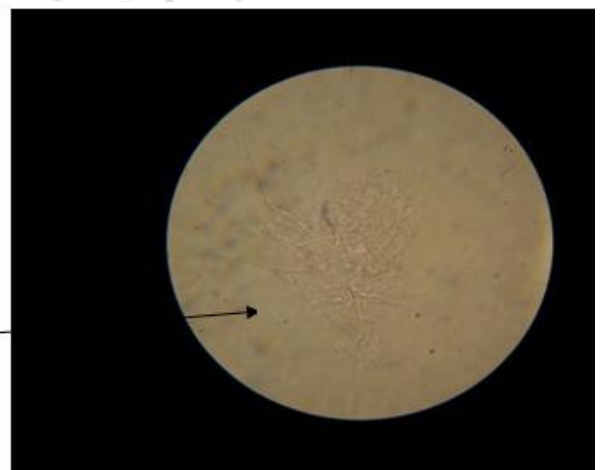
A 80 year old man came to ophthalmic OPD complaining of pain, redness watering and blurring of vision left eye since 8 days. He gave the history of ocular trauma by vegetative material during working in farm ten days back. He got treatment from local doctor for the same in form of steroid and antibiotic combination eye drop but symptoms didn't relieve instead it get worsened.

On slit lamp examination ophthalmologist diagnosed it as a case of corneal ulcer. Ophthalmologist collected corneal scrapping & sent it to microbiology department for further etiological evaluation. In our lab we performed direct examination in 10% KOH mount, gram stain. For isolation of organism we inoculated blood agar, mac conkey, two sets of Sabouraud dextrose agar (SDA). Blood agar & mac conkey are incubated at 37<sup>o</sup> c. Two sets of SDA incubated at 25<sup>o</sup> c & 37<sup>o</sup> c separately.

On KOH mount we found interlacing meshwork of septate fungal hyphae. Gram stain showed few pus cells, gram positive fungal hyphae but no bacterial organisms. This report was immediately conveyed to ophthalmologist. There was no organism isolated on blood agar and mac conkey agar. On SDA, growth occurred within 3-4 days it showed on obverse woolly olive-brown colonies, reverse was black. On lactophenol cotton blue (LPCB) staining it showed dark septate hyphae. Conidiophores unbranched, Conidia with 3-4 cells curved with swelling of central cell. Slide culture showed unbranched, septate hyphae and short, brown conidiophores bearing single septate curved conidia with central cells enlarged. It was diagnosed as curvularia species on microscopic finding. Strain was further sent to National Fungal Culture Collection Of India, Pune for identification based on morphotaxonomy. They identified it as curvularia pallescens Boedijn



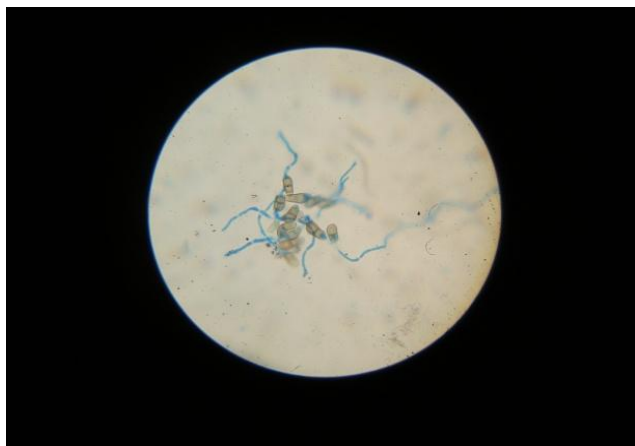Corneal Ulcer



Wet mount showing Septate Hyphae



Growth on SDA



LPCB Mount

## 2. Management & Outcome

Ophthalmologist gave Natamycin eye drop each hourly on basis of findings in KOH mount.

## 3. Discussion

Fungal infections of the cornea present as suppurative, usually ulcerative, lesions. they poses a challenge to the ophthalmologist because of its tendency to mimic other types of stromal inflammation, and because its management is restricted by the availability of effective antifungal agents and the extent to which they can penetrate into corneal tissue<sup>11</sup>. Mainly in the cases of mycotic corneal ulcers, *Curvularia* is the most common oculomycosis<sup>4,5,12</sup> which is isolated in ocular traumas especially when the trauma is due to wooden or plant materials. Depending upon microscopic morphological characters, *Curvularia* species was differentiated from *Alternaria*<sup>13,14,15</sup> species and *Fusarium* species<sup>13,14</sup>. *Curvularia geniculata* and *C. lunata* are encountered to be the most common causative organisms of oculomycosis among *Curvularia* species<sup>16</sup>. Considering fungus as a possible cause of infectious keratitis is important because devastating ocular damage can result if it is not diagnosed and treated promptly and effectively. Apart from keratomycosis, *Curvularia* is known to cause, sinusitis, onychomycosis, phaeohyphomycosis, eumycetoma, etc<sup>17,18</sup>. However, if proper aseptic precautions are not taken while inoculating and incubating the medias at appropriate

temperatures this species is found to be the most common laboratory media contaminant<sup>15,16</sup>. The routine laboratory diagnosis on the basis of macroscopic and microscopic features are enough for patient's medical treatment management as soon as possible. With conventional methods immunodiagnosis<sup>16</sup>, molecular techniques and animal pathogenicity can also be used for the diagnosis of oculomycosis. As it is the most common laboratory contaminant, it is required to maintain the aseptic measures and identify them on the basis of microscopic characteristics which can help us in the diagnosis of *Curvularia* as a cause of oculomycosis.

Hence Early diagnosis is necessary for treatment of corneal ulcers. Whenever there is suspicion of fungal etiology, ophthalmologists should avoid use of steroids and antibiotics as delayed diagnosis and mis treatment of mycotic ulcers can lead to blindness. While diagnosing such infections proper precautions like aseptic inoculation and incubation of culture media at appropriate temperatures should be taken to avoid contaminant growth.

## References

- [1] John P. Whitcher et al. *Corneal blindness: a global perspective* Bulletin of the World Health Organization 2001;79(3): 214-221.
- [2] Gabrielle Weiner. *Confronting Corneal Ulcers*. *Eye net* July 2012 ;44-52.
- [3] Jagdish chander *Textbook of medical mycology* 3<sup>rd</sup> edition. New Delhi: Mehta publisher; 2009; p.400-417.
- [4] Jones BR, Richards AB, Morgan G. Direct fungal infections of the eye in Britain. *Trans Ophthalmol Soc U K* 1969;89:727-741.
- [5] Forster RK, Rebell G, Wilson LA. Dematiaceous fungal keratitis. Clinical isolates and management. *Br J Ophthalmol* 1975;59:372-376.
- [6] Jones DB. Strategy for the initial management of suspected micro- bial keratitis. In: Barraquer J, Binder PS, Buxton JN, et al, eds. *Transactions of the New Orleans Academy of Ophthalmology. Symposium on Medical and Surgical Diseases of the Cornea*. St Louis, Mo: CV Mosby; 1980:86-119.
- [7] Schell WA. Oculomycoses caused by dematiaceous fungi. *Proceedings of the VI International Conference on the Mycoses*. Scientific publication No. 479. Washington, DC: Pan American Health Organization; 1986:105-109.
- [8] Zapater RC. Keratomycoses caused by dematiaceous fungi. *Proceedings of the Fifth International Conference on the Mycoses*. Scientific Publication No. 396. Washington, DC: American Health Organization; 1980:82-87.
- [9] Kirk R, Wilhelmus, Dan B. Jones, *Curvularia Keratitis*. *Tr Am Ophth Soc* 2001;99:111-132
- [10] Jagdish chander *Textbook of medical mycology* 3<sup>rd</sup> edition. New Delhi: Mehta publisher; 2009. P.401.
- [11] PA Thomas, *Fungal infections of cornea*. *Eye* (2003) 17,852-862
- [12] Jack J Kanski, *Orbit, textbook of Clinical Ophthalmology*, 7th edition, pg: 91.
- [13] Conat, Smith, Baker and Callaway, pg: 686-690.
- [14] Hazen, Gordon and Reed, pg: 184-194.

- [15] Wilson and Plunkett, pg: 382-384.
- [16] Jagdish Chander, Oculomycosis, textbook of Medical Mycology, 3rd edition, Mehata publishers, August, 2012, pg: 400-417.
- [17] Yau YCW, de Nanassy J, Summerbell RC, et al. Fungal sternal wound infection due to *Curvularia lunata* in a neonate with congenital heart disease: Case report and review. *Clin Infect Dis* 1994;19:735-740.
- [18] Fernandez M, Noyola DE, Rossmann SN, et al. Cutaneous phaeohyphomycosis caused by *Curvularia lunata* and a review of *Curvularia* infections in pediatrics. *Pediatr Infect Dis J* 1999;18:727-731.

