

Conservative Management of Osteoradionecrosis By Debridement, Sequestrectomy and Placement of An Obturator – A Clinical Report

Dr. V. Suresh, MDS¹, Dr. R. Sathya Narayanan, MDS², Dr. Beena Agnes Therese, BDS³

¹Department of Oral & Maxillofacial Surgery, Indira Gandhi Institute of Dental Sciences, Mahathma Gandhi Medical College Campus, Puducherry, India

Abstract: Osteoradionecrosis is defined as an exposed irradiated bone that fails to heal over a period of three months without a residual or recurrent tumor. The risk factors for the development of ORN includes dose or radiation (> 50-60Gy), radiation area, patients with poor oral hygiene, recent dental extraction, malnutrition, immuno compromised status. The management of osteoradionecrosis varies from more conservative approach to the aggressive treatment modalities. In this clinical report we present a case of stage I osteoradionecrosis who underwent conservative management with obturator which shows excellent results.

Keywords: mandible, osteoradionecrosis, radiotherapy, Head and neck neoplasm, Obturator

1. Introduction

Head and neck cancers are on the rise in recent times. In India, Head and Neck cancers account for 30 % of all cancers of which 60% to 80% present with advanced stage of the disease [1]. The management of head and neck cancers has also shown much advancement in terms of the surgical techniques employed and the chemo and radiation therapy techniques for locoregional control of head and neck cancer. Radiation therapy is used as the primary modality for treatment of early stage lesions and as adjuvant to surgical management for lesions in the advanced stage or when the margins are not free of tumor cells.

The different tissues in the body have different levels of sensitivity to radiation treatment. There are both acute and chronic complications resulting from the radiation therapy, one of which is osteoradionecrosis. The average time period for the development of osteoradionecrosis following exposure to radiation ranges from 22 to 47 months [2,3,4]. The mandible is more susceptible for the development of osteoradionecrosis due to its comparatively lesser blood supply, its mineralized nature that absorbs more radiation and its inclusion in the site of exposure for most of the oropharyngeal lesions [5]. Of late preventive measures undertaken meticulously, like extraction of teeth with poor prognosis 2 to 3 weeks before the initiation of radiation therapy, oral prophylaxis, avoidance of alcohol and tobacco, and Intensity modulated radiation therapy have significantly reduced the incidence of osteoradionecrosis.

According to the classification by Schwartz and Kagan [6], Stage I includes involvement of the superficial cortical bone, Stage II includes involvement of both cortical and medullary bone and Stage III includes involvement of the lower border. Once a diagnosis of Osteoradionecrosis is made from the history, clinical signs and radiographic features, the management depends on the level of involvement of the bone. For Stages I and II, preventive measures along with some conservative management like a combination therapy of Pentoxifylline-Tocopherol-Clodronate [7], Hyperbaric

Oxygen therapy [8], Ultrasound [9], superficial sequestrectomy [5] can be employed. For stage III, extensive resection and reconstruction is indicated. In patients with Stage I lesion, a definitive surgical management is often unnecessary and if the necrosed fragments are discernible, debridement can be done and the exposed bone cavity protected to allow unhindered healing. A series of patients who reported at our institution who were diagnosed with Stage I Osteoradionecrosis and who were considered appropriate for conservative management were managed with superficial debridement of the sequestrum following which the exposed bone was protected using an obturator. The following is a report of a case that showed excellent results following management by conservative therapy.

2. Clinical Report

A 65 year old man reported with the chief complaint of pain in relation to the right anterior region of his lower jaw for seven days. He was apparently normal when he had undergone extraction lower right anterior teeth since when he had complaints of pain and pus discharge from the extracted socket (Fig 1). His history revealed that he had had a carcinoma of his right buccal mucosa before 10 years for which he had undergone surgery followed by radiation therapy. The patient has been having a habit of betel nut chewing since his childhood with the frequency of 6 to 7 times per day. Intraoral examination revealed that the buccal mucosa on the right side appeared pale and pus discharge was present from the extracted socket. On palpation tenderness was present in the lower right vestibular region. The gingiva was reddish in colour, edematous and soft in consistency. An OPG was taken which showed characteristic mixed radiolucency and radioopacity indicating presence of predominant osteolytic activity (Fig 2). Since only the dentoalveolar segment was involved, indicating a Schwartz Stage I lesion, conservative management by superficial sequestrectomy was planned. Under naso endotracheal intubation, general anesthesia was administered and under strict aseptic precautions, surgical site was prepared with povidone iodine solution. Through

intraoral lower vestibular incision from right mandibular central incisor to molar region, a mucoperiosteal flap was elevated. The sequestrum and necrosed bone fragments were gently removed (Fig 3). The wound was irrigated with povidone iodine solution and saline and any possible approximation of the overlying tissues was done. In the immediate postoperative period, the exposed bone was protected using medicated gauze pack. One week later, intraoral impression was taken and an acrylic obturator was fabricated, appropriately designed to minimize irritation at the site of the lesion (Fig 4). The obturator served the triple purpose of protection of the exposed bone, adequate functional rehabilitation and improvement of patient comfort. The follow up visits showed satisfactory healing with no untoward complications like infection and recurrence (Fig 5).

3. Discussion

Osteoradionecrosis was first described in 1922 by Regaud. It has been defined as “An area greater than 1 cm of exposed bone in a field of irradiation that had failed to show any evidence of healing for at least 6 months”^[10] and “an ulceration of the mucous membrane with exposure of necrotic bone”^[11]. The process of sequestration that occurs during Osteoradionecrosis is in reality a defense response that walls off the infected area and results in the separation of the necrosed bone or sequestrum. At times there is a possibility that the presence of these necrosed fragments at the site of the already hypovascular lesion can further impair wound healing^[10]. It is believed that the removal of sequestra promotes healing by secondary intention^[12,13]. In a study of 104 cases of Osteoradionecrosis by Johnson RP et al^[14], it was found that resolution of 44 cases occurred by conservative management alone. It was found that local wound care until mucosal coverage occurs and a superficial sequestrectomy is sufficient enough treatment for osteoradionecrosis. Beumer J et al^[15], have also reported complete resolution and wound healing following treatment debridement and removal of sequestra. Traditionally gauze packs have been used to protect the exposed bone cavity, sometimes medications are added to these gauze packs. Morton and Simpson^[16], advocated these gauze packs and they found gauze packs soaked in Bismuth and iodoform paraffin paste to effectively maintain a clean bone cavity. But these gauze packs, efficient as they are, require meticulous care to replace them at regular intervals and also necessitate good cooperation from the patients to keep up regular appointments. As a result, for the cases that underwent conservative treatment in the form of debridement and removal of sequestrum, the bone cavity was protected using an acrylic obturator, fabricated one week after the necrosed fragments were removed. The follow up visits showed positive results in the form of satisfactory wound healing, improved patient comfort and better rehabilitation. In patients with malignancy who have already been through major surgical procedures and radiation treatment regimens, when possible, the conservative management described above, in terms of debridement, sequestrectomy and placement of an obturator placement affords considerable relief and also ensures satisfactory results.

The authors have no potential conflicts of interest. An informed consent in the local vernacular language was obtained from the patients included in the report.

4. Conflict of Interest

The Authors (Dr. V. Suresh, Dr. R. Sathyanarayanan, Dr. Beena Agnes Therese) Have No Potential Conflicts Of Interest.

References

- [1] Manik Rao Kulkarni. Head and Neck cancer burden in India. *International Journal of Head and Neck Surgery*. 2013 Apr;4(1):29–35.
- [2] Lee IJ, Woong SK, Chang GL, et al. Risk factors and dose-effect relationship for mandibular osteoradionecrosis in oral and oropharyngeal cancer. *J Radiat Oncol Biol Phys*. 2009;75(4):1084–91.
- [3] Oh HK, Chambers M, Martin J, et al. Osteoradionecrosis of the mandible: treatment outcomes and factors influences the progress of osteoradionecrosis. *J Oral Maxillofac Surg*. 2009;67:1378–86.
- [4] Store G, Boysen M. Mandibular osteoradionecrosis clinical behavior and diagnostic aspects. *Clin Otolaryngol Allied Sci*. 2000;25(5):375–84.
- [5] O’Dell K, Sinha U. Osteoradionecrosis. *Oral Maxillofac Surg Clin N Am*. 2011 Aug;23(3):455–64.
- [6] Schwartz HC, Kagan AR. Osteoradionecrosis of the mandible: scientific basis for clinical staging. *Am J Clin Oncol*. 2002;25(2):168–71.
- [7] Mcleod NMH, Pratt CA, Mellor TK, Brennan PA. Pentoxifylline and tocopherol in the management of patients with osteoradionecrosis, the Portsmouth experience. *Br J Oral Maxillofac Surg*. 2012 Jan;50(1):41–4.
- [8] Harding S, Courtney D, Hodder S, Bryson P. Effects of Hyperbaric Oxygen Therapy on Quality of Life in Maxillofacial Patients With Type III Osteoradionecrosis. *J Oral Maxillofac Surg*. 2012 Dec;70(12):2786–92.
- [9] Reher P, Harris M. Ultrasound for the treatment of osteoradionecrosis. *J Oral Maxillofac Surg*. 1997;55(10):1193–4.
- [10] Marx RE. A new concept in the treatment of osteoradionecrosis. *J Oral Maxillofac Surg*. 1983;41:351–7.
- [11] Epstein JB, Wong FL, Dickens A, Szasz I, Lepawsky M. Bone and gallium scans in postradiotherapy osteonecrosis of the jaw 1992;14:288–92. *Head Neck*. 1992;14:288–92.
- [12] Rankow RM, Weissman B. Osteoradionecrosis of the mandible. *Annals of Otolaryngology*. 1971;80:603–11.
- [13] Harris M. The conservative management of osteoradionecrosis of the mandible with ultrasound therapy. *Br J Oral Maxillofac Surg*. 1992;30:313–8.
- [14] Johnson RP. Osteoradionecrosis of the jaws: a retrospective study of the background factors and treatment in 104 cases. *J Oral Maxillofac Surg*. 1997;55(6):545–6.

- [15] Beumer J 3rd et al. Preradiation dental extractions and the incidence of bone necrosis. *Head Neck Surg.* 1983;5:514-21.
- [16] Morton ME, Simpson W. The management of osteoradionecrosis of the jaws. *Br J Oral Maxillofac Surg.* 1986;24:332-41.

Fig 1: Exposed necrotic bone with pus discharge

Fig 2: OPG shows extracted socket with necrotic bone

Fig 3: Intra operative picture showing removal of necrotic bone

Fig 4: Placement of an acrylic obturator

Fig 5: postoperative healed area.

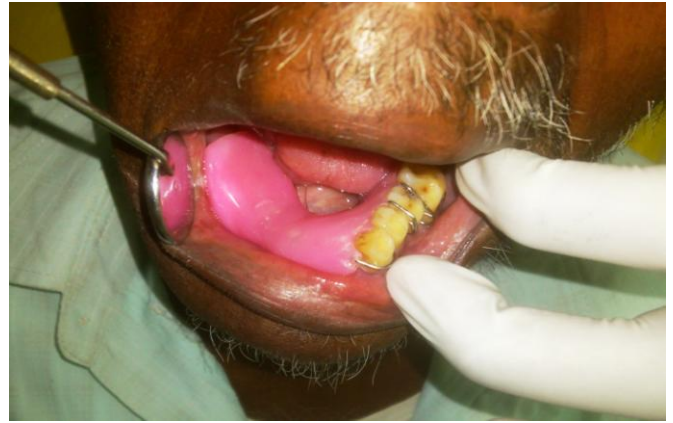

Figure 4

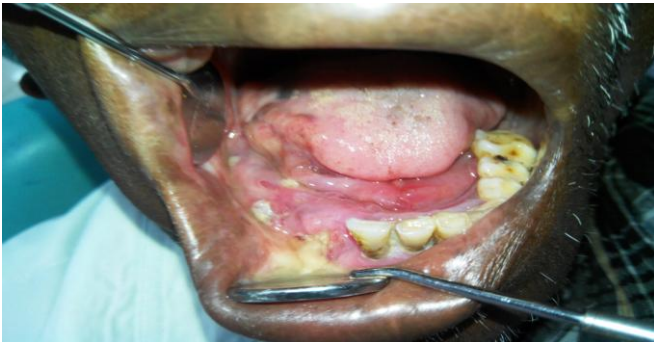

Figure 1

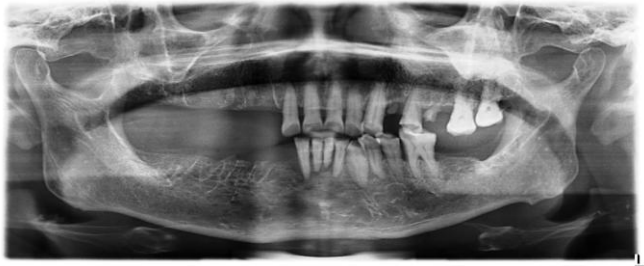

Figure 2

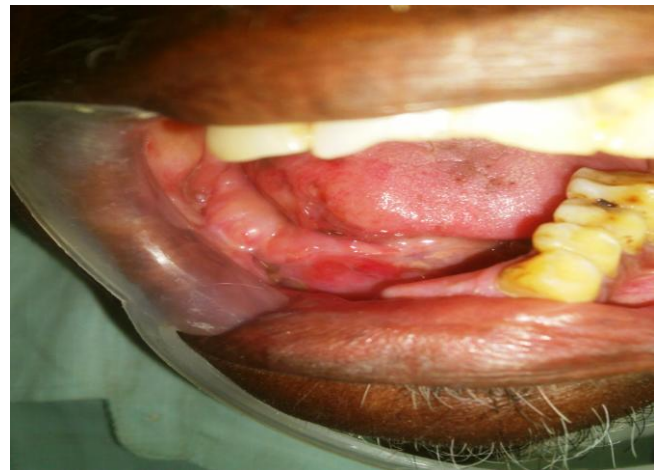


Figure 5

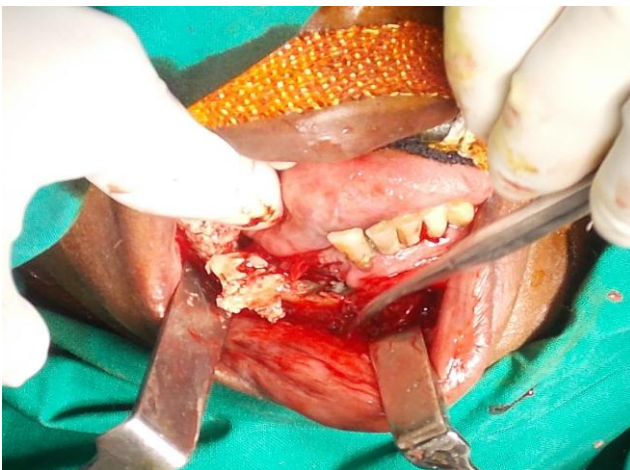

Figure 3