

# In Vivo Analysis of Some Key Characteristics of the Apical Zone in Teeth with Chronic Apical Periodontitis

Gusiyska A.

Department of Conservative dentistry, Faculty of Dental Medicine, Medical University-Sofia, Bulgaria

**Abstract:** *The pathogenesis of internal and external resorptive processes in the dental tissues and those of the periapical zone is not fully understood, but the main purpose, either in teeth with internal resorption or in teeth with periapical lesions, is decontamination of the endodontic space and subsequent three-dimensional obturation in order to isolate periapical and oral tissues and prevent reinfection. Since the target of this work were teeth with CAP, in the majority of the cases with clinical findings of root canals with preexisting filling, radicular pins, obliteration, separated canal instruments, perforations at different levels, via falsa or thresholds, the access to the apical zone was not subjected to a closely observed instrumental clinical protocol. In the treatment of each case, however, the clinical principles of modern endodontic treatment were closely observed.*

**Keywords:** apical zone, apical width, chronic apical periodontitis, external apical resorption, hard tissue resorption

## 1. Introduction

One of the main principles of orthograde endodontic treatment of teeth with chronic apical periodontitis (CAP) is to achieve a three-dimensional obturation of the root canal space, with accentuated attention to the obturation of the apical third. The achievement of maximum sealing of the apical zone is much more predictive in the presence of an apical narrowing and the possibility of preparing an apical stop [1, 2, 3, 4].

Only a few decades ago, the treatment of apical resorption-complicated teeth was carried out through conventional obturation techniques, while the planning of an apical surgery, immediately after filling the root canal, was a part of the standard treatment protocol. The lack of a physiological constriction leads to overpressing of the sealer or gutta-percha, which in 62-89% of the cases, affects adversely or delays significantly the healing process [5, 6, 7]. In a large percentage of cases, the presence of a foreign body in the periapical zone is accompanied by clinical symptoms and thereby, apical surgery and retrograde obturation of the root canal are indicated. Despite the need for such interventions, these may lead to several disadvantages, such as: a) problems with the retrograde sealing; b) postoperative bacterial invasion; c) percolation; d) availability of cut dentinal canals that may lead to the maintenance of a chronic persistent infection within the apparently sealed endodontic space, dentinal microtubular system and periapical tissues.

The pathogenesis of internal and external resorptive processes in the dental tissues and those of the periapical zone is not fully understood, but the main purpose, either in teeth with internal resorption or in teeth with periapical lesions, is decontamination of the endodontic space and subsequent three-dimensional obturation in order to isolate periapical and oral tissues and prevent reinfection. Because

of the asymptomatic course of these processes, the destruction may involve much of the tissue prior to the radiographic diagnosis. Clinical cases with similar findings in the dental tissues are challenging with regard to decontamination of the dentinal microtubular system, influence on the destructive processes on the external apical root surface, sealing of the open apex and achieving a three-dimensional obturation.

## 2. Material and Methods

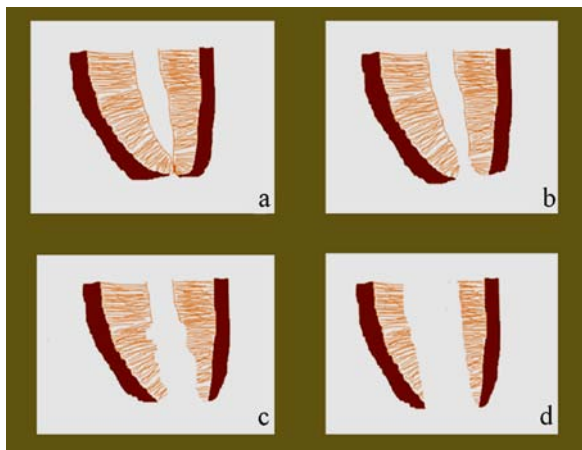
Our objective was to clarify some of the aspects in handling the apical zone, as a part of the first stage of decontamination. To realize this purpose, the working width of the apical narrowing was clinically determined. To facilitate the clinical protocol after the radiographic analysis and assessment of patency, the working lengths of 153 root canals (n = 153) in 106 teeth were determined. The clinical widths of the apical narrowing were measured by using the last instrument (ISO 0.02 tapered file), which can move freely through the apical narrowing after electrometric determination of the working length (Raypex 5 /VDW, Germany/). The measurements were allocated to groups, defined for the purposes of this study, as follows:

Group I: № **006-008** (initial obliteration of the apical zone) (Fig. 1a);

Group II: № **010-030** (physiological patency of the apical constriction) (Fig. 1b);

Group III: № **035-055** (physiological patency or initial resorption of the apical constriction and apical foramen) (Fig. 1c);

Group IV: № **060-140** (advanced apical resorption) (Fig. 1d).



**Figure 1.** Schematic presentation of the clinically established changes in the apical zone (a – I group, b – II group, c – III group, d – IV group)

The study was not aiming at examining the detailed anatomical shape of the apical narrowing, but after the analysis of all previous investigations in this zone, a clinical protocol was prepared for preparation of the apical zone, as the established parameters are of clinical significance for the three-dimensional preparation and subsequent three-dimensional sealing of the root canal. The radiographic analysis of the treatment outcomes for teeth with CAP, grouped into the four clinical groups, gave us reason to combine the two criteria, i.e. the radiographic criterion (according to Ørstavik) and the introduced clinical criterion for determining the apical constriction width [8]. From a clinical perspective, the width of the apical narrowing or its absence, combined with a pathological apical opening, is of crucial importance. In a radiographically diagnosed lesion with PAI5, the clinical approaches would be different for # 010 and # 070 (according to ISO) widths of the apical narrowing. This supports the allocation into four groups, since it complements the imaging features of the lesions with the clinical characteristics of the pathologically changed apical zone. Based on the combination of these two criteria, the type of the periapical lesion could be successfully determined that can be correlated and used to assess the degree of difficulty for the treatment of teeth with CAP, from type I periapical lesions with degree I difficulty to type IV periapical lesions with degree IV of difficulty. In accordance to the aforementioned criteria, the four types of periapical lesions are presented in Table 1.

### 3. Results and Discussion

After processing, the obtained results are plotted in Table 2, where the percentage ratios between the different groups are shown. Determination of working width and working length is important for realizing the first stage of decontamination – maximum instrumentation of the endodontic space and choice of a clinical protocol.

**Table 1:** Types of periapical lesions

	PAI 3	PAI 4	PAI 5
<b>I group</b> (ISO#006–008)	I Type	I Type	II Type
<b>II group</b> (ISO#010–030)	I Type	I Type	II Type
<b>III group</b> (ISO#035–055)	II Type	II Type	III Type
<b>IV group</b> (ISO#060–140)	III Type	III Type	<b>IV Type</b>

**Table 2:** Percentage distribution of clinical cases by type of lesion

n=164	PAI 3	PAI 4	PAI 5
<b>I group</b> (ISO#006–008)	I Type n=8 (4.87%)	I Type n=11 (6.7%)	II Type n=9 (5.48%)
<b>II group</b> (ISO#010–030)	I Type n=15 (9.14%)	I Type n=21 (12.80%)	II Type n=11 (6.7%)
<b>III group</b> (ISO#035–055)	II Type n=10 (6.09%)	III Type n=12 (7.31%)	III Type n=11 (6.7%)
<b>IV group</b> (ISO#060–140)	III Type n=4 (2.43%)	III Type n=8 (4.87%)	<b>IV Type</b> n=44 (26.82%)

The classification of root canals in a particular group according to the relative patency or lysed apical opening is important for the selection of obturation technique, which is essential for reducing the microleakage in the zone. The likelihood of an increased microleakage after obturation is proportional to the size of destruction of the apical foramen, as the preparation of the root canal space before obturation is also of importance [9]. The method of electrometry in the treatment of teeth with CAP and available (radiographically diagnosed or not) hard tissue resorption of varying degree in the apical zone does not provide accurate indicators on the root canal termination and the outset of periradicular tissues, i.e. periodontal ligament, bone, granulation tissue, cystic tissue. Being the first stage of decontamination, the exact instrumental preparation of the pulp chamber and the root canal provides an access to the endodontic space and is a prerequisite for achieving maximum results in the next stages.

The exact determination of the following parameters: curves and shape of the root canal and selection of a treatment technique and instruments, is of no less importance for the treatment of teeth with CAP.

For the precise condensation of gutta-percha and prevention of overpressing either of the gutta-percha or the sealer, which could injure the periradicular tissues, the presence of an apical stop (an apical control area) for groups I, II, III or an apical barrier for group IV is required [10].

While adhering to the principles of creating an apical stop, the instrumentation of the root canal space and the apical zone protects the periapical tissues and the anatomical narrowing from trauma and transportation. By applying this technique of preparation, it is possible to increase the size of the main apical file, which is a prerequisite for adequate removal of the infected microtubular dentine and maximum removal of invaded microorganisms, in consistency with the features of the root canal system, while avoiding the increased risk of over instrumentation in the apical zone. Clinical observations have shown that the increase in the size of the file applied last in the apical zone and the extension of the set conicity/taper substantially increase the volume of solution for irrigation, enhance debris evacuation to the maximum and minimize the need of creating an apical dentine stopper. The average statistical apical treatment of the root canal with file #40 (according to ISO) and taper 0.04 has been shown to

preserve hard dental tissues and provide maximum irrigation in the apical third, adequate distance between the needle and the root canal walls and a possibility for evacuation of the solution towards the orifice. This has been confirmed by a number of authors [11, 12, 13, 14, 15]. The apical level of processing and the volume that should be removed during root canal preparations in this area are the subject of much discussion [16, 17, 18, 15, 19]. Many modern machine Ni-Ti systems limit the processing area to a diameter of 250-300 µm, while avoiding the preparation in the zone of narrowing. This is due to technical considerations aiming at the creation of favorable conditions for obturation of the root canal system by applying warm condensation methods in order to avoid the extrusion of material in the case of a wider apical zone.

**Table 3:** Master apical file processing to stop at the apical teeth CAP compared to the group and root canal

Maxilla											
Group teeth	Incisors		Canines	Premolars				Molars			
	Centrals	Laterals		Single rooted		Multi rooted		P	DB	MB1	MB2
				oval canals	elliptical canals	B	P				
MAF*	ISO #40-80	ISO #35-50	ISO #50-80	ISO #30-40	ISO #45	ISO #35-40	ISO #35-50	ISO #40-60	ISO #35-40	ISO #35-40	ISO #30-35
Mandibula											
Group teeth	Incisors		Canines	Premolars				Molars			
	Single rooted	Two rooted		Single rooted		Multi rooted		D	ML	MB	
				oval canals	elliptical canals	B	L				
MAF*	ISO #30-40	ISO #35	ISO #40-60	ISO #40	ISO #45	ISO #35-40	ISO #35-50	ISO #35-60	ISO #35-40	ISO #35-40	

\*MAF – master apical file; B – buccal; P – palatal; L – lingual; D – distal; DB – distobuccal; MB1 – mesiobuccal 1; MB2 – mesiobuccal 2; ML – mesiolingual; MB – mesiobuccal

However, biological considerations indicate otherwise [16, 18, 15, 19]. The apical narrowing and the apical foramen are areas that favor the development of microorganisms and the accumulation of bacterial biofilm that can remain mechanically and chemically untreated upon limited preparation [17]. Moreover, the natural size of the apical narrowing (typically ≥250-300 µm to 600 µm) implies an extended apical preparation [20].

Based on the clinical observations and the analysis of late treatment outcomes of teeth with CAP and apical resorption, the average optimal criteria for selection of a primary apical file for apical stop preparation were determined in relation to the tooth and the root canal (Table 3).

#### 4. Conclusions

The design of instruments, hand or machine, is particularly important for the prevention of errors in root canal

instrumentation. Since the target of this work were teeth with CAP, in the majority of the cases with clinical findings of root canals with preexisting filling, radicular pins, obliteration, separated canal instruments, perforations at different levels, via falsa or thresholds, the access to the apical zone was not subjected to a closely observed instrumental clinical protocol. In the treatment of each case, however, the clinical principles of modern endodontic treatment were closely observed.

Studies have advocated using larger endodontic instruments to clean the apical zone. An appropriate master apical size can help the operator avoid unnecessary enlargement of the apex whereas predictably reducing intracanal debris.

## References

- [1] Le Geros RZ. Properties of osteoconductive biomaterials: calcium phosphates. *Clin Orthop Relat Res.* 2002;395:81-98.
- [2] Mäntylä P, Stenman M, Kinane DF, Tikanoja S, Luoto H, Salo T, et al. Gingival crevicular fluid collagenase-2 (MMP-8) test stick for chair-side monitoring of periodontitis. *J Periodont Res.* 2003;38:436-439.
- [3] Scarfe WC, Farman AG, Sukovic P. Clinical applications of cone-beam computed tomography in dental practice. *J Can Dent Assoc.* 2006;72:75-80.
- [4] Wang CY, Stashenko P. Characterization of bone-resorbing activity in human periapical lesions. *J Endod.* 1993 19;Mar (3):107-11.
- [5] Friedman S. Considerations and concepts of case selection in the management of post-treatment endodontic disease (treatment failures). *Endod Topics.* 2002;1(1):54-78.
- [6] Neville BW, Damm DD, Allen CM, Bouquot JE. *Oral & Maxillofacial Pathology.* (Philadelphia, USA) W. B. Saunders Co, 2002;107-136;589-601.
- [7] Seltzer S. *Endodontology.* 2-nd ed. Philadelphia: Lea & Febiger. 1988;444-6.
- [8] Gusiyska A. Orthograd treatment of chronic apical periodontitis – biological approach. [Dissertation]. Faculty of Dental Medicine, Sofia; 2012. 254 p.
- [9] Grootvelt M, Baysan A, Siddiqui N, Sim J, Silwood C, Lynch E. History of clinical applications of ozone. – In: Lynch E. *Ozone: the revolution in dentistry.* Quintessence. 2004; Chapter 1.2.
- [10] Murugan R, Ramakrishna S. Development of cell-responsive nanophase hydroxyapatite for tissue engineering. *Am J Biochem Biotech.* 2007;3(3):118-124.
- [11] Boutsoukis C, Verhaagen B, Versluis M, Kastrinakis E, Wesselink P, Van der Sluis LWM. The effect of apical preparation size on irrigant flow in root canals evaluated using an unsteady Computational Fluid Dynamics model. *Int Endod J.* 2010;10:874-81.
- [12] Brunson M, Heilborn C, Johnson DJ, Cohenca N. Effect of apical preparation size and preparation taper on irrigant volume delivered by using negative pressure irrigation system. *J Endod.* 2010;36(4):721-724.
- [13] Camões IC, Salles MR, Chevitarrese O. Ca<sup>2+</sup> diffusion through dentin of Ca(OH)<sub>2</sub> associated with seven different vehicles. *J Endod.* 2003;29(12):822-5.
- [14] Ørstavik D, Kerekes K, Eriksen HM. The periapical index: a scoring system for radiographic assessment of apical periodontitis. *Endod Dent Traumatol.* 1986;2:20-34.
- [15] Souza-Filho FJ, Soares A, Vianna M, Zaia A, Ferraz C, Gomes B. Antimicrobial effect and pH of chlorhexidine gel and calcium hydroxide alone and associated with other materials. *Braz Dent J.* 2008;19(1):28-33.
- [16] Card SJ, Sigurdsson A, Ørstavik D, Trope M. The effectiveness of increased apical enlargement in reducing intracanal bacteria. *J Endod.* 2002;28(11):779-783.
- [17] Nair PNR, Sjögren U, Krey G, Kahnberg KE, Sundqvist G. Intraradicular bacteria and fungi in root filled asymptomatic human teeth with therapy resistant periapical lesions: a long term light and electron microscope follow-up study. *J Endod.* 1990;16:580-588.
- [18] Peters LB, Wesselink PR, van Winkelhoff AJ. Combinations of bacterial species in endodontic infections. *Int Endod J.* 2002;35:698-702.
- [19] Vier F, Figueiredo J. Prevalence of different periapical lesions associated with human teeth and their correlation with the presence and extension of apical external root resorption. *Int Endod J.* 2002;35:710-719.
- [20] Briseño-Marroquin B, El-Syed MAA, Willershausen-Zonnchen B. Morphology of the physiological foramen: I. Maxillary and mandibular molars. *J Endod.* 2004 May;30(5):321-8.

## Address for Correspondence

Dr Angela Gusiyska, PhD

Department of Conservative Dentistry, Faculty of Dental Medicine

1, St. George Sofiiski Str., 1431 Sofia, Bulgaria

E-mail: gusiyska@yahoo.com

## Author Profile



**Dr. Angela Gusiyska** received her degree in Dentistry (Dr. med. Dent) from the Faculty of Dental Medicine, Medical University of Sofia, Bulgaria in 1997 and she specialized in Operative Dentistry and Endodontics at the same University in 2003. Since 1998 she is Assistant Professor at the Department of Conservative Dentistry, FDM – Medical University, Sofia. Her research interests are in the area of regeneration of periapical zone, nanotechnology and bioceramics in endodontics and esthetic rehabilitation of dentition. Dr. Gusiyska presents her scientific papers on national and international dental meetings. Her practice is focused on microscopic endodontic treatments. She developed her PhD thesis titled “Orthograde Treatment of Chronic Apical Periodontics – Biological Approaches: in 2011. She is currently a member of the Bulgarian Dental Association, Bulgarian Scientific Dental Association, Bulgarian Endodontic Society, Bulgarian Society of Aesthetic Dentistry, International Team for Implantology, Bulgarian Society of Oral Implantology.