

The Study of Anatomical Variation of the Prevalence and Agenesis of Palmaris Longus Muscle in Medical Students in an Indian Medical College

Anant Sachan¹, Rajkumar²

¹Lecturer in S.M.M.H. Medical College, Saharanpur, U.P., India

²Lecturer in Govt. Medical College, Jalaun, U.P., India

Abstract: *Palmaris Longus Muscle is one of the most variable muscles in the human body (Brones & Wilgis, 1978) in the concern of presence and absence. Palmaris longus (PL) muscle, although of little functional use to the human upper limb, assumes great importance when used as a donor tendon for transfer or transplantor grafting .It is The most desirable tendons in reconstructive surgery. In the present study, 500 Medical students (210 males and 290 females) of different ages from Teerthankar Mahaveer Medical College & Research Centre, Moradabad were examined for the presence or absence of the PL tendon, using the conventional four tests are following, Schaeffer's test, Thompson's test, Mishra's test, Pushpakumakar's two finger sign method. PL agenesis was further analyzed statistically for differences in the prevalence and agenesis of PL with regard to sex and body side. I was observed the 290 females, the palmaris longus muscle is present in 72.06% (n=209) of the total population. Bilateral absence of the muscle is found in 18.96% (n=55) of the sample. Unilateral absence on the left side was found in 5.86% (n=17) of the cases and on the right side in 3.10% (n=9) of the cases and 210 males, 97.61% (n=205) had the palmaris longus muscle on both the left and the right sides. In the sample population, 0.47% (n=1) had bilateral absence of palmaris longus. The muscle was absent on the left side in 0.95% (n=2) of the cases and on the right side in 0.95% (n=2) of the cases.*

Keywords: Prevalence; Agenesis; Palmaris longus

1. Introduction

The palmaris longus muscle has been well studied following the first report of its absence in 1559 by Colombos in *De Re Anatomica Libri* (Schaeffer, 1909; Thompson *et al.*, 2001). It is one of the most variable muscles in the human body (Brones & Wilgis, 1978). It varies in the incidence of its absence, form, attachment, duplication and its ability of having accessory slips and substitute structures (Reimann *et al.*, 1944). The palmaris longus muscle is a slender, fusiform shaped muscle arising from the common flexor origin of the medial epicondyle of the humerus, passing between the flexor carpi radialis and flexor carpi ulnaris muscles, it ends as a slender, flattened tendon passing superficially over the transverse carpal ligament and inserting into the palmar aponeurosis (Roohi *et al.*, 2007). The action of the palmaris longus muscle is weakly flex the wrist and tense the palmar aponeurosis, synergized by flexor carpi radialis, flexor carpi ulnaris and flexor digitorum superficialis muscles. It is supplied by the median nerve. The muscle belly of palmaris longus is supplied by a small branch from anterior ulnar recurrent artery.

2. Material & Methods

To determine the prevalence of the palmaris longus muscle, 500 Medical students are randomly selected from various age groups at Teerthankar Mahaveer Medical College & Research Centre, Moradabad. There are four tests performed with every subject for examining the presence or absence of palmaris longus muscle. The name of four tests are following, Schaeffer's test, Thompson's test, Mishra's

first test, Pushpakumakar's two finger sign method. The Schaeffer's test is the standard test for determining the presence or absence of palmaris longus muscle and rest three tests are supportive tests.

Schaeffer's Test: Schaeffer's test is used in order to visualize or palpate the palmaris longus tendon. Participants are asked to oppose their thumb and little finger with slight flexion of the wrist. If the palmaris longus tendon is present, it would be visible at the distal aspect of the forearm (see figure 1).

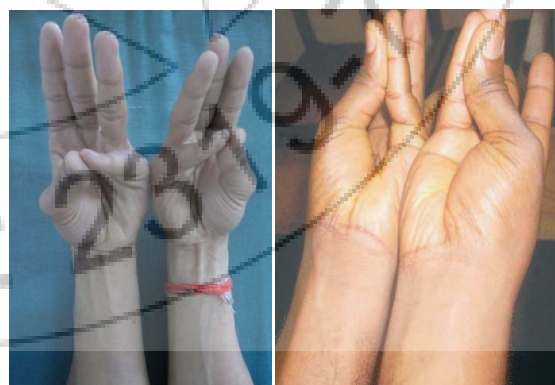

Figure 1: Schaeffer's test, in the left figure The individual have both the palmaris longus muscles and in the right figure the individual has none.

Thompson's test: It involves flexion of the fingers to form a fist followed by flexion of the wrist and finally the thumb is opposed and flexed over the fingers (see figure 2).

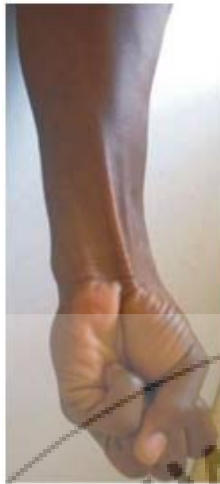


Figure 2: Thompson's (1921) technique for assessing PL.

Mishra's Test: It involves passive hyperextension of the metacarpophalangeal joints followed by resisted active flexion at the wrist (see figure 3).

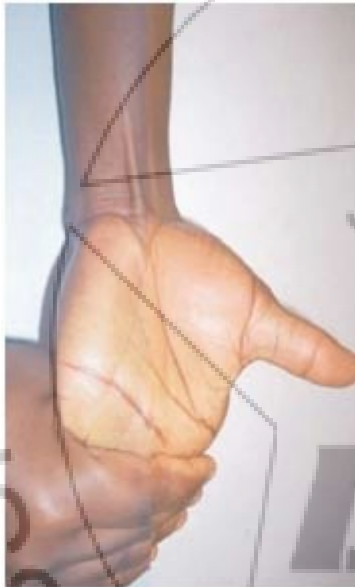


Figure 3: Mishra's (2001) first test for demonstrating PL.

Pushpakumakar's test: It involves extension of the index and middle finger with flexion of the other fingers and the wrist followed by opposition and flexion of the thumb (see figure 4).

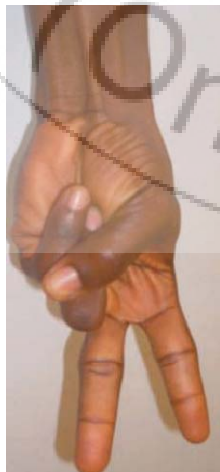

Figure 4: Pushpakumakar's (2004) two finger sign method.

3. Statistical Analysis

The result of observation will be statistically calculated with the help of following formula.

Formula:-

$$\text{Mean} = \frac{\sum X}{n}$$

$\sum X$ = Sum of observations

n = total no. of observations

4. Result

In the sample of 210 males, 97.61% ($n=205$) had the palmaris longus muscle on both the left and the right sides. In the sample population, 0.47% ($n=1$) had bilateral absence of palmaris longus. The muscle was absent on the left side in 0.95% ($n=2$) of the cases and on the right side in 0.95% ($n=2$) of the cases.

For the 290 females, the palmaris longus muscle is present in 72.06% ($n=209$) of the total population. Bilateral absence of the muscle is found in 18.96% ($n=55$) of the sample. Unilateral absence on the left side was found in 5.86% ($n=17$) of the cases and on the right side in 3.10% ($n=9$) of the cases.

The prevalence of the palmaris longus muscle is summarized in table.

Table No. 1 showing the prevalence and agenesis of PL with regard to sex and body side.

Table 1: Current study of palmaris longus muscle

Sex	Male	Female	Total
Subject	210 (41.92%)	290 (58.07%)	500 (100%)
Absent in Both Hand	1 (0.47%)	55 (18.96%)	56 (11.20%)
Absent in Left Hand	2 (0.95%)	17 (5.87%)	19 (3.80%)
Absent in Right	2 (0.95%)	9 (3.10%)	11 (2.20%)
Present in Both Hand	205 (97.61%)	209 (72.06%)	414 (82.80%)

5. Discussion

A bilateral absence of the palmaris longus was noted in 8.3% of cases, 3.6% was absent in the left arm only and 4.7% in the right arm only (Reimann *et al.*, 1944). A bilateral absence of 0.6% was recorded for a Zimbabwean population (Gangata, 2009) compared to the results obtained from a study done on an Amazon Indian population, which revealed a bilateral absence of 2.6% of this muscle (Machado *et al.*, 1967). Sebastin and co-workers (2005) reported on a study done on subjects of Asian descent and found a bilateral absence of 2%. Unilateral absence was found in 2.9% of the cases in the left arm and 1.2% in the right arm.

Schaffer's *et al* (1909) studied Caucasian subjects and reported a bilateral absence of 8.7% of the palmaris longus muscle. Unilateral absence of this muscle was noted in 6.7% of the left arm and 9.7% of the right arm. Wehbé and Mawr (1992) reported a bilateral absence of 5% in a sample made up of mainly Caucasian subjects. Another study done on

Caucasian subjects reported a bilateral absence of 9.7% of the palmaris longus muscle. This muscle was absent in the right arm only (2.2%) (Vanderhooft, 1996).

Kapoor and co-workers (2008) studied the palmaris longus muscle in an Indian population and found a bilateral absence

of 17.2%; unilateral absence consisted of 6.2% on the left side and 3% on the right side. The author noted that the method used was not entirely reliable and therefore a weak tendon could be mistaken for an absent tendon. The findings from the above studies are summarized in Table 2.

Table 2: Prevalence of the palmaris longus muscle, a comparison between the different studies found in the earlier study.

Author	Total sample	Present bilaterally		Absent bilaterally		Unilateral absence (left)		Unilateral absence(right) (right)	
		n	%	n	%	n	%	n	%
North American population (Reimann <i>et al.</i> , 1944)	362	302	83.4	30	8.3	13	3.6	17	4.7
Amazon Indian population (Machado & Di Dio, 1967)	379	-	-	10	2.6	-	-	-	-
North American population (Wehbé & Mawr, 1992)	120	-	-	6	5	-	-	-	-
North American population (Vanderhooft, 1996)	186	156	83.9	18	9.7	0	0	4	2.2
European population (Thompson <i>et al.</i> , 2002)	300	228	76	26	8.7	20	6.7	29	9.7
Asian population (Sebastin <i>et al.</i> , 2005)	418	394	94.3	7	2	12	2.9	5	1.2
Malaysian population (Roohi <i>et al.</i> , 2007)	450	-	-	13	2.9	-	-	-	-
Indian population (Kapoor <i>et al.</i> , 2008)	500	414	82.8	40	17.2	31	6.2	15	3
Iranian population (Mobarakeh <i>et al.</i> , 2008)	64	-	-	5	7.8	-	-	-	-
Nigerian population (Oluyemi <i>et al.</i> , 2008)	600	188	31.3	112	18.75	150	25	150	25
Southern Indian population (Pai <i>et al.</i> , 2008)	30	-	-	1	3.3	3	10	-	0
Zimbabwean population (Gangata, 2009)	890	-	-	5	0.6	-	-	-	-
Current study (Anant Sachan 2014)	500	414	82.8	56	11.2	19	3.8	11	2.2
Global prevalence (average %)	4799	-	41.11	-	7.23	-	4.47	-	3.69

Since the palmaris longus is an expendable muscle, its absence will not affect the function of the wrist significantly (Roohi *et al.*, 2007). However, the congenital absence of this muscle can be seen as a disadvantage when the use of this muscle is indicated for use in reconstructive surgery (White, 1960; Carlson *et al.*, 1993). The prevalence of the palmaris longus muscle has been shown to differ between various population groups (Roohi *et al.*, 2007).

Most of the literature only gives the bilateral absence of the palmaris longus muscle in a percentage value: 0.6% (Gangata, 2009), 2.6% (Machado *et al.*, 1967), 5% (Wehbé & Mawr, 1992), 13% (Sinnatamby, 1999), just to name a few. Other studies revealed the bilateral absence as well as the unilateral absence of the palmaris longus, whether it was on the left or right side. In such studies the bilateral absence varied from 2-18.75% (Vanderhooft, 1996; Thompson *et al.*, 2002; Sebastin *et al.*, 2005; Kapoor *et al.*, 2008; Oluyemi *et al.*, 2008). The absence of the palmaris longus muscle on the left side was reported to be 0-25%, and on the right side 1.2-25%, for the same studies.

If one should disregard population variation and combine the results of all the above-mentioned studies, where a total of 4799 subjects were examined, the results show that on average the palmaris longus is present in 41.11% (bilaterally), absent in 7.23% (bilaterally), absent on the left in 4.47% and on the right in 3.69% of people worldwide. Kapoor and co-workers (2008) supports this statement by stating that the palmaris longus muscle is not diminishing as fast in the Indian population as in other races.

6. Conclusion

In the present study the prevalence and agenesis of palmaris longus muscle, the females are more prone to Bilateral absence of the muscle (about 18.96%), Unilateral absence on the left side (about 5.86%) and on the right side in (about

3.10%) and present (about 72.06%) in the total population than male. Thus this is the most significant anatomical variation in the human body.

References

- [1] Brones, M. F. & Wilgis, E. F. Anatomical variations of the palmaris longus causing carpal tunnel syndrome. Case reports. *Plast. Reconstr. Surg.*, 62:798-800, 1978.
- [2] Schaeffer, J. P. On the variations of the palmaris longus muscle. *Anat. Rec.*, 3:275-8, 1909.
- [3] Thompson, N. W.; Mockford, B. F. & Cran, G. W. Absence of the palmaris longus muscle: a population study. *Ulster Med. J.*, 70:22-4, 2001.
- [4] Reimann AF, Daseler EH, Anson BJ and Beaton LE. 1944. The palmaris longus and tendon. A study of 1600 extremities. *Anat Rec* 89:495-505.
- [5] Roohi SA, Choon-Sian L, Shalimar A, Tan GH and Naicker AS. 2007. A Study on the Absence of Palmaris Longus in a Multi-racial Population. *M Ortho J* 1(1):26-28
- [6] Gangata H. 2009. The Clinical Surface Anatomy Anomalies of the Palmaris Longus Muscle in the Black African Population of Zimbabwe and a Proposed New Testing Technique. *Clin Anat* 22:230-235.
- [7] Machado ABM and Di Dio LJA. 1967. Frequency of the Musculus Palmaris Longus Studied in Vivo in some Amazon Indians. *Am J Phys. Anthropol* 27:11-20.
- [8] Sebastin SJ, Lim AYT, Bee WH, Wong TCM and Methil BV. 2005. Does the absence of the palmaris longus affect grip and pinch strength? *J Hand Surg* 30B:406-408.
- [9] Wehbé MA, and Mawr, B. 1992. Tendon graft donor sites. *J Hand Surg* 17A: 1130-2.
- [10] Vanderhooft E. 1996. The Frequency of and Relationship Between the Palmaris Longus Tendons. *Am J Orthop* 1:38-41.

- [11] Kapoor SK, Tiwari A, Kumar A, Bhatia R, Tantuway V and Kapoor S. 2008. Clinical relevance of palmaris longus agenesis: Common anatomical aberration. *Anat Sci Int* 83:45-8.
- [12] White WI. 1960. Tendon Grafts: A consideration of Their Source, Procurement and Suitability. *Surg Clin North Am* 40:403-13.
- [13] Sinnatamby CS. 1999. *Last's Anatomy: Regional and Applied*. 10th ed. Edinburgh: Churchill Livingstone.
- [14] Carlson GD, Botte MJ, Josephs MS, Newton PO, Davis JLW and Woo SLY. 1993. Morphologic and biomechanical comparison of tendons used as free grafts. *J Hand Surg* 18A:76-82.
- [15] Oluyemi KA, Adesanya OA, Odion BI and Ukwenya VO. 2008. Incidence of palmaris longus muscle absence in Nigerian population. *Int J Morphol* 6(2):305-308.
- [16] Mobarakeh MK, Pasha MG and Poor MM. 2008. Variation, Length and Width of Tendinous Portion of Palmaris Long us and Forearm Length and Height.
- [17] Pai MM, Prabhu LV, Nayak SR, Madhyastha S, Vadgaonkar R, Krishnamurthy A and Kumar A. 2008. The palmaris longus muscle: its anatomic variations and functional morphology *Rom J Morphol Embryol* 49(2):21 5-217.
- [18] Mishra, S. Alternative tests in demonstrating the presence of palmaris longus. *Indian J. Plast. Surg.*, 34:12, 2001.
- [19] Pushpakumar, S. B.; Hanson, R. P. & Carroll, S. The 'two finger' sign. Clinical examination of palmaris longus (PL) tendon. *Br. J. Plast. Surg.*, 57:184-5, 2004.

Author Profile

Anant Sachan is serving as lecturer in Department of Anatomy, S. M. M. H. Medical College, Saharanpur, 247001 (U.P.), India