

Surgical Banding for Congenital Porto-Systemic Shunt: How We Do It?

Sunil Kumawat¹, Shivang Saxena², Ashish Katewa³, Maruti Haranal⁴

^{1, 2, 3, 4}Department of Pediatric Cardiac Surgery, U N Mehta Institute of Cardiology and Research, Ahmedabad, India

Abstract: Congenital porto-systemic shunt with intrahepatic portal vein hypoplasia is a rare pathology often necessitating liver transplant. However, in a subset of patients, the hypoplastic intrahepatic portal veins can be encouraged to grow by banding the postsystemic shunt. We describe an innovative technique of banding the postsystemic shunt as the first step in the multi-staged treatment for this rare congenital anomaly.

Keywords: Banding, Congenital, Intrahepatic portal vein, Portosystemic shunt

1. Introduction

Congenital postsystemic shunt (CPSS) with intrahepatic portal venous (IHPV) hypoplasia is a rare pathology where the mesenteric venous blood bypass the liver and enters the systemic veins directly. The consequent metabolic derangement due to hepatic malperfusion and altered “first pass” effect has diverse life-threatening manifestations including Pulmonary hypertension, Hepato-pulmonary syndrome causing severe cyanosis, Hyperammonemia causing hepatic encephalopathy, manganese deposition in basal ganglia and hepatic tumours (1). Extrahepatic CPSS are classified into two types based on the absence or presence of intrahepatic portal veins (2). Type 1 CPSS with absent IHPV generally progress towards liver transplant and its antecedent complications (3). Symptomatic patients with Type 2 CPSS with adequate IHPV will require occlusion of the shunt. This can be performed either surgically or by percutaneous intervention. However, there is an intermediate type of CPSS, can also be classified as variant of Type 1 CPSS, with hypoplastic IHPV where liver transplant need not be the first choice of therapy. The diagnosis is made by balloon occlusion venography of the CPSS. The thin portal vein and a “smoke sign” in the liver are diagnostic of IHPV hypoplasia. If the mesenteric pressure is more than 24 mm Hg or the pre and post occlusion pressure gradient is more than 9 mm Hg, single stage occlusion of CPSS is contraindicated. (4, 7). The treatment is usually offered in two stages. During the first stage the CPSS is banded to encourage IHPV to enlarge. A repeat angiogram is performed 2 to 3 months later to demonstrate the growth of IHPV and to document the portal venous pressure of less than 24 mmHg after balloon occlusion of the CPSS. If the mesenteric venous pressure is lower than 24 mm Hg, the shunt can be occluded completely.

Technique

Preoperative diagnosis with computed tomographic imaging, abdominal doppler and selective portal venography, and manometry pre and post-test occlusion is mandatory. The access was through right subcostal laparotomy. The right ascending colon and second part of duodenum were mobilised using extended Kocher’s maneuver. The inferior vena cava was exposed and the left renal vein was traced. The CPSS was immediately above the left renal vein and could be identified easily (Figure 1). The CPSS was looped with a silastic sling. A pressure monitoring catheter was cited in the

CPSS. The baseline pressure in the mesenteric veins was 8 mm Hg. Next, the CPSS was completely occluded and the distal pressure increased to 32 mm Hg with a pre and post occlusion gradient of 24 mm Hg. This was not tenable with the gut survival and it was decided to band the shunt. A 5mm size expanded Poly Tetra Fluoro Ethylene tube graft (e-PTFE) was opened longitudinally. The CPSS was encircled with this graft. The cut segment is passed around the CPSS and then sutured end-to-end with 5-0 prolene suture, thus creating a band of approximately 4mm width around the shunt (Figure 2). Post banding, needle pressure was 22 mm Hg. Though the pre and post occlusion gradient was 14mmHg, the absolute pressure was less than 24mm Hg and the bowel appeared healthy, it was decided to accept the band at 4mm diameter. The abdomen was packed with warm mops for 10 minutes and the bowel was reassessed for any colour changes and oedema. Any lymphatic Leakes are carefully sought and cauterized to prevent chylo-peritonium. The abdomen was closed in layers without a drain.

Postoperative management Protocol:

The patient is kept fasting for at least 24 hours or till the return of peristalsis. The abdominal girth is monitored for any signs of intestinal obstruction. Systemic heparin is given for 7 days and titrated to maintain activated partial thromboplastin clotting time (APPT) between 80 to 100 seconds to prevent mesenteric vein thrombosis. Thrombosis of mesenteric veins is a known complication precipitated by high hematocrit and stasis imposed by the band. Venous doppler examination is performed daily for 7 days to rule out mesenteric venous thrombosis and to confirm flow in IHPV.

2. Conclusion

Liver transplant is a major surgery and can be avoided in a small subset of patients with type 1 CPSS by this strategy as demonstrated earlier (4, 5, 6, 7). We extrapolated the techniques of pulmonary artery banding and regulating the pulmonary blood flow after a systemic-pulmonary shunt from the armamentarium of congenital heart surgery and utilised it successfully to band the CPSS (8, 9).

Acknowledgement: None

Conflict of interest: None

Ethics committee approval: Not applicable

Informed consent: Informed consent was obtained from the parents for the publication.

Availability of data and material: All the data related to the publication are available in the hospital's record department.

Code availability: Not applicable

Human and animal rights: Not applicable

Authors' contributions: All authors have equally participated in the preparation of manuscript.

References

- [1] Witters P, Maleux G, George C, Delcroix M, Hoffman I, Gewillig M, et al. Congenital veno-venous malformations of the liver: Widely variable clinical presentations. *J Gastroenterol Hepatol*. 2008 Aug;23(8 Pt 2):e390-4. doi: 10.1111/j.1440-1746.2007.05156.x. Epub 2007 Sep 14. PMID: 17868331.
- [2] Timpanaro T, Passanisi S, Sauna A, Trombatore C, Pennisi M, Petrillo G, et al. Congenital Portosystemic Shunt: Our Experience. *Case Rep Pediatr*. 2015;2015:691618. doi: 10.1155/2015/691618. Epub 2015 Feb 2. PMID: 25709849; PMCID: PMC4332460.
- [3] Uchida H, Sakamoto S, Kasahara M, Kudo H, Okajima H, Nio M, et al. Longterm Outcome of Liver Transplantation for Congenital Extrahepatic Portosystemic Shunt. *Liver Transpl*. 2021 Feb;27(2):236-247. doi: 10.1002/lt.25805. Epub 2020 Aug 6. PMID: 32463947.Feb
- [4] Facas J, Cruz M, Costa JF, Agostinho A, Donato P. Multistage closure of a congenital extrahepatic portosystemic shunt. *CVIR Endovasc* 4, 79 (2021). <https://doi.org/10.1186/s42155-021-00267-x>
- [5] Matsuura T, et al, Surgical strategy according to the anatomical types of congenital portosystemic shunts in children, *J Pediatr Surg* (2016), <http://dx.doi.org/10.1016/j.jpedsurg.2016.09.046>
- [6] Blanc T, Guerin F, Franchi-Abella S, Jacquemin E, Pariente D, Soubrane O, et al. Congenital Portosystemic Shunts in Children: A New Anatomical Classification Correlated With Surgical Strategy. *Annals of Surgery*, Volume 260, Number 1, July 2014
- [7] Sasikumar D, Valakkada J, Kramadhari H, Ayyappan A, Krishnamoorthy K. Novel transcatheter treatment for staged closure of Abernethy malformation with portal hypoplasia. *Ann Pediatr Card* 2021;14(3): 419-421
- [8] Nezafati MH, Nezafati P, Kahrom M. Pulmonary artery banding using polytetrafluoroethylene; Choice of material. *ARYA Atheroscler* 2017; 13(5): 202-4.
- [9] Osami Honjo and Christoph Haller. Banding a Systemic-to-Pulmonary Shunt to Balance Pulmonary Blood Flow. <https://doi.org/10.1053/j.optechstcvs.2018.03.002>

Figure legends

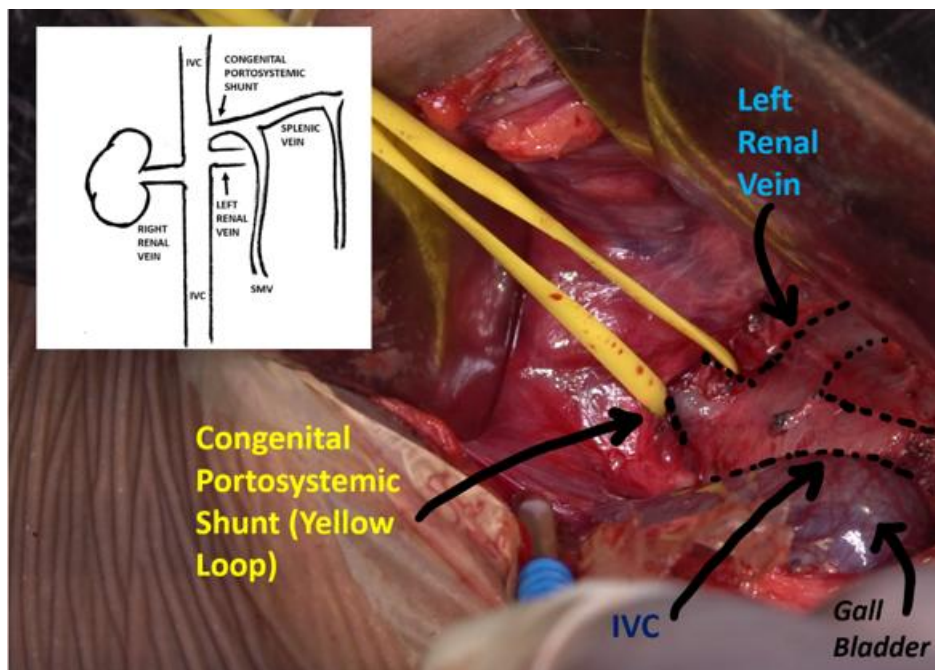


Figure 1: Intraoperative image pre-band. IVC: inferior vena cava, SMV: superior mesenteric vein

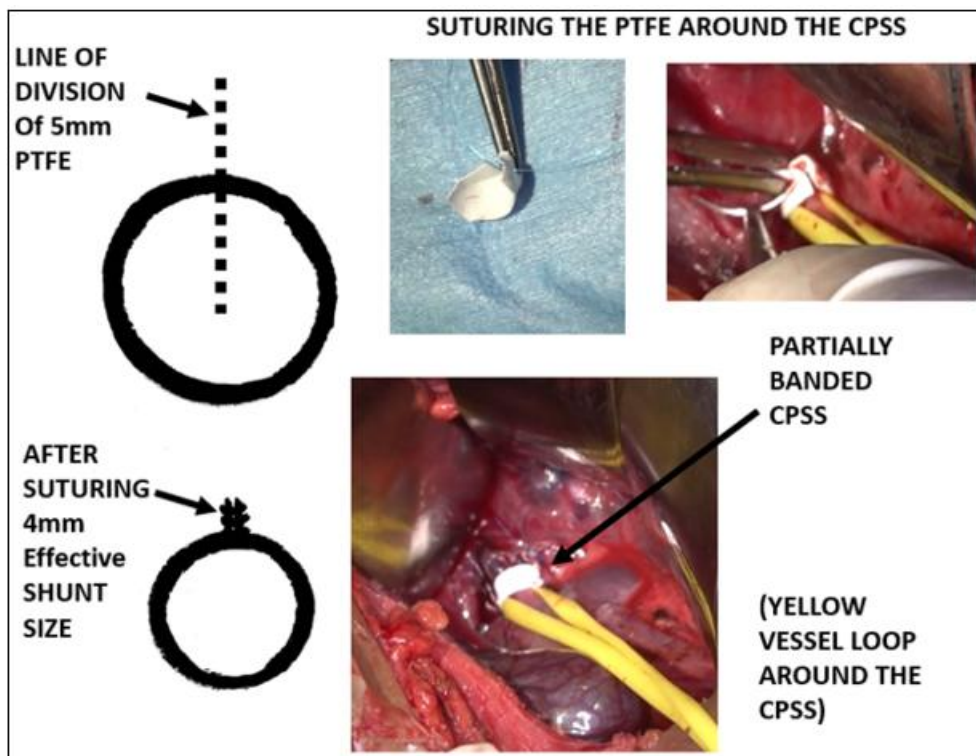


Figure 2: Intraoperative image post band and band technique