

# Lymphangiomas Circumscriptum Over External Urethral Meatus: A Case Report

Dr. Jaya Pritica Toppo<sup>1</sup>, Dr. Twisha Sharma<sup>2</sup>

<sup>1</sup>MBBS MD (DVL), Senior Resident, Department of Dermatology, Venereology and Leprosy, Sheikh Bhikhari Medical College, Hazaribagh, Jharkhand, India 825301

Corresponding Author Email: [jpritica18\[at\]gmail.com](mailto:jpritica18[at]gmail.com)

<sup>2</sup>MBBS MD (DVL), Senior Resident, Department of Dermatology, Venereology and Leprosy, Mahatma Gandhi Memorial Medical College, Jamshedpur, Jharkhand, India 831020

Email: [twishasharma10\[at\]gmail.com](mailto:twishasharma10[at]gmail.com)

**Abstract:** *Lymphangioma circumscriptum (LC) is a rare benign lymphatic malformation presenting as clusters of translucent vesicles. Genital involvement, particularly over the external urethral meatus, is exceedingly uncommon and may mimic infectious conditions. We report a 15-year-old male with a congenital, progressively enlarging lesion over the urethral meatus associated with intermittent bleeding. Examination revealed grouped clear fluid-filled vesicles over an erythematous plaque. The patient had prior interventions with recurrence and complications. Due to the sensitive site and parental preference, conservative management with follow-up was advised. This case highlights the diagnostic challenge of urethral LC and emphasizes the importance of considering it in genital lesions to avoid misdiagnosis and inappropriate treatment.*

**Keywords:** Lymphangioma circumscriptum, urethral meatus, genital lesions, lymphatic malformation

## 1. Introduction

Lymphangioma circumscriptum is a rare benign cutaneous lesion which occurs due to the hamartomatous tortuous lymphatic channels. It can be congenital, occurring due to the abnormal development of lymphatics over epidermis or subcutaneous tissue or can occur after occlusion of lymphatic flow due to any cause, like edema, post-surgery, radiation or due to pressure effects of a tumor growth. It sometimes can cause pain, discomfort, irritation and discharge of serous fluid from the lesions.<sup>1</sup> Lymphangioma are divided into two categories: superficial and deeper type. Cutaneous lymphangioma circumscriptum falls under the superficial type and the deeper type consists of cystic hygroma and cavernous lymphangioma.<sup>2</sup> Lesions of lymphangioma circumscriptum present as plaque over which are studded, multiple clear fluid filled vesicles which have frogspawn appearance on dermoscopy.<sup>3</sup> It can cause a diagnostic dilemma when occurs in genital areas and can be confused for lesions of herpes zoster, molluscum contagiosum, anogenital warts and other infectious conditions.<sup>4</sup> The occurrence over urethral meatus is rare and not many cases have been reported in literature.

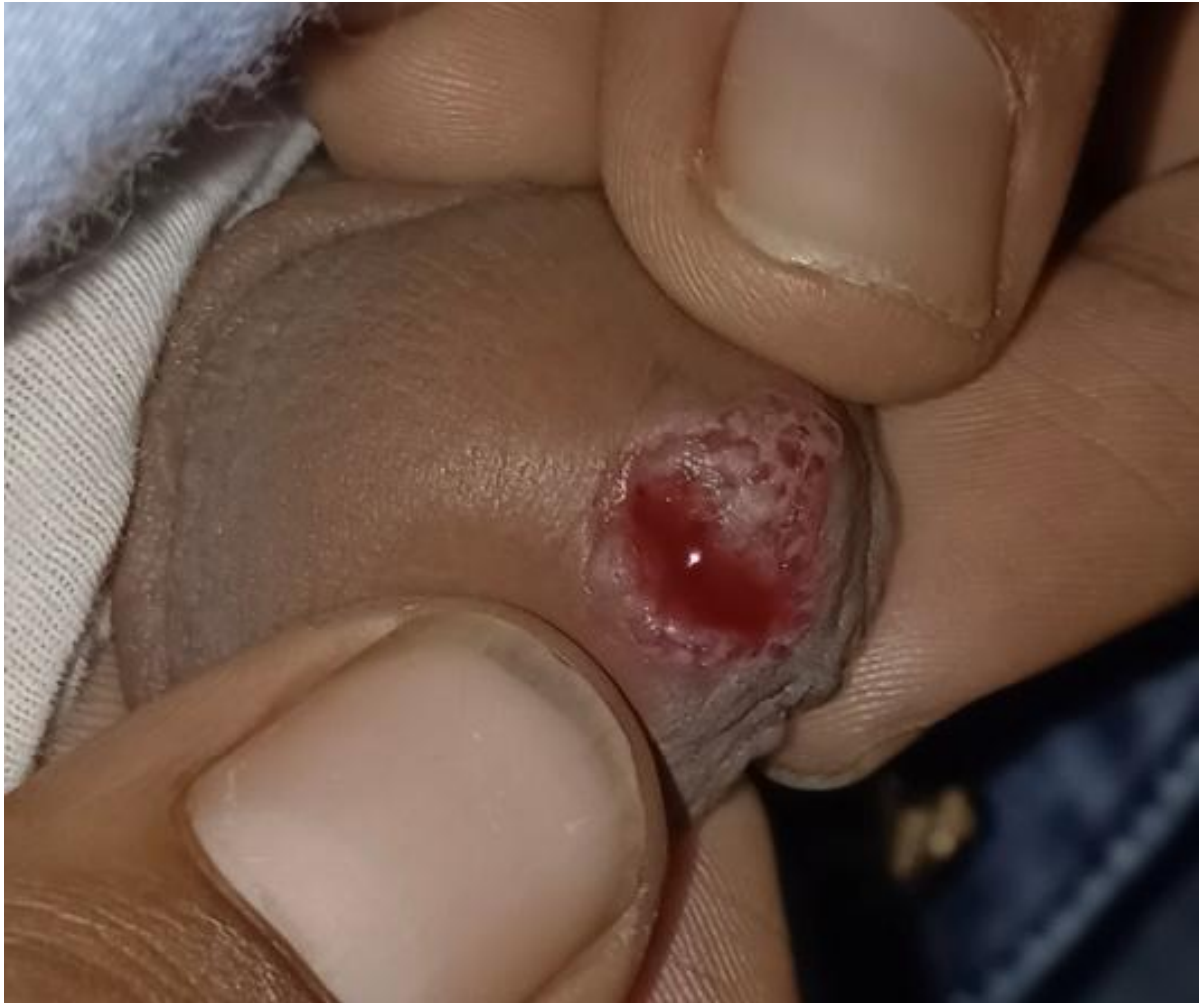## 2. Case Presentation

A 15-year-old male patient presented in skin OPD with a slowly progressive lesion present over the opening of the urethral meatus. The lesion was present since birth and had been first noticed by the boy's parents 15-20days after his birth. The lesion had been slowly growing in size ever since. It initially was present over the lower right side of the opening

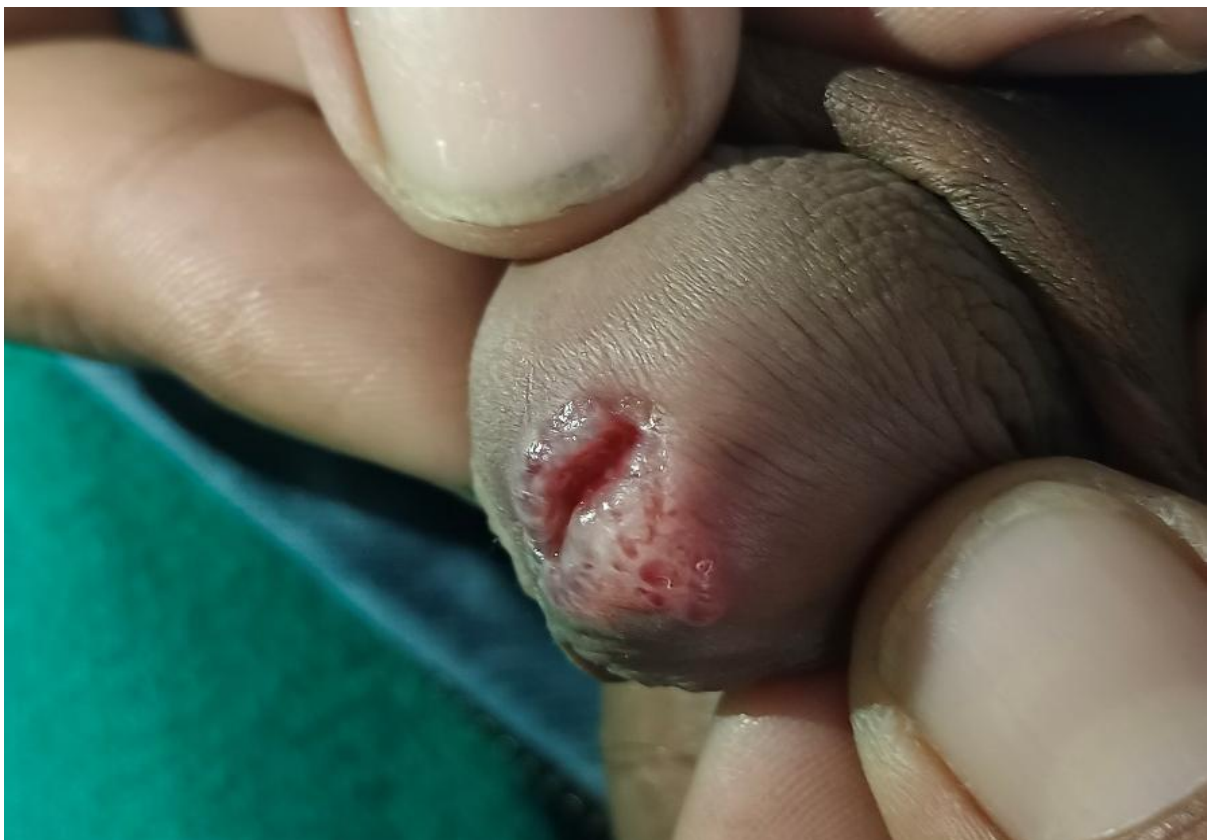of meatus and has grown to current size almost covering the opening circumferentially. It is associated with bleeding per urethra with complains of pain occasionally but no other discomfort. The boy had been circumcised at the age of 5 years. On closer inspection there was a plaque on which were present a cluster of translucent clear vesicles, of approximately 1mm-3mm in diameter over an erythematous base. The lesions were filled with clear fluid. There was blood-tinged watery discharge present over the external urethral meatus. It was not tender on touch. Patient had a complaint of bleeding from urethra since the age of 4 years, which did not improve after circumcision. He had an ulceration over the lesion at the age of 6 years for which his parents consulted a local practitioner and was treated symptomatically with Neosporin ointment and were advice for cryoscopy and fulguration for which patient party denied. Patient underwent a chemical cautery with copper sulphate solution at age 7 years after which he developed strictures for which surgical treatment were done. The lesion recurred and since then has been insidiously growing along with complains of recurrent ulcerations and bleeding from urethra.

A biopsy was done and the sample sent for histopathological examination which showed acanthosis and hyperkeratosis in the epidermal region along with dilated lymphatics in the papillary dermis, confirming the diagnosis for lymphangioma circumscriptum.

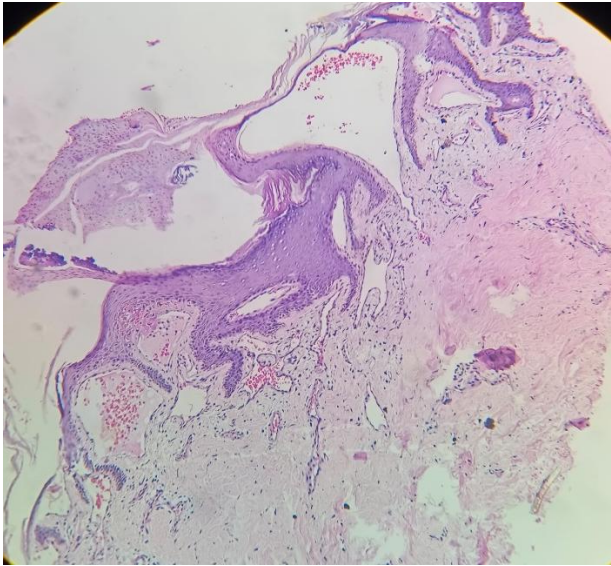
The parents were counseled for RFA for which they denied. The patient and parents were counseled for future complications of secondary infection and ulcerations and symptomatic treatment was given. Patient was kept in monthly follow up.



**Image 1:** Lesion of lymphangioma circumscriptum(LC) seen over the external urethral meatus



**Image 2:** Another image showing lesion of LC at the external urethral meatus in the patient.



**Image 2:** Biopsy of the lesion showing dilated lymphatics confirming diagnosis of LC

### 3. Discussion

Lymphangioma circumscriptum although congenital in most cases, can also be acquired.<sup>1</sup> Superficial lymphangioma comprising the cutaneous lymphangioma circumscriptum is the most common type of cutaneous lymphangioma.<sup>2</sup>

The pathogenesis of congenital lymphangioma circumscriptum was described by Whimster in 1976. The primitive lymph sac during embryonic development gives rise to lymphatic cysterns which remain deep in subcutaneous tissue due to failure of connection to the lymphatic channels. The vesicles seen over the skin are a result of the distension of the occluded channels when the muscle lining present in the lymphatic cistern walls contract causing a rise in pressure within these channels.<sup>5</sup> The malformations in the lymphatics as well as vascular malformations have been attributed to mutations in somatic phosphatidylinositol-4,5-bisphosphate 3-kinase, catalytic subunit alpha (PIK3CA).<sup>6</sup> LC in half of the cases are present at the time of birth and in 90% cases become apparent by 2 years of age.<sup>7</sup>

The lesions of LC most commonly occur over the arms, legs and trunk but can involve any other cutaneous area of the body.<sup>8</sup> LC appear as small vesicles of size 1-3mm in diameter which are filled with clear fluid and are clustered over a plaque with erythematous base.<sup>3</sup> The lesions can ulcerate due to secondary infection and can become hemorrhagic as seen in this case.<sup>8</sup>

There are no pharmacological treatments available and surgical removal is the definitive treatment option available, however other methods like imiquimod, bleomycin, ablative CO2 lasers, radiofrequency ablation, cryotherapy, sclerotherapy have been tried.<sup>9</sup> To this day only a single case of external urethral meatus LC has been described in study done by Jayanti S. et al in a report published in 2020, in which lesion was present over external urethral meatus in 10-year-old male child.<sup>10</sup> LC present over genital sites particularly in pediatric patients poses a different challenge for assessment and treatment as it may torment the parents and the patient owing to the cosmetic disfigurement

that may be caused due to the lesion per se or as a result of surgical treatments exercised.

### 4. Conclusion

Urethral LC is rare and tends to pose challenge for clinicians while making a diagnosis as it mimics other genital lesions and hence warrants a need for proper consideration to avoid missing the diagnosis and to prevent inappropriate treatment.

#### Consent

Patient consent was obtained for publication of this case report and accompanying images. The patients understand that their names and initials will not be published and due efforts will be made to conceal their identity, but anonymity cannot be guaranteed.

#### Financial support and sponsorship-

Nil

#### Conflicts of interest-

There are no conflicts of interest.

### References

- [1] Haroon, S., & Hasan, S. H. (2012). Lymphangioma circumscriptum in the scrotum: A case report. *Journal of Medical Case Reports*, 6(1), 1–5.
- [2] Patel, G. A., & Schwartz, R. A. (2009). Cutaneous lymphangioma circumscriptum: Frog spawn on the skin. *International Journal of Dermatology*, 48, 1290.
- [3] James, W. D., Berger, T. G., & Elston, D. M. (Eds.). (2011). *Andrews' diseases of the skin: Clinical dermatology*. Saunders.
- [4] Riley, D. S. (2017). CARE guidelines for case reports: Explanation and elaboration document. *Journal of Clinical Epidemiology*, 89, 218–235.
- [5] Whimster, I. W. (1976). The pathology of lymphangioma circumscriptum. *British Journal of Dermatology*, 94, 473–486.
- [6] Luks, V. L., Kamitaki, N., Vivero, M. P., Uller, W., Rab, R., Bovée, J. V. M. G., et al. (2015). Lymphatic and other vascular malformative/overgrowth disorders are caused by somatic mutations in PIK3CA. *Journal of Pediatrics*, 166, 1048–1054.
- [7] Fernandez, G., & Schwartz, R. A. (2007). Lymphangioma. *eMedicine Dermatology*. Retrieved May 26, 2009, from <http://www.emedicine.com/DERM/topic866.htm>
- [8] Mortimer, P. S. (2016). Disorders of lymphatic vessels. In C. Griffiths, J. Barker, T. Bleiker, R. Chalmers, & D. Creamer (Eds.), *Rook's textbook of dermatology* (9th ed., pp. 105.34–105.37). John Wiley & Sons.
- [9] Shrestha, S., Shrestha, R., & Manandhar, M. (2020). Lipectomy for symptomatic relief of lymphangioma circumscriptum. *Journal of Clinical and Aesthetic Dermatology*, 13(8), 45.
- [10] Singh, J., Dayal, S., Mothra, J., & Sahu, P. (2020). Primary lymphangioma circumscriptum around external urethral meatus in a male child: A rare presentation. *Indian Journal of Paediatric Dermatology*, 21(3), 206–208.