

# A Dual-Action Appliance for Interceptive Management of Tongue Thrusting Habit and Space Maintenance - A Case Report

Savitha Sathyaprasad<sup>1</sup>, Rashmi S S<sup>2</sup>, Tanmayee Sripada<sup>3</sup>

<sup>1</sup>MDS, PhD FAIMER, Head of the Dept., Dept of Pediatric and Preventive Dentistry, KVG Dental College and Hospital, Sullia, Karnataka;

<sup>2</sup>Post Graduate Student, Dept of Pediatric and Preventive dentistry, KVG Dental College and hospital, Sullia, Karnataka

<sup>3</sup>Post Graduate Student, Dept of Pediatric and Preventive dentistry, KVG Dental College and hospital, Sullia, Karnataka

**Abstract:** *This case report describes the comprehensive management of a 6-year-old female presenting with pain in the lower left posterior region. Clinical and radiographic examination revealed multiple carious lesions, root stumps in tooth 54, ectopic eruption of tooth 11, mesiolingual rotation of tooth 31, and a tongue thrusting habit contributing to developing malocclusion. Treatment followed a systematic multi-phase approach including pulpectomy of teeth 74, 75, and 62 with stainless steel crown restorations, extractions, and composite restorations. Premature loss of tooth 54 necessitated space maintenance, addressed through a dual-function appliance combining a modified tongue crib with Mayne's space maintainer for simultaneous habit correction and space preservation. This case underscores the importance of early diagnosis and interceptive management of oral habits and premature tooth loss to promote favourable occlusal development.*

**Keywords:** Early childhood caries, pulpectomy, stainless steel crown, space maintainer, tongue thrusting habit, ectopic eruption, mayne's space maintainer, tongue crib, interceptive orthodontics, oral habits.

## 1. Introduction

Early childhood caries (ECC) is one of the most prevalent chronic diseases in children worldwide, affecting 60–90% of school-aged children according to the World Health Organization<sup>[1,3]</sup> In India, prevalence is reported between 40% and 70%, particularly in populations with limited access to preventive dental care.<sup>[1]</sup> Tongue thrusting habit has a reported prevalence of 5–25% in children and is strongly associated with developing malocclusions<sup>[6,7]</sup> Premature loss of primary teeth due to ECC frequently results in space loss, further contributing to occlusal discrepancies and compromised arch development.<sup>[9,20]</sup>

Tongue thrusting is characterized by the forward placement of the tongue against or between the anterior teeth during swallowing, speech, or at rest.<sup>[9]</sup> Persistence of this habit beyond the normal developmental stage adversely affects the developing dentofacial structures, leading to anterior open bite, proclination of incisors, spacing, and ectopic eruption of teeth.<sup>[7,9]</sup> Early interception is therefore essential to prevent the progression of functional and orthodontic abnormalities and to promote normal orofacial growth.<sup>[8,10]</sup>

Premature loss of primary molars can result in drifting of adjacent teeth, reduction in arch length, and disturbance in the eruption pattern of permanent successors.<sup>[19,20]</sup> Management becomes particularly challenging when oral habits coexist with premature tooth loss, as both conditions synergistically contribute to developing malocclusion.<sup>[11,12]</sup> Combining a habit-breaking appliance with a space maintainer offers an efficient interceptive approach by simultaneously addressing abnormal muscular activity and preserving arch space.<sup>[16,17,18]</sup> The present case report highlights the use of a modified tongue crib integrated with Mayne's space maintainer for the

concurrent management of these two conditions in a young pediatric patient.

## 2. Case Report

A 6-year-old female child reported to the Department of Pedodontics and Preventive Dentistry, K.V.G. Dental College and Hospital, Sullia, with a chief complaint of pain in the lower left posterior region for the past 3 weeks. The pain was spontaneous in onset, dull and gnawing in nature, aggravated by hot and cold stimuli, and associated with food lodgement. Medical history was non-contributory, and the child exhibited normal growth and development. This was the patient's first dental visit. Oral hygiene practices were inadequate, with brushing performed once daily, and the diet was deficient in fruits and vegetables. Behavioural assessment categorized the child as tense cooperative and manageable with behaviour guidance techniques.

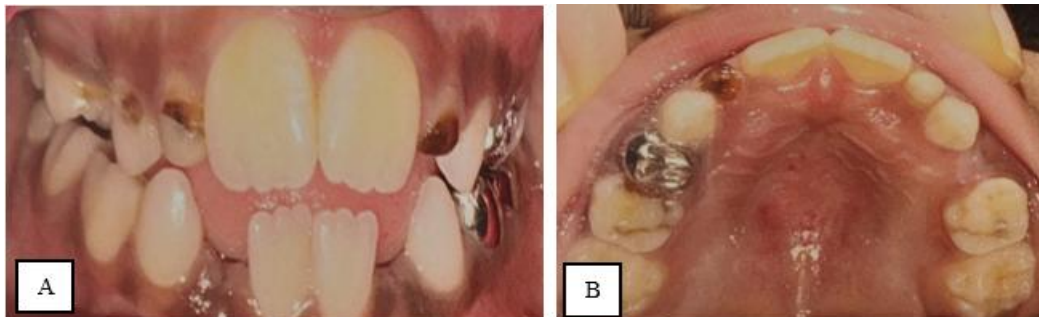
Intraoral examination revealed the patient to be in the mixed dentition stage with multiple carious lesions. Tooth 54 was present as root stumps requiring extraction. A tongue thrusting habit was clinically evident, characterized by forward tongue placement during swallowing, and was associated with ectopic eruption of tooth 11 and mesiolingual rotation of tooth 31. Radiographic examination of tooth 54 confirmed extensive coronal destruction with a widened periodontal ligament space, suggestive of chronic pulpal pathology.

Based on clinical and radiographic findings, a diagnosis of root stumps in relation to tooth 54 secondary to ECC, with a coexisting tongue thrusting habit, was established. A comprehensive, multi-phase treatment plan was formulated including pulpectomy for teeth 74, 75, and 62 with stainless

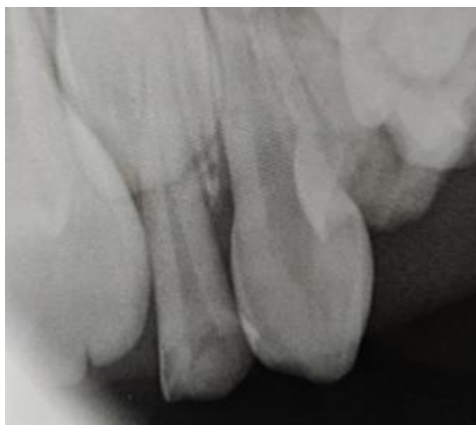steel crown restorations, composite restorations for remaining carious lesions, extraction of root stumps in relation to tooth 54, and interceptive orthodontic management.

Following extraction of tooth 54, a dual-function appliance combining a modified tongue crib with Mayne's space maintainer was fabricated. The appliance was designed to simultaneously intercept the tongue thrusting habit and

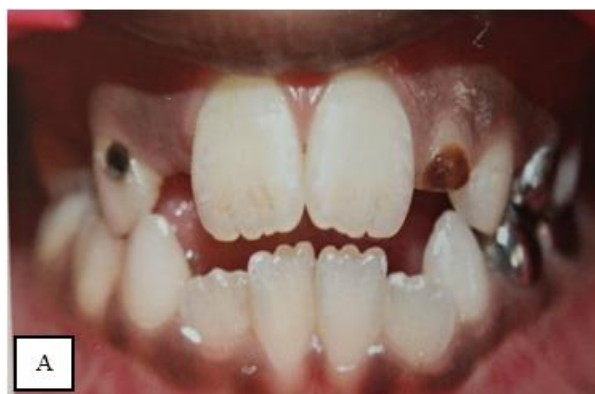maintain the space created following extraction, thereby minimizing the risk of developing malocclusion and promoting favourable occlusal development. The patient, being tense cooperative, was managed using gradual acclimatization and positive reinforcement techniques, with parental counselling provided regarding dietary modification and oral hygiene maintenance throughout the treatment period.

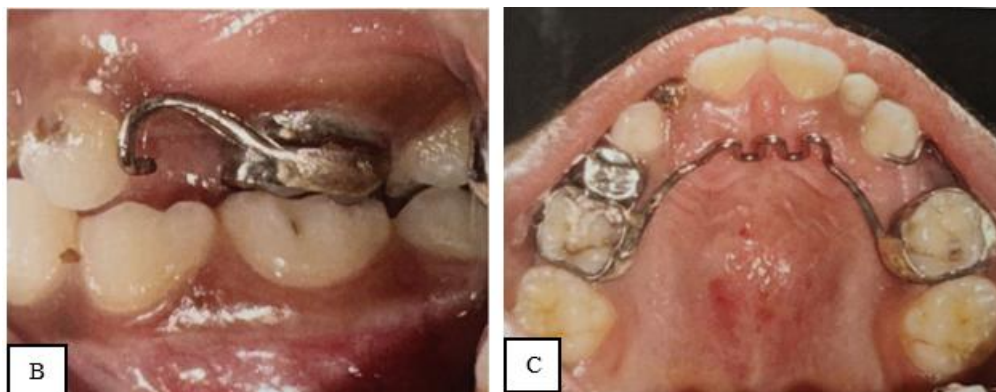


**Figure 1:** Pre-treatment intraoral photographs. (A) Frontal view showing multiple carious lesions, ectopic eruption of tooth 11, and mesiolingual rotation of tooth 31. (B) Occlusal view showing gross carious destruction, root stumps in relation to tooth 54, and mixed dentition status.



**Figure 2:** Intraoral periapical radiograph of tooth 54 revealing extensive coronal destruction, widened periodontal ligament space, and furcation involvement, confirming chronic pulpal pathology and necessitating extraction





**Figure 3:** Post-treatment intraoral photographs. (A) Frontal view showing stainless steel crown restorations. (B) Lateral view showing Mayne's space maintainer in situ following extraction of tooth 54. (C) Occlusal view demonstrating the dual-function appliance combining the modified tongue crib with Mayne's space maintainer.

### 3. Discussion

Ecc is strongly associated with poor oral hygiene, prolonged bottle feeding, and a diet rich in fermentable carbohydrates.<sup>[1,2]</sup> In the present case, extensive carious destruction resulted in root stumps in tooth 54, necessitating extraction. Premature loss of primary molars is clinically significant, as it may lead to drifting of adjacent teeth, arch length reduction, and subsequent malocclusion if timely space maintenance is not performed.<sup>[19,20]</sup>

Space maintenance following extraction of tooth 54 was therefore considered essential to preserve arch integrity and guide proper eruption of the permanent successor.<sup>[16,17,18]</sup> Mayne's space maintainer was selected for its proven effectiveness in preserving arch space while maintaining patient comfort and appliance stability.<sup>[21,22]</sup> Concurrently, the patient's tongue thrusting habit was associated with ectopic eruption of tooth 11 and mesiolingual rotation of tooth 31. Persistent tongue thrusting alters the equilibrium of orofacial musculature and can adversely affect the developing dentition by producing abnormal and continuous forces on the anterior teeth.<sup>[6,7,9]</sup>

To address both concerns simultaneously, a modified tongue crib combined with mayne's space maintainer was fabricated as a single integrated appliance.<sup>[11,21]</sup> The tongue crib component restricted forward tongue posture during swallowing, while the space maintainer component preserved arch space following extraction.<sup>[13,14]</sup> Combining both functions into one appliance offered a practical and efficient interceptive approach, reducing the need for multiple appliances and significantly improving patient compliance.<sup>[11,12]</sup> Behaviour management through gradual acclimatization and positive reinforcement facilitated successful treatment execution. Parental counselling regarding dietary modification, oral hygiene maintenance, and adherence to regular follow-up visits was strongly emphasized to prevent recurrence and ensure long-term treatment success.<sup>[4,5]</sup>

### 4. Conclusion

This case highlights the importance of early diagnosis and comprehensive management of pediatric patients presenting with ecc, oral habits, and developing malocclusion.<sup>[1,5]</sup> A

phased, multidisciplinary treatment approach involving endodontic therapy, definitive restorations, space maintenance, and interceptive orthodontic intervention was essential in achieving optimal clinical outcomes.<sup>[24,25]</sup>

The modified tongue crib combined with mayne's space maintainer proved to be an effective dual-function strategy for simultaneously managing tongue thrusting habit and preserving arch length.<sup>[11,21]</sup> This integrated approach not only improved treatment efficiency and patient compliance but also minimized the need for multiple appliances.<sup>[12,22]</sup> Timely intervention, along with appropriate behaviour management and parental counselling, plays a critical role in preventing long-term functional and aesthetic complications.<sup>[4,5]</sup> Regular follow-up and consistent reinforcement of preventive measures are essential to ensure sustained oral health and proper dentition development in pediatric patients.<sup>[1,3]</sup>

### References

- [1] Tinanoff N, Baez RJ, Diaz Guillory C, et al. Early childhood caries epidemiology, aetiology, risk assessment, societal burden, management, education, and policy: Global perspective. *Int J Paediatr Dent.* 2019;29(3):238–248.
- [2] Drury TF, Horowitz AM, Ismail AI, Maertens MP, Rozier RG, Selwitz RH. Diagnosing and reporting early childhood caries for research purposes. *J Public Health Dent.* 1999;59(3):192–197.
- [3] Uribe S, Innes N, Maldupa I. The global prevalence of early childhood caries: a systematic review with meta-analysis using the WHO diagnostic criteria. *Int J Paediatr Dent.* 2021;31(6):817–830.
- [4] Datta P, Datta PP. Prevalence of early childhood caries in India: a systematic review. *Indian J Pediatr.* 2018;85(11):951–957.
- [5] American Academy of Pediatric Dentistry. Policy on early childhood caries (ECC): classifications, consequences, and preventive strategies. *Pediatr Dent.* 2022;44(6):15–19.
- [6] Subtelny JD. Oral habits — studies in form, function, and therapy. *Angle Orthod.* 1973;43(4):347–383.
- [7] Tulunoglu O, Bodur H, Uctasli M. Effect of tongue thrust swallowing on dentofacial structures. *J Clin Pediatr Dent.* 2005;30(1):23–26.

- [8] Urzal V, Braga AC, Ferreira AP. Oral habits as risk factors for anterior open bite in the deciduous and mixed dentition — cross-sectional study. *Eur J Paediatr Dent*. 2013;14(4):299–302.
- [9] Al Habib SA, et al. Influence of oral habits on pediatric malocclusion: etiology and preventive approaches. *Cureus*. 2024;16(11): e73540.
- [10] Cozza P, Baccetti T, Franchi L, Mucedero M, Polimeni A. Sucking habits and facial hyperdivergency as risk factors for anterior open bite in the mixed dentition. *Am J Orthod Dentofacial Orthop*. 2005;128(4):517–519.
- [11] Manzoor Z, Wadhawan A, Nagar S, Kumar A, Singh M. A modified tongue crib appliance for correction of tongue thrusting. *Cureus*. 2023;15(6): e40518.
- [12] Chandel R, Pande MS, Yeluri R, Pankey N, Khubchandani M. Anterior open bite treated with palatal crib and myofunctional therapy: a case report. *Cureus*. 2024;16(6): e63549.
- [13] Huang Y, et al. Treatment of severe anterior open bite by using tongue crib and teeth extraction: a case report. *BMC Oral Health*. 2025; 25: 731.
- [14] Osiewacz S, Jurecka M, Pawłowska E. Tongue function correction appliances: current state of knowledge and therapeutic possibilities — review of the literature. *Dent Med Probl*. 2015;52(2):227–234.
- [15] Ovsenik M. Incorrect orofacial functions until 5 years of age and their association with posterior crossbite. *Am J Orthod Dentofacial Orthop*. 2009;136(3):375–381.