

# Role of Computed Tomography in Diagnosis of Masses in the Visceral Compartment of Mediastinum

Dr. Manni Sharma<sup>1</sup>, Dr. Anjana Patel<sup>2</sup>, Dr. Vishva Chauhan<sup>3</sup>, Dr. Ravi S. Patel<sup>4</sup>

<sup>1</sup>Resident Doctor, Department of Radiology, PDU Govt. Medical College and Civil Hospital, Rajkot, Gujarat, India  
Email: buddysplint[at]gmail.com

<sup>2</sup>Professor & Head, Department of Radiology, PDU Govt. Medical College and Civil Hospital, Rajkot, Gujarat, India

<sup>3</sup>Assistant Professor, Department of Radiology, PDU Govt. Medical College and Civil Hospital, Rajkot, Gujarat, India

<sup>4</sup>Resident Doctor, Department of Radiology, PDU Govt. Medical College and Civil Hospital, Rajkot, Gujarat, India

**Abstract:** ***Introduction:** Masses of the visceral compartment of the mediastinum encompass a wide spectrum of pathological entities ranging from benign cysts to aggressive malignancies. Accurate localization, characterization, and assessment of the extent of these lesions are essential for appropriate diagnosis and management. Multidetector Computed Tomography (MDCT) has emerged as the imaging modality of choice due to its high spatial resolution, rapid acquisition, and excellent capability for multiplanar reconstruction. **Materials and Methods:** This prospective study was conducted over a period of 18 months from October 2023 to March 2025 at a tertiary care center and included 50 patients with suspected visceral mediastinal masses. All patients underwent CT of the thorax using multidetector CT scanner. Imaging findings were analyzed with respect to lesion location, size, morphology, attenuation characteristics, enhancement pattern, and involvement of adjacent structures. Wherever possible, imaging findings were correlated with histopathological diagnosis or clinical follow-up. **Results:** The study included patients across a wide age range with a slight male predominance. The most common presenting symptoms were cough, dyspnea and chest pain. Lymph nodal masses and malignant lesions constituted a significant proportion of cases, followed by congenital cystic lesions such as bronchogenic and duplication cysts. MDCT accurately localized lesions within the visceral compartment and provided detailed characterization based on attenuation and enhancement patterns. It also effectively demonstrated invasion of adjacent mediastinal structures. **Conclusion:** MDCT plays a pivotal role in the evaluation of visceral mediastinal masses by providing precise anatomical localization, characterization of lesions, and assessment of extent of disease. It serves as an indispensable tool in guiding diagnosis, management, and further therapeutic planning.*

**Keywords:** ITMIG, Visceral mediastinum, Mediastinal masses, Multidetector CT, Lymphadenopathy, Lymphoma, MDCT

## 1. Introduction

The mediastinum contains a wide variety of pathological conditions, including neoplasms, cysts, vascular abnormalities, and lymph node masses, making their diagnosis challenging. With the advent of multidetector computed tomography (MDCT), cross-sectional imaging has become the modality of choice for evaluating mediastinal lesions due to its excellent spatial resolution, multiplanar reconstruction capabilities, and ability to characterize tissue composition and disease extent. The International Thymic Malignancy Interest Group (ITMIG) classification has further improved lesion localization by dividing the mediastinum into prevascular, visceral, and paravertebral compartments based on anatomical boundaries. The visceral compartment contains vital structures such as the heart, great vessels, trachea, oesophagus, and central lymph nodes, and is affected by a broad spectrum of benign and malignant pathologies. CT plays a pivotal role in accurately localizing these lesions, assessing their internal characteristics, and evaluating involvement of adjacent structures, thereby aiding diagnosis, staging, and treatment planning. This study focuses on the role of CT in the evaluation and characterization of masses arising within the visceral compartment of the mediastinum.

## 2. Aim and Objectives

To determine the localization, extent of involvement and characterization of visceral mediastinal masses.

### Deciphering the Mediastinum through the Decades of Studies

#### 01. Primary Mediastinal Tumors, Part II. Tumors of the Middle and Posterior Mediastinum, 1997 Stollo D. C., Rosado-de-Christenson M. L., Jett J. R.

This review highlights that middle and posterior mediastinal masses account for approximately 50% of all mediastinal lesions. The most common lesions are lymphoma, congenital foregut cysts, and neurogenic tumors. Neurogenic tumors constitute about 90% of posterior mediastinal masses, while foregut cysts are the most frequent cystic lesions of the middle mediastinum.

#### 02. CT Evaluation of Mediastinal Masses, 2015 Jitendra Kumar Singh Chaudhary, Rasesh Vyas, Avichala Taxak

In this study of 50 patients, mediastinal masses were most common in individuals over 61 years and were predominantly located in the middle mediastinum, where many lesions were malignant. The findings highlight CT's crucial role in detecting, characterizing, staging, and monitoring mediastinal

diseases, offering far greater diagnostic accuracy than conventional radiography.

**03. Multidetector Computed Tomography Evaluation of Mediastinal Lesions with Histopathological Diagnosis, 2015** Venkateshwaran Arumugam, Hajimohammed Nazir, Konduru Varadarajulu Rajasekar

This study of 50 patients demonstrated excellent agreement between MDCT and histopathology in evaluating mediastinal masses. Malignant lesions, particularly lymphoma, were more common than benign lesions. With 100% sensitivity and 91.7% specificity, MDCT accurately characterized lesions, defined their extent, and reduced the need for invasive diagnostic procedures.

**04. Diagnostic Accuracy of Multidetector Computed Tomography Scan in Mediastinal Masses Assuming Histopathological Findings as Gold Standard, 2018** Somshankar Pandey, Usha Jaipal, Nima Mannan, Rajkumar Yadav

This prospective study of 60 patients found that malignant mediastinal masses, particularly metastatic carcinoma, were more common than benign lesions. The anterior mediastinum was the most frequently involved compartment. MDCT showed high diagnostic accuracy (94% sensitivity, 90% specificity), proving valuable for lesion characterization, staging, and surgical planning, although histopathology remained essential for confirmation.

**05. Role of Multidetector Computed Tomography in the Evaluation of Mediastinal Mass Lesions, 2018** V V Hattiholi, Pallav Gupta, Jyothi Hattiholi

This cross-sectional study of 45 patients demonstrated the value of MDCT, combined with the ITMIG classification system, in accurately localizing and characterizing mediastinal masses. Its high-resolution, multiplanar imaging improved pre-procedural planning and reduced diagnostic uncertainty. However, histopathological examination remained essential for establishing a definitive diagnosis.

**06. Computed Tomographic Evaluation of Mediastinal Mass Lesions, 2019**

S Satbeer Singh, Sudhir Sachar, Julius N. Toppo, Anand Acharya

This study of 50 patients found that most mediastinal lesions were malignant, with the middle mediastinum being the most commonly affected compartment. Lymphadenopathy was the predominant finding. CT accurately localized lesions, assessed their extension to adjacent structures, and characterized tissue components, making it invaluable for diagnosis and clinical management.

**07. Role of CT in Evaluation of Mediastinal Masses, 2019** Maajid Mohi Ud Din Malik

This retrospective study of 40 patients demonstrated that CT is highly accurate in evaluating mediastinal masses, with a sensitivity of 96% and specificity of 93%. By identifying characteristic attenuation patterns and assessing involvement of adjacent structures, CT provided reliable lesion characterization, closely correlating with pathology and aiding diagnosis, treatment planning, and follow-up.

### 3. Materials and Method

This prospective observational study was conducted in the Department of Radiodiagnosis, P.D.U. Medical College and Civil Hospital, Rajkot, over a period of one and a half years from October 2023 to March 2025. The study included a total of 50 patients. All examinations were performed using a Wipro GE 128-slice H-211 CT scanner to evaluate the imaging characteristics of mediastinal lesions.

#### Selection criteria

**Inclusion criteria:** All patients referred to the Department of Radiodiagnosis with clinically suspected and CT scan proven visceral mediastinal masses.

**Exclusion criteria:** Pregnant patients and patients with contraindications to contrast media.

**Informed Consent:** Patients fulfilling the selection criteria were informed about the purpose and nature of the study and in case of pediatric patients, parents/ guardians of the children were informed about the purpose & nature of the study and a written informed consent was obtained.

**Procedure:** Once consent was obtained, the patients were interviewed and descriptive data of the participants like age and sex were obtained along with clinical history. All the cases taken up for the CT were evaluated for the compartment localization, MDCT features of the visceral mediastinal masses along with involvement of adjoining structures.

**Patient preparation:** Prior to CT examination, renal function tests were assessed and patients were instructed to fast for 4–6 hours. In patients with impaired renal function, only non-contrast CT was performed. Scanning was carried out in the supine position using a 128-slice MDCT scanner. Contrast-enhanced CT was performed with intravenous non-ionic contrast unless contraindicated. Images were reconstructed in axial, coronal, and sagittal planes and evaluated for lesion location, size, attenuation characteristics, calcification, enhancement patterns, and involvement of adjacent structures.

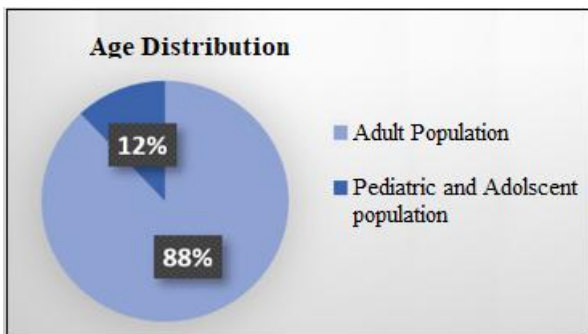
### 4. Results

The study cohort comprised a prospective analysis of 50 patients definitively diagnosed with mass lesions localized within the visceral mediastinal compartment in accordance with the International Thymic Malignancy Interest Group (ITMIG) classification system.

The demographic analysis revealed an expansive age spectrum among the participants, with the cohort maintaining a calculated mean age of 47.9 years. Of the total cases, only 6 were of paediatric and adolescent age group, amounting to 12% of the total cases. Regarding gender distribution, a significant male predominance was documented. (Table no. 1 and 2).

**Table 1: Age Distribution**

Age group (years)	No. of patients (%)
0 to 10	3 (6%)
11 to 20	3 (6%)
21 to 30	4 (8%)
31 to 40	1 (2%)
41 to 50	14 (28%)
51 to 60	14 (28%)
61 to 70	7 (14%)
71 to 80	3 (6%)
81 to 90	1 (2%)



**Table 2: Gender Distribution**

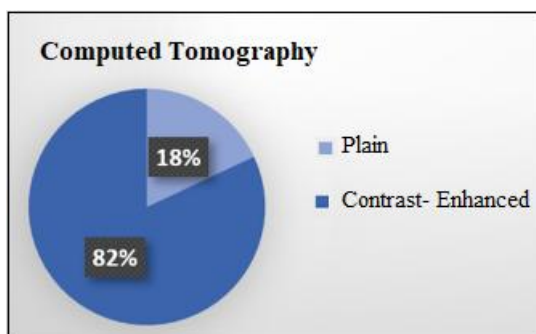
Gender	No. of patients (%)
Males	31 (62%)
Females	19 (38%)

The clinical spectrum of the cohort was predominantly characterized by irritative and obstructive respiratory symptoms, likely a physiological consequence of the masses' proximity to the central airway within the visceral space. (Table no.3)

**Table 3: Symptomatology**

Symptom	No. of patients (%)
Cough	38 (76%)
Dyspnea	37 (74%)
Chest pain	25 (50%)
Dysphagia	22 (44%)
Weight loss	21 (42%)
Fever	19 (38%)

Multidetector Computed Tomography (MDCT) provided the definitive morphological characterization for all lesions. Upon analysis, the majority of visceral masses exhibited a solid attenuation profile (62%, n=31). Complex solid-cystic masses were identified in 26% (n=13) of patients, while purely cystic lesions remained relatively infrequent, accounting for only 6% (n=3) of the total. (Table no. 4)



**Table 4: Distribution of Attenuation of Masses**

Attenuation of mass	No. of masses (%)
Solid	31 (62%)
Solid-cystic	13 (26%)
Cystic	3 (6%)
Fat	1 (2%)
Calcification	8 (16%)
Vessel	3 (6%)

The diagnostic landscape was primarily dominated by lymphadenopathy, which was the definitive finding in 62% (n=31) of the study population. (Table no. 5, 7 and 8.)

**Table 5: Distribution of the Visceral Mediastinal Masses**

The various visceral mediastinal masses diagnosed in the study:	No. of cases in the study	Percentage out of the total cases (%)	Percentage out of the category (%)
Lymphadenopathy	31	62	
• Infective	11	22	35.48
• Metastatic	12	24	38.7
• Inflammatory	8	16	25.8
• Neoplastic lesion	12	24	
• Neoplastic mass (Indeterminate)	4	8	33.33
• Oesophageal carcinoma	4	8	33.33
• Lymphoma	3	6	25
• Bronchogenic carcinoma	1	2	8.33
• Aortic aneurysm	3	6	
• Benign cystic lesion	3	6	
• Pericardial cyst	1	2	33.33
• Oesophageal duplication cyst	1	2	33.33
• Bronchogenic cyst	1	2	33.33
Mediastinal lipoma	1	2	

**Table 6: Distribution of Visceral Mediastinal Masses in Pediatric and Adolescent Population**

Masses seen in the paediatric and adolescent population	Number	Percentage of total paediatric and adolescent population (%)
Lymphadenopathy (infective)	4	66.66
Oesophageal duplication cyst	1	16.66
Neoplastic mass	1	16.66

**Table 7: Distribution of Nature of Masses**

Nature of masses	Number (%)
Benign	26 (52%)
Malignant	24 (48)

**Table 8: Distribution of the Etiology of the Lymphadenopathy**

Lymphadenopathy	No. of patients	Percentage out of the total cases (%)	Percentage out of the category (%)
Infective	11	22	
Tuberculous	8	16	72.72
Aspergillosis	1	2	9.09
Others	2	4	18.18
Inflammatory	8	16	
Silicosis	3	6	37.5

Interstitial lung disease	2	4	25
Others	3	6	37.5
Metastatic	12	24	
Lung carcinoma	6	12	50
Others	6	12	50

The assessment of contrast behaviour on CECT provided critical insights into the internal architecture and vascularity of the masses. A homogeneous enhancement pattern was identified in 36% (n=18) of cases, suggesting a uniform tissue density. Heterogeneous enhancement was documented in 54% (n=27), a feature typically indicative of internal necrosis, haemorrhage, or diverse tissue components within the mass. Finally, non-enhancing lesions, predominantly representing cystic structures or avascular tissue, accounted for 10% (n=5) of the study population.

Topographical analysis indicated that visceral pathologies frequently demonstrated a diffuse rather than focal distribution. (Table no. 9)

**Table 9:** Distribution of the Location of the Masses

Location	No. of cases involving the location (%)
Paratracheal	35 (70%)
Para-oesophageal	13 (26%)
Para-aortic	25 (50%)
Sub-aortic	10 (20%)
Carinal	32 (64%)
Subcarinal	31 (62%)
Hilar	7 (14%)
Para-cardiac	1 (2%)
Multiple locations (as mentioned above) involved	38 (76%)
Extra-compartmental involvement	4 (8%)

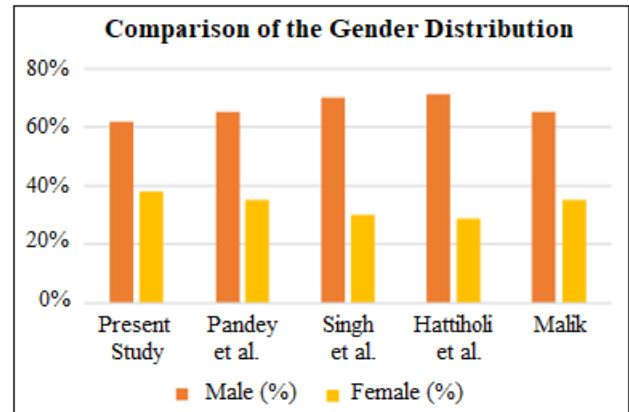
### 5. Discussion

This study provides a targeted analysis of visceral mediastinal mass lesions, utilizing the ITMIG classification system. Unlike broader studies (e.g., Pandey et al., Singh et al., and Malik et al.) that cover the entire mediastinal space, this

research focuses exclusively on the visceral compartment. By isolating this region- which contains the heart, great vessels, and tracheobronchial tree- the aim is to offer a more granular understanding of its specific pathological spectrum.

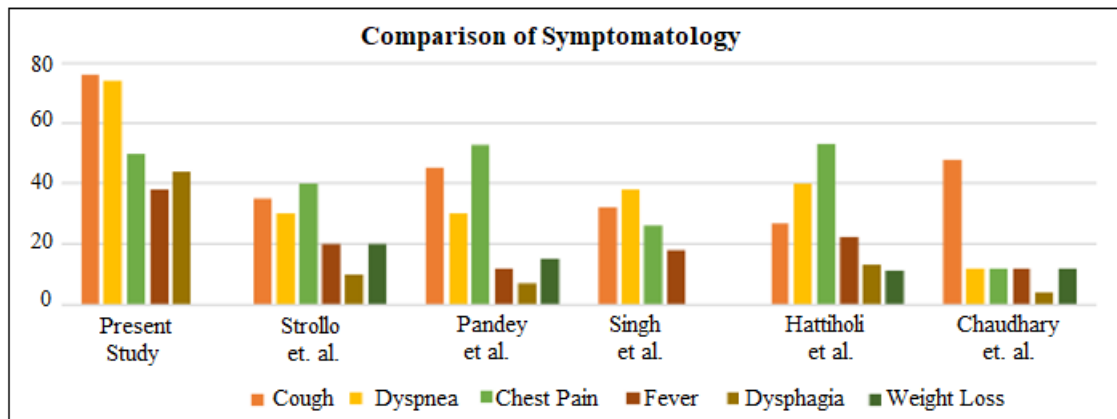
#### Comparison of Demographic Profiles (Age and Gender):

The present study demonstrated a male predominance among patients with visceral mediastinal masses, with most cases occurring in middle-aged and older adults. These findings are broadly consistent with previous studies, which also reported a higher incidence in males and a peak presentation during the fifth and sixth decades of life.



#### Comparison of Clinical Symptomatology:

Patients in the present study showed a markedly higher symptomatic burden than those reported in previous studies. Cough and dyspnea were the most common presenting complaints, with dysphagia and weight loss also occurring more frequently. (Refer to the chart) *The high prevalence of symptoms in this study reflects the anatomy of the visceral (middle) mediastinum, which contains the trachea, bronchi, and oesophagus. Unlike the anterior mediastinum, it poorly accommodates expanding masses. Frequent dysphagia and cough likely result from compression or invasion of these structures by esophageal tumors or metastatic lymphadenopathy.*

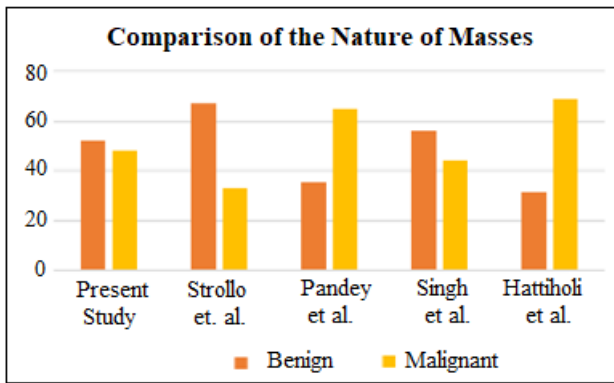


#### Comparison of Biological Nature (Benign vs. Malignant):

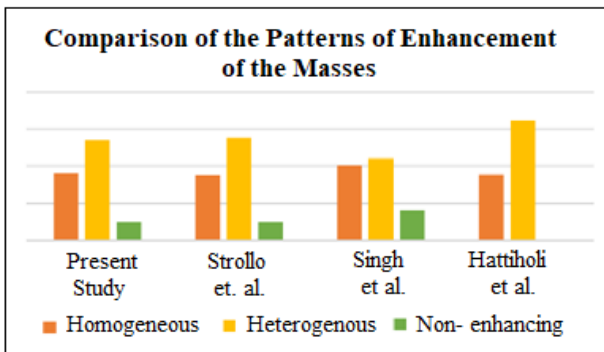
The present study demonstrated a nearly equal distribution of benign and malignant visceral mediastinal masses, with a slight predominance of benign lesions. This finding differs from several previous studies that reported a higher frequency of malignant pathology, highlighting variability in the

reported spectrum of mediastinal masses across different populations. (Refer to the chart) *The predominance of benign lesions in this study is attributable to the high frequency of infective and inflammatory lymphadenopathy (38%), the commonest pathology of the visceral mediastinum. Unlike studies enriched with anterior mediastinal tumors, the benign*

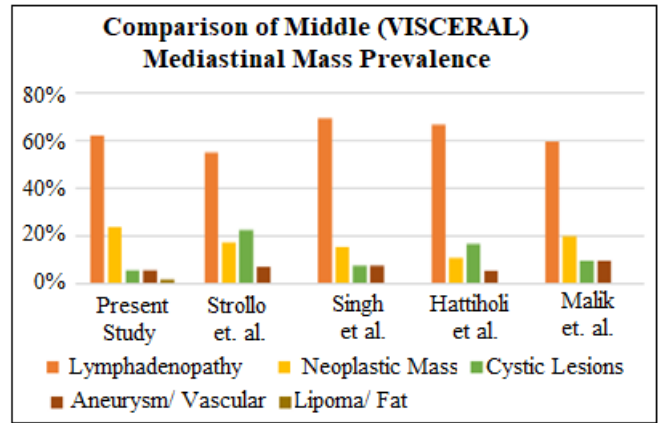
rate reflects infectious granulomatous disease. Nevertheless, malignancies accounted for 48% of cases, indicating an increasing burden compared to earlier reports.



**Comparison of Radiological Characteristics (Enhancement Pattern):** Heterogeneous enhancement was the most common CT enhancement pattern across studies, followed by homogeneous enhancement, while non-enhancing lesions were relatively uncommon. The findings of the present study were consistent with previous reports, although comparison was limited by the lack of enhancement data in several studies. (Refer to the chart). *Variations in enhancement patterns are influenced by lesion pathology, size, necrosis, imaging technology, and contrast protocols. High-resolution CT scanners detect subtle heterogeneity more accurately than older systems. Differences in patient populations, regional disease patterns, and stage at presentation further contribute to the varied radiological profiles reported across studies.*

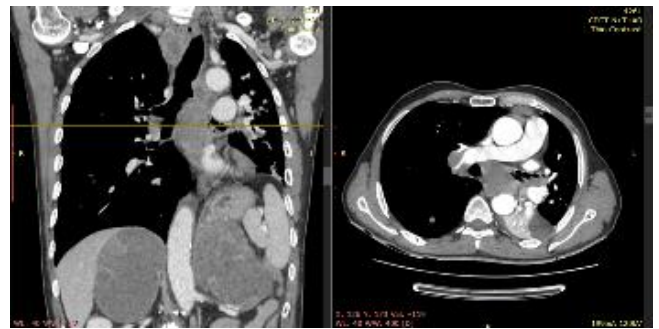


**Comparative Analysis and Compartmental Prevalence:** Lymphadenopathy was the most common finding in the present study, consistent with observations from previous reports. Neoplastic masses constituted a substantial proportion of cases, while cystic, fat-containing, and vascular lesions were comparatively uncommon. Overall, the findings indicate a predominance of nodal and neoplastic pathologies within the visceral mediastinal compartment. (Refer to the chart). *The high prevalence of middle mediastinal lymphadenopathy in this study likely reflects regional factors, particularly the burden of tuberculosis and occupational exposure leading to silicosis in Gujarat. While tuberculosis remains a common cause across India, the prominence of silicosis highlights a localized determinant. Malignant lymphadenopathy constituted 24% of cases, exceeding earlier reports and suggesting a growing impact of environmental and lifestyle-related risk factors.*



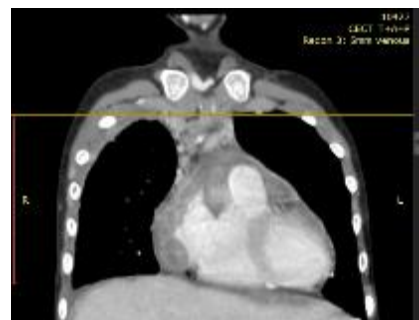6. Case Illustrations

Case Number 1



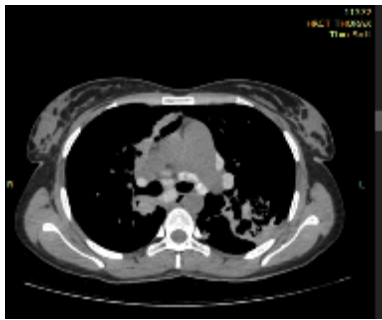
**Lymphadenopathy (metastatic):** CT scan of the thorax (coronal and axial view) showing multiple enlarged homogeneous hypodense lymph nodes at the left paratracheal, carinal and subcarinal regions. There is evidence of left side pleural effusion with underlying lung collapse, ipsilateral mediastinal shift and pulling up of left hemidiaphragm. Bilateral adrenal glands show large hypodense lesions showing relatively homogeneous post-contrast enhancement.

Case Number 2



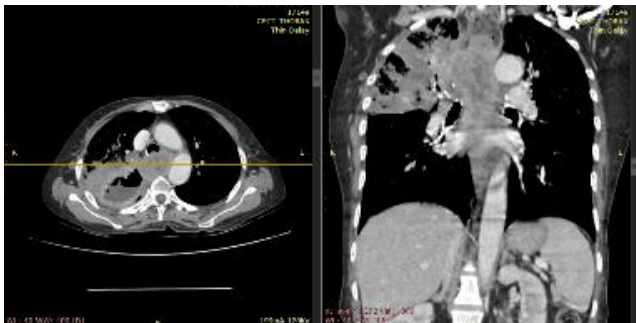
**Lymphadenopathy (infective):** CT scan of the thorax (coronal) showing well-defined hypodense nodular masses at the prevascular and right paratracheal regions of mediastinum, showing heterogeneous post-contrast enhancement and internal small non-enhancing area, suggestive of necrotic areas. There is evidence of well-defined hypodensities in the pericardium along the right atrium, suggestive of pericarditis.

## Case Number 3



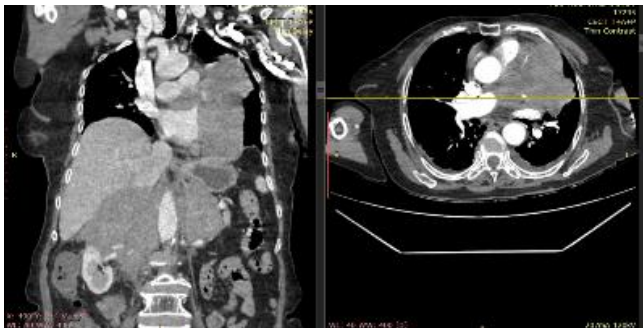**Lymphadenopathy (inflammatory):** CT scan of the thorax (axial view) showing multiple hyperdense carinal, subcarinal and bilateral hilar regions of the mediastinum. Lung field shows confluent area of fibrosis with adjacent traction bronchiectasis, changes of silicosis.

## Case Number 4



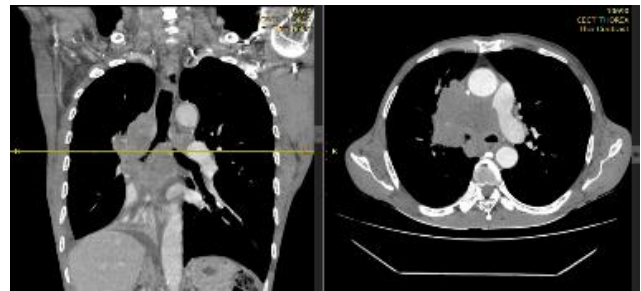
**Oesophageal neoplasm:** CT scan of the thorax (Coronal and axial view) showing a well-defined hypodense lesion with heterogeneous post-contrast enhancement, internal non-enhancing necrotic areas at the retro-tracheal region, arising from the oesophagus. There is a thick-walled cavitary lesion in the right upper lobe. On administration of oral contrast, there is evidence of communication between the oesophageal mass and pulmonary cavitary lesion, likely suggestive of oesophageo-pulmonary fistula formation.

## Case Number 5



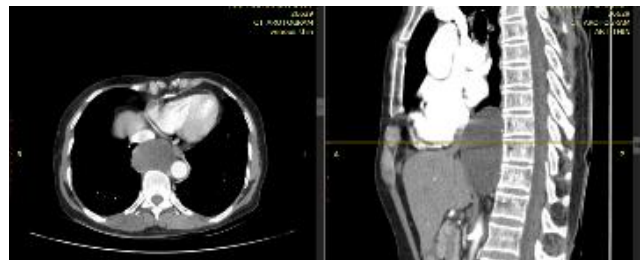
**Lymphoma:** CT scan of the thorax (coronal and axial view) showing a large, well-defined hypodense lesion with homogeneous post-contrast enhancement at the sub-aortic and left para-cardiac region. It is encasing the main pulmonary artery, with no significant luminal narrowing. There are similar appearing hypodense lesions seen at the bilateral adrenal glands.

## Case Number 6



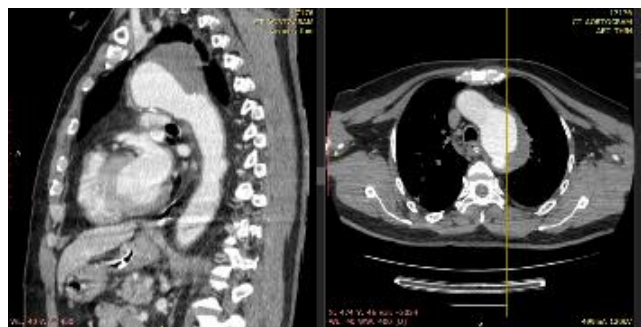**Bronchogenic carcinoma:** CT scan of the thorax (coronal and axial view) showing a well-defined hypodense lesion is seen at the right paratracheal, carinal and subcarinal region, showing homogeneous post-contrast enhancement. It is abutting the ascending aorta and pulmonary artery. There is associated right bronchial wall thickening seen with luminal narrowing and pleural effusion with underlying right lower lobe collapse.

## Case Number 7



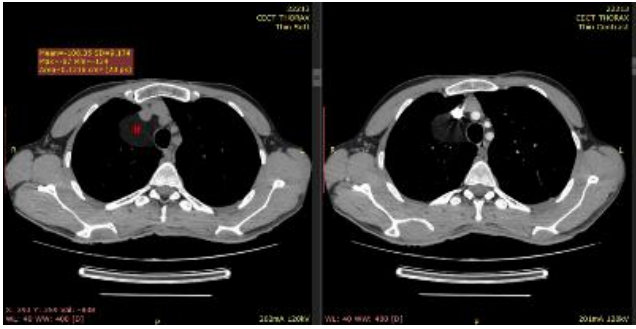
**Bronchogenic cyst:** CT scan of the thorax (Axial and sagittal view) showing a well-defined thin-walled cystic lesion in the right para-oesophageal, lower thoracic region.

## Case Number 8



**Aortic aneurysm:** CT scan of the thorax (Sagittal and axial view) showing a medium-sized outpouching with crescentic filling-defect is seen at the lateral wall of arch of aorta, suggestive of partial thrombosis.

## Case Number 9



**Mediastinal lipoma:** CT scan of the thorax (axial view) showing a well-defined fat-density lesion noted at the right paratracheal region with no evidence of post-contrast enhancement.

## 7. Summary

The present study included 50 patients with visceral mediastinal masses classified according to ITMIG criteria. The mean age of the study population was 47.9 years, with the majority of patients (56%) belonging to the 41–60 years age group. A male predominance was observed, with a male-to-female ratio of 1.63:1. The most common presenting symptoms were cough (76%) and dyspnea (74%).

On CT evaluation, lymphadenopathy was the predominant finding, accounting for 62% of cases. Metastatic lymphadenopathy, mainly secondary to lung carcinoma, was the most common subtype, followed by infective causes, predominantly tuberculosis, and inflammatory causes, with silicosis being the leading etiology. Neoplastic lesions constituted 24% of cases, with oesophageal carcinoma and indeterminate neoplastic masses being the most frequent, followed by lymphoma and bronchogenic carcinoma. Less common lesions included aneurysms (6%), cysts (6%), and mediastinal lipoma (2%).

Most lesions were solid in nature (62%), while 26% were mixed solid-cystic and 6% were purely cystic. Homogeneous enhancement was the most common enhancement pattern (50%), followed by heterogeneous enhancement (26%) and non-enhancing lesions (24%). The paratracheal, carinal, and subcarinal regions were the most frequently involved sites, and diffuse or multi-station involvement was observed in 76% of patients. Benign and malignant lesions showed a nearly equal distribution, accounting for 52% and 48% of cases, respectively. Overall, the study demonstrates that the visceral mediastinal compartment harbors a diverse range of pathologies, including vascular, inflammatory, infective, benign, and malignant lesions, many of which can be accurately characterized using CT imaging.

## 8. Conclusion

This study confirms that multidetector computed tomography (MDCT) is the imaging modality of choice for evaluating visceral mediastinal masses, providing accurate localization, tissue characterization, and assessment of disease extent through the ITMIG compartment-based approach. Visceral mediastinal lesions commonly presented with cough and dyspnea and were predominantly solid, often manifesting as

multi-station lymphadenopathy. Tuberculosis and metastatic lung carcinoma were major contributors to disease burden, while the presence of silicosis reflected regional occupational influences. The superior spatial resolution and multiplanar capabilities of MDCT make it invaluable for diagnosis, treatment planning, and image-guided interventions in mediastinal pathology.

## References

- [1] Webb WR, Higgins CB. Thoracic Imaging: Pulmonary and Cardiovascular Radiology. 3rd ed. Philadelphia, PA: Lippincott Williams & Wilkins; 2016.
- [2] Ko JP, et al. Multidetector CT of the Mediastinum. Radiologic Clinics of North America. 2006;44(3):435-460. PUBMED ID: 16631887
- [3] Gupta S, et al. Mediastinal Biopsy: Principles and Practice. Seminars in Interventional Radiology. 2012;29(4):241-249. PUBMED ID: 23271887
- [4] Whitten CR, et al. A Designer's Guide to Mediastinal Anatomy. RadioGraphics. 2007;27(2):429-442. PUBMED ID: 17356215
- [5] Carter BW, et al. ITMIG Classification of Mediastinal Compartments and Multidetector CT Differential Diagnosis of Mediastinal Masses. Journal of Thoracic Oncology. 2014;9(9):S97-S101. PUBMED ID: 25170275
- [6] Yanagawa M, et al. CT Characterization of Mediastinal Masses: The Role of the ITMIG Classification. Japanese Journal of Radiology. 2015;33(12):731-742. PUBMED ID: 26346452
- [7] Mullan CP, et al. The Mediastinum: A Review of Anatomy and Management. British Journal of Radiology. 2014;87(1034):20130541. PUBMED ID: 24308892
- [8] Grover SB, et al. Value of Multidetector CT with Multiplanar Reformation in Evaluating Mediastinal Masses. Journal of Clinical and Diagnostic Research. 2017;11(7):TC01-TC05. PUBMED ID: 28953049
- [9] Duwe BV, Sterman DH, Musani AI. Tumors of the Mediastinum. Chest. 2005;128(4):2893-2909. PUBMED ID: 16236891
- [10] Fujimoto K, et al. A Proposal for a New Mediastinal Compartment Classification of the Japanese Association for Research on the Thymus (JART). Japanese Journal of Radiology. 2014;32(10):565-573. PUBMED ID: 25141933
- [11] Burkholder DH, et al. International Thymic Malignancy Interest Group (ITMIG) Standardized Definitions and Policies: A Roadmap for the Future. Journal of Thoracic Oncology. 2011;6(10):S1743-S1747. PUBMED ID: 21947055
- [12] Tomiyama N, et al. CT and MRI of Mediastinal Lymphoma and Other Nodal Diseases. Japanese Journal of Radiology. 2009;27(1):1-10. PUBMED ID: 19137452
- [13] Rustgi AK, El-Serag HB. Esophageal Carcinoma. New England Journal of Medicine. 2014;371(26):2499-2509. PUBMED ID: 25539106
- [14] Ba-Ssalamah A, et al. Dedicated Multidetector CT of the Esophagus: Spectrum of Diseases. RadioGraphics. 2009;29(2):405-423. PUBMED ID: 19325055

- [15] Park CM, et al. Tumors of the Trachea: A Radiologic-Pathologic Correlation. *RadioGraphics*. 2004;24(2):537-553. PUBMED ID: 15026598
- [16] Urdaneta AI, et al. Tracheal Tumors: Imaging Spectrum and Pathologic Correlation. *Radiologic Clinics of North America*. 2016;54(6):1053-1065. PUBMED ID: 27712592
- [17] Moon WK, et al. Mediastinal Nodes in Tuberculosis: Evaluation with CT. *RadioGraphics*. 1997;17(3):789-802. PUBMED ID: 9153703
- [18] Iannuzzi MC, et al. Sarcoidosis. *New England Journal of Medicine*. 2007;357(21):2153-2165. PUBMED ID: 18032765
- [19] McAdams HP, et al. Bronchogenic Cyst: Imaging Features with Clinical and Histopathologic Correlation. *Radiology*. 2000;217(2):441-446. PUBMED ID: 11058641
- [20] Grainger RG, Allison DJ. *Grainger & Allison's Diagnostic Radiology: A Textbook of Medical Imaging*. 6th ed. Edinburgh: Churchill Livingstone; 2014.