

# A Comparative Study of Conventional Incision and Drainage Versus Ultrasound Guided Minimally Invasive Technique in Management of Breast Abscess

Dr. Shashwati Dixit<sup>1</sup>, Dr. Amit Agarwal<sup>2</sup>

<sup>1</sup>Postgraduate Resident, Department of General Surgery Saraswathi Institute of Medical Sciences, Hapur, Uttar Pradesh, India

<sup>2</sup>Professor & Head, Department of General Surgery, Saraswathi Institute of Medical Sciences, Hapur, Uttar Pradesh, India

**Abstract:** ***Background:** Breast abscess is a common surgical condition, particularly among lactating women, and often develops as a complication of mastitis. Conventional incision and drainage (I&D) has long been considered the standard treatment; however, it is associated with prolonged healing time, pain, repeated dressings, interruption of breastfeeding, and unsatisfactory cosmetic outcomes. Ultrasound-guided needle aspiration has emerged as a minimally invasive alternative with potentially superior functional and cosmetic results. **Aim:** To compare the efficacy of ultrasound-guided needle aspiration with conventional incision and drainage in the management of breast abscess. **Materials and Methods:** This prospective randomized comparative study was conducted in the Department of General Surgery at Saraswathi Institute of Medical Sciences, Hapur. Fifty patients diagnosed with breast abscess were included and randomly divided into two groups of 25 each. Group A underwent conventional incision and drainage, while Group B underwent ultrasound-guided needle aspiration/re-aspiration under antibiotic coverage. Patients were evaluated for residual abscess, recurrence, healing time, resumption of lactation, and cosmetic outcome. **Results:** Patients managed with ultrasound-guided needle aspiration demonstrated significantly faster healing, lower recurrence rate, fewer residual abscesses, and improved cosmetic outcomes compared to the incision and drainage group. Lactating mothers treated with ultrasound-guided aspiration showed better continuation and resumption of breastfeeding. **Conclusion:** Ultrasound-guided needle aspiration is a safe, effective, and minimally invasive technique for the management of breast abscess. It provides faster recovery, reduced recurrence, improved cosmetic results, and better preservation of breastfeeding compared to conventional incision and drainage.*

**Keywords:** Breast abscess, Ultrasound-guided aspiration, Incision and drainage, Lactational abscess, Minimally invasive surgery

## 1. Introduction

Breast abscess is a localized collection of pus within the breast tissue, most commonly occurring in lactating women as a complication of mastitis. The condition is associated with pain, fever, swelling, erythema, and difficulty in breastfeeding. Staphylococcus aureus remains the most common causative organism.

Traditionally, breast abscess has been managed by incision and drainage under anesthesia. Although effective, the procedure is associated with prolonged wound care, repeated dressings, visible scar formation, patient discomfort, and interruption of breastfeeding. Recent advances in ultrasonography have enabled minimally invasive management using ultrasound-guided needle aspiration.

Ultrasound-guided aspiration offers several advantages including reduced tissue trauma, shorter hospital stay, faster wound healing, better cosmetic outcomes, and continuation of lactation. The present study was undertaken to compare the outcomes of conventional incision and drainage with ultrasound-guided minimally invasive aspiration in the management of breast abscess.

## 2. Aim and Objectives

### Aim

To compare conventional incision and drainage with ultrasound-guided needle aspiration in the management of breast abscess.

### Objectives

- To compare residual abscess formation in both treatment groups.
- To compare recurrence rates following treatment.
- To evaluate healing time in both modalities.
- To assess resumption of breastfeeding in lactating mothers.
- To compare cosmetic outcomes and scar formation.

## 3. Materials and Methods

### Study Design

Prospective randomized comparative study.

### Study Setting

Department of General Surgery, Saraswathi Institute of Medical Sciences, Hapur, Uttar Pradesh.

### Study Duration

9 months.

Volume 15 Issue 5, May 2026

Fully Refereed | Open Access | Double Blind Peer Reviewed Journal

[www.ijsr.net](http://www.ijsr.net)

**Sample Size**

A total of 50 patients diagnosed with breast abscess were included in the study.

**Inclusion Criteria**

- Patients aged more than 12 years.
- Clinically and ultrasonographically diagnosed breast abscess.
- Patients willing to participate and provide informed consent.

**Exclusion Criteria**

- Tubercular breast abscess.
- Recurrent or chronic breast abscess.
- Patients unwilling to participate.

**Methodology**

Patients were randomly allocated into two groups:

**Group A**

Conventional incision and drainage.

**Group B**

Ultrasound-guided needle aspiration/re-aspiration under antibiotic coverage.

All patients received empirical antibiotic therapy initially, which was later modified according to culture and sensitivity reports.

Follow-up ultrasonography was performed on postoperative days 3 and 7 to evaluate residual collection.

Patients were followed for:

- Residual abscess
- Recurrence
- Healing time
- Resumption of lactation
- Cosmetic outcome

**Statistical Analysis**

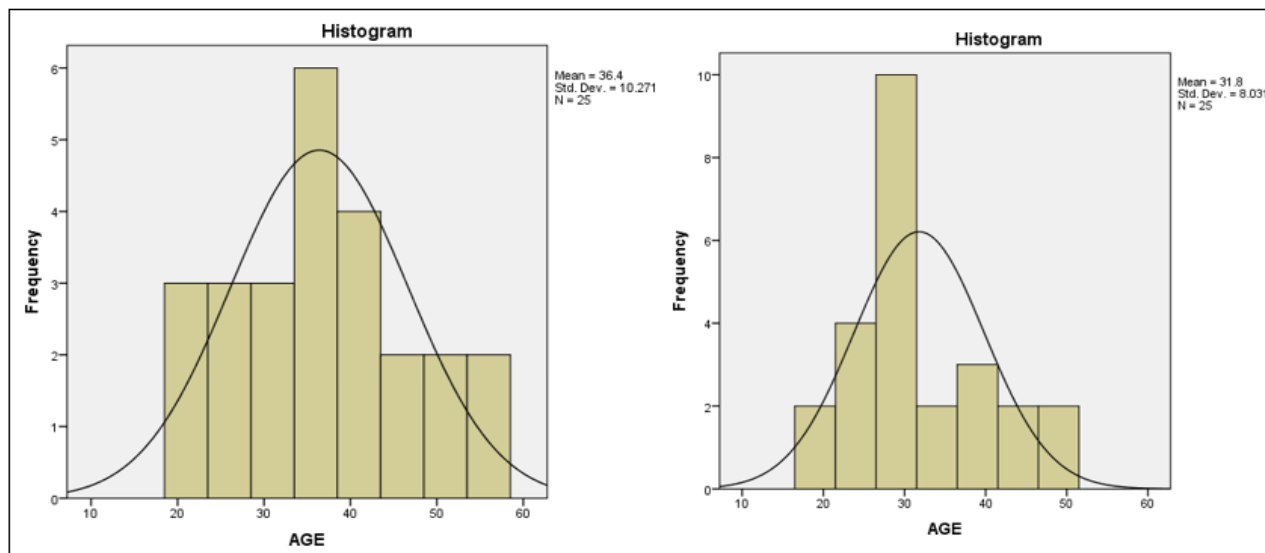
Collected data were analyzed using appropriate statistical methods. Student’s t-test was applied for comparison of healing times between the two groups. A p-value of <0.05 was considered statistically significant.

**4. Results**

A total of 50 patients were studied, with 25 patients in each treatment group.

Most patients belonged to the reproductive age group, and lactational abscess constituted most cases.

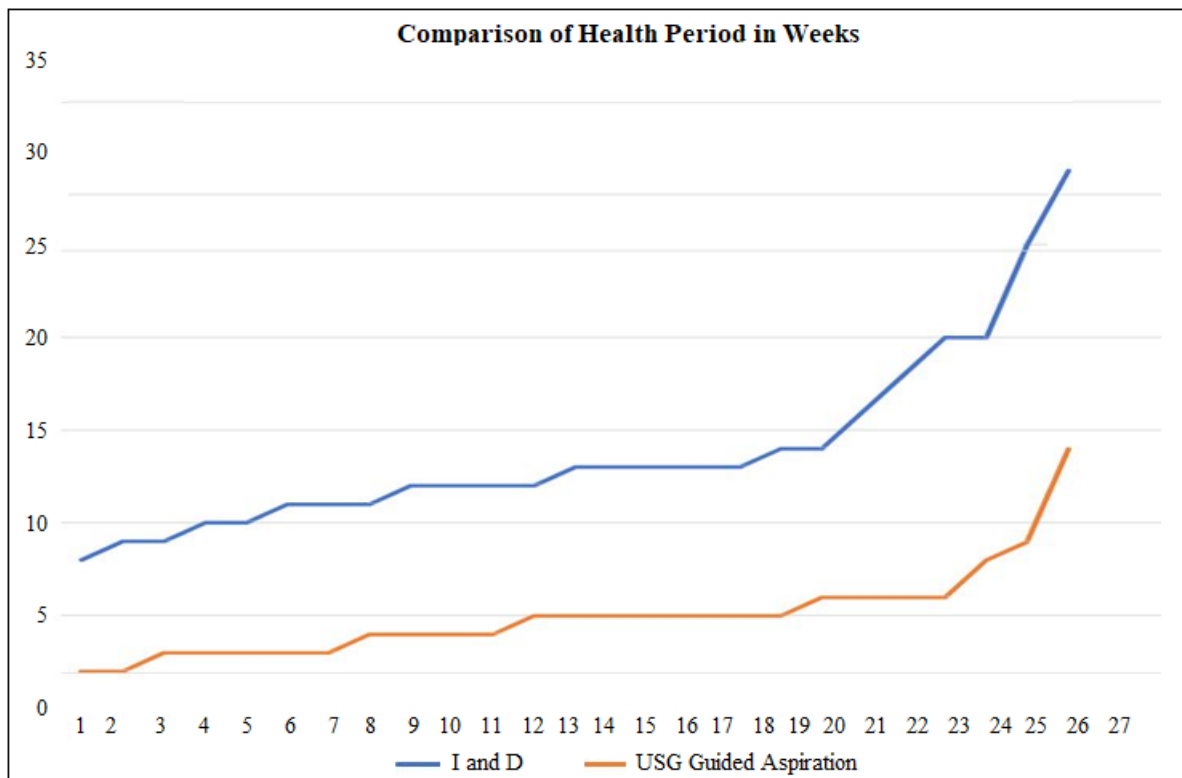
Age Distribution	I and D	USG Guided Aspiration
N	25	25
Mean	36.4	31.8
Median	35	30
Mode	34	30
Std. Deviation	10.27132	8.03119
Minimum	21	19
Maximum	56	48



**Healing Time**

Patients treated with ultrasound-guided aspiration demonstrated significantly faster healing compared to the incision and drainage group.

Characteristic	I and D group	USG Guided Aspiration Group
Mean	13.92	5
Median	13	5
Mode	13	5
Std. Deviation	5.01597	2.51661
Minimum	8	2
Maximum	29	14



**Residual Abscess**

Residual abscess on postoperative follow-up was lower in the ultrasound-guided aspiration group.

Residual abscess on 7 <sup>th</sup> post-operative day	Management (Method)		Total	Chi-square test p-value
	I AND D	USG Guided Aspiration		
No	16 (64%)	22 (88%)	38	3.947 P=0.047
Yes	9 (36%)	3 (12%)	12	Significant
Total	25	25	50	

**Recurrence**

Recurrence rates were lower in patients managed with ultrasound-guided aspiration.

Recurrence after two weeks	Management (Method)		Total	Chi-square test p-value
	I AND D	USG Guided Aspiration		
No	18 (72%)	25 (100%)	43	8.857 P=0.012
Yes	7 (28%)	0	7	Significant
Total	25	25	50	

**Lactation**

A higher proportion of lactating mothers resumed breastfeeding in the aspiration group compared to the conventional incision and drainage group.

Resumption of lactation in lactating patients	Management (Method)		Total	Chi-square test p-value
	I AND D	USG Guided Aspiration		
No	8 (80%)	1 (8.33%)	9	11.82 P=0.003
Yes	2 (20%)	0	7	Highly Significant
Total	10	12	50	

**5. Discussion**

Breast abscess remains a common surgical condition, especially among lactating women. The traditional approach of incision and drainage effectively evacuates pus but often causes prolonged morbidity due to open wound care, repeated dressings, pain, and scar formation.

The findings of the present study suggest that ultrasound-guided needle aspiration is associated with superior patient outcomes compared to conventional incision and drainage. Faster healing observed in the aspiration group may be attributed to minimal tissue trauma and preservation of surrounding breast tissue.

Reduced recurrence and residual abscess rates indicate that ultrasound guidance allows precise localization and complete

evacuation of the abscess cavity. Additionally, the minimally invasive nature of the procedure enables better cosmetic outcomes with minimal scarring.

An important advantage noted in this study was better continuation of breastfeeding among lactating mothers treated with ultrasound-guided aspiration. Preservation of lactation is critical for maternal and infant health and contributes significantly to patient satisfaction.

These findings are consistent with previously published studies advocating minimally invasive management as the preferred first-line treatment for uncomplicated breast abscess.

## 6. Conclusion

Ultrasound-guided needle aspiration is an effective, safe, and minimally invasive treatment modality for breast abscess. Compared to conventional incision and drainage, it offers:

- Faster healing
- Reduced recurrence
- Better cosmetic outcomes
- Less postoperative morbidity
- Improved continuation of breastfeeding

Therefore, ultrasound-guided aspiration should be considered the preferred initial treatment option for appropriately selected patients with breast abscess.

## 7. Limitations

- Relatively small sample size.
- Single-center study.
- Short duration of follow-up.

Further multicentric studies with larger sample sizes are recommended.

## References

- [1] Bailey H, Love RJM. Bailey & Love's Short Practice of Surgery. 28th ed. CRC Press; 2022.
- [2] Townsend CM, Beauchamp RD, Evers BM, Mattox KL. Sabiston Textbook of Surgery. 21st ed. Elsevier; 2021.
- [3] Dixon JM. Breast infection. *BMJ*. 2013;347:f3291.
- [4] Christensen AF, Al-Suliman N, Nielsen KR, et al. Ultrasound-guided drainage of breast abscesses: results in 151 patients. *AJR Am J Roentgenol*. 2005;184(2):399-404.
- [5] Imperiale A, Zandrino F, Calabrese M, et al. Abscesses of the breast: US-guided serial percutaneous aspiration and local antibiotic therapy after unsuccessful systemic antibiotic therapy. *Acta Radiol*. 2001;42(2):161-165.
- [6] Schwarz RJ, Shrestha R. Needle aspiration of breast abscesses. *Am J Surg*. 2001;182(2):117-119.
- [7] Berna-Serna JD, Madrigal M, Berna-Mestre JD. Percutaneous management of breast abscesses. An experience of 39 cases. *Ultrasound Med Biol*. 2004;30(1):1-6.
- [8] Eryilmaz R, Sahin M, Hakan Tekelioglu M, Daldal E. Management of lactational breast abscesses. *Breast*. 2005;14(5):375-379.
- [9] Karvande R, Yadav S, Bhole A. Comparative study between conventional incision and drainage versus ultrasound-guided aspiration in breast abscess management. *Int Surg J*. 2019;6(3):811-815.
- [10] Ulitzsch D, Nyman MK, Carlson RA. Breast abscess in lactating women: US-guided treatment. *Radiology*. 2004;232(3):904-909.
- [11] Hook GW, Ikeda DM. Treatment of breast abscesses with US-guided percutaneous needle drainage without indwelling catheter placement. *Radiology*. 1999;213(2):579-582.
- [12] Chandika AB, Gakwaya AM, Kiguli-Malwadde E, Chalya PL. Ultrasound-guided needle aspiration versus surgical drainage in management of breast abscesses: a Ugandan experience. *BMC Res Notes*. 2012;5:12.
- [13] Benson EA, Goodman MA. Incision with primary suture in the treatment of acute puerperal breast abscess. *Br J Surg*. 1970;57(1):55-58.
- [14] O'Hara RJ, Dexter SP, Fox JN. Conservative management of infective mastitis and breast abscesses after ultrasonographic assessment. *Br J Surg*. 1996;83(10):1413-1414.
- [15] Bharat A, Gao F, Aft RL, et al. Predictors of primary breast abscesses and recurrence. *World J Surg*. 2009;33(12):2582-2586.
- [16] Giess CS, Golshan M, Birdwell RL. Clinical and imaging evaluation of palpable breast abnormalities. *AJR Am J Roentgenol*. 2012;198(2):W173-W180.
- [17] WHO. Guidelines on Maternal, Newborn, Child and Adolescent Health. Geneva: World Health Organization; 2017.
- [18] Walker M. Mastitis in lactating women: physiology or pathology? *Breastfeed Rev*. 2008;16(2):5-12.
- [19] Dener C, Inan A. Breast abscesses in lactating women. *World J Surg*. 2003;27(2):130-133.
- [20] Pesce C, Galimberti V, et al. Conservative and minimally invasive management of breast abscesses. *Breast Care*. 2016;11(4):276-280.