

# Ultrasonography and Histopathological Correlation in Differentiating Breast Masses

Dr. Chetna Singh<sup>1</sup>, Dr. Anjana J Patel<sup>2</sup>, Dr. Niket Domadiya<sup>3</sup>, Dr. Mohit Sehrawat<sup>4</sup>, Dr. Navdeep Singh<sup>5</sup>

<sup>1</sup>Resident Doctor, Third Year

<sup>2</sup>Professor and Head of Department, Department of Radiology (Pandit Deendayal Upadhyay Government Medical College & Civil Hospital, Rajkot, Gujarat, India)

<sup>3</sup>Assistant Professor

<sup>4</sup>Resident Doctor, Second Year

<sup>5</sup>Resident Doctor, Second Year

**Abstract:** **Background:** Breast lump in any age group is addressed cautiously to exclude the possibility of breast cancer. The clinical approach to breast lump involves the "triple test" for screening. Triple test includes clinical examination, imaging (ultrasonography and mammogram) and tissue sampling (FNAC and biopsy). These tests happen in a sequential manner and it is important that their findings support the final diagnosis for accurate management of the patient. Imaging modality the (ultrasonography and mammogram) have good sensitivity and specificity in the breast lesions and can be reliably use as a preliminary test in breast lump evaluation. In discordant cases, core needle biopsy with FNAC (fine needle aspiration cytology) used for final diagnosis. Therefore, the aim of this study was to evaluate the clinical, imaging and histopathological features of breast lesions in patients. The secondary objective was to investigate the relationship between radiological characteristics and histopathological features. **Materials and Methods:** A prospective observational study was conducted at PDU Medical College and Hospital, Rajkot, over a period of 1.5 years involving 200 patients with clinically suspected breast lesions. **Results:** Most lesions were benign on ultrasonography (78%) and histopathology (75%). The sensitivity, specificity, PPV, NPV and accuracy of ultrasonography were 80%, 97.3%, 90.9%, 93.6% and 93% respectively. Fibroadenoma was the most common benign lesion while invasive ductal carcinoma was the most common malignant lesion. **Conclusion:** Ultrasonography demonstrates high diagnostic accuracy and strong correlation with histopathological findings in differentiating benign and malignant breast lesions.

**Keywords:** Breast masses, Ultrasonography, Histopathology, BI-RADS, Breast carcinoma, Fibroadenoma

## 1. Background

Breast lesions encompass a wide spectrum of benign and malignant pathologies. Early diagnosis and differentiation are essential for appropriate management. Ultrasonography has emerged as a highly valuable imaging modality because of its non-invasive nature, lack of ionizing radiation and high sensitivity in evaluating breast masses, especially in dense breasts and younger women. Histopathological examination remains the gold standard for diagnosis. The present study evaluates the sonographic characteristics of breast lesions and correlates them with histopathological findings.

### Aims and Objectives

- 1) The aim of this study is to evaluate the role of ultrasonography and FNAC/biopsy in diagnosis of breast masses and in its characterization and differentiation.
- 2) To investigate the incidence of different types of breast lesions at PDU medical college and Hospital, Rajkot.
- 3) To give early diagnosis of the breast carcinoma to reduce mortality and morbidity.

## 2. Materials and Methods

This prospective observational study was carried out at PDU Medical College and Hospital, Rajkot, over a duration of 1.5 years. A total of 200 patients with complaints of breast lump, breast heaviness, nipple discharge, skin changes or family history of breast carcinoma were included. Ultrasonography

was performed using SAMSUNG RS80 EVO and SAMSUNG ACCUVIX XG machines. Lesions were evaluated according to BI-RADS descriptors including shape, margins, echogenicity, posterior acoustic features and vascularity. Histopathological examination was used as the reference standard.

## 3. Results

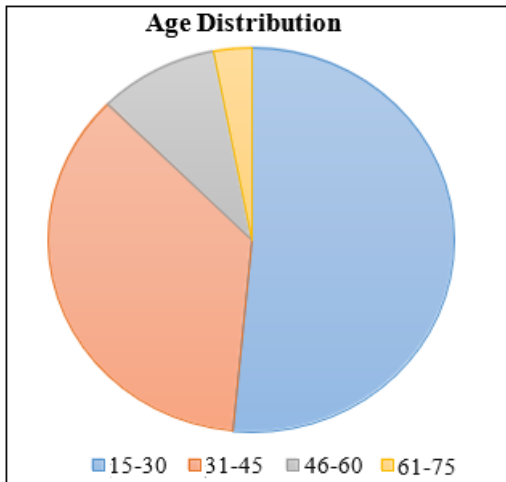
- Majority of patients belonged to the 15–30 years age group (51.5%).
- Unilateral breast involvement was observed in 92% cases.
- Upper outer quadrant was the most common site of lesion (54%).
- Single lesions were noted in 75% cases.
- BI-RADS II lesions constituted 62% of the cases.
- Benign lesions accounted for 78% on ultrasonography and 75% on histopathology.
- Fibroadenoma was the most common benign lesion (48%).
- Invasive ductal carcinoma was the most common malignant lesion (12.5%).
- Ultrasonography demonstrated sensitivity of 80%, specificity of 97.3% and diagnostic accuracy of 93%.

**Key Statistical Findings**

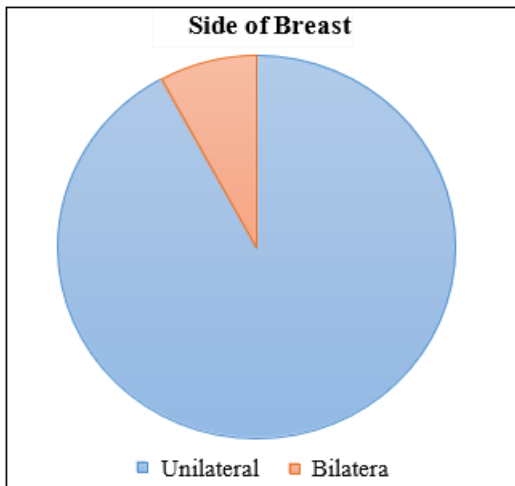
Parameter	Value
Sensitivity	80%
Specificity	97.3%
Positive Predictive Value	90.9%
Negative Predictive Value	93.6%
Diagnostic Accuracy	93%

**Graphs**

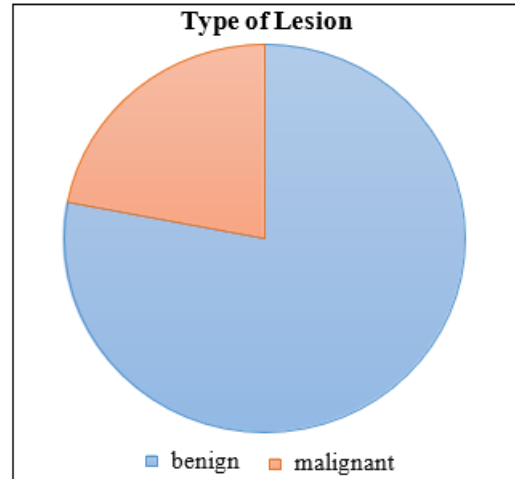
Among the 200 patients, most patients fall in the age group of 15-30 years constituting approximately 51.5% of the total patients.



Among the 200 patients, abnormalities were noted in the unilateral side in 92 % patients and in both breasts in 8% patients.



Among the 200 patients, on USG, 78% patients fall in the benign category, 22 % in malignant category.



**Final Assessment after Combined Sonography and Histopathological Evaluation of Breast Lesions**

	HPE Malignant lesions	HPE benign lesions	Total
USG Malignant lesions	40(TP)	4(FP)	44
USG Benign lesions	10(FN)	146(TN)	156
Total	50	150	200

**4. Discussion**

This prospective observational study was conducted in the Department of Radiodiagnosis at P.D.U. Medical College and Hospital, Rajkot, including **200 female patients** presenting with breast complaints.

The **maximum number of patients (51.5%)** belonged to the **15–30 years age group**, indicating a predominance of breast lesions in younger women. Most lesions were **unilateral (92%)** and **single in number (75%)**, with the **upper outer quadrant (54%)** being the most common site of involvement.

On imaging assessment using BI-RADS classification, the majority of cases were categorized as **BI-RADS II (62%)**, followed by BI-RADS III (16%), BI-RADS IV (12%), and BI-RADS V (10%).

Ultrasonography revealed that **78% of lesions were benign**, while **22% were malignant**, whereas histopathological examination showed **75% benign and 25% malignant lesions**, indicating good concordance.

Among benign lesions, **fibroadenoma (48%)** was the most common diagnosis, followed by **abscess (9%)**, **cysts (8%)**, and fibrocystic disease. Among malignant lesions, **invasive ductal carcinoma (12.5%)** was the most frequent, followed by ductal carcinoma in situ.

Diagnostic performance of ultrasonography showed **80% sensitivity, 97.3% specificity, 90.0 % PPV, 93.6% NPV and 93% accuracy**

A statistically significant correlation was observed between USG and histopathology ( $p < 0.0001$ ), confirming the reliability of ultrasonography in differentiating breast lesions.

## 5. Conclusion

The study highlights the following key conclusions:

- **Ultrasonography shows high specificity and good sensitivity**, making it an excellent screening and diagnostic tool.
- **Strong correlation between sonographic and histopathological findings** supports the diagnostic accuracy of imaging.
- **Combined use of USG and FNAC/biopsy significantly improves diagnostic precision**, reducing false-positive and false-negative results. Clinically, the study reinforces that:
- USG should be the **first-line modality in women <40 years**
- Histopathology remains the **gold standard for definitive diagnosis**

A **multidisciplinary approach involving radiologist, pathologist, and clinician** is essential for optimal patient management.

## References

- [1] Nafisa Bello et al. Correlation of Sonographic and Histopathologic Findings in Breast Masses.
- [2] Hafsat Oluwatosin Akinnibosun-Raji et al. Correlation of Sonographic Findings and Histopathological Diagnoses in Women Presenting With Breast Masses.
- [3] Raj Bhesdadiya et al. Mammographic and Ultrasonographic Evaluation of Breast Lesions with Pathological Correlation.