

Evaluation of the Eustachian Tube Angles in Patients with Chronic Otitis Media Using High Resolution Computed Tomography (HRCT)

Dr. Manali P Joshi¹, Dr. Sarang S Gosavi², Dr. Vishal Magdum³, Dr. Rahul S Gosavi⁴

¹Assistant Professor, Sanjeevan ENT Institute, Miraj, India

²Consultant Radiologist, Sanjeevan ENT Institute Miraj, India

³Associate Professor, Sanjeevan ENT Institute Miraj, India

⁴Assistant Professor, Sanjeevan ENT Institute Miraj, India

Abstract: *Chronic otitis media remains closely linked to structural and functional changes within the middle ear, and this study examines how Eustachian tube angulation may contribute to that relationship using high resolution computed tomography. Through a retrospective evaluation of fifty patients with unilateral chronic otitis media, measurements of Reid plane Eustachian tube angle and tubotympanic angle were compared between diseased and healthy ears. The diseased ears showed lower Reid plane Eustachian tube angles and higher tubotympanic angles, with statistically meaningful differences between both sides. These findings support the view that altered Eustachian tube orientation may influence middle ear ventilation, disease progression, and susceptibility to chronic infection. The observed patterns also align with earlier anatomical studies, strengthening the argument that radiologic angle assessment may have diagnostic and preoperative value. Despite limitations related to sample size, the study highlights the relevance of temporal bone anatomy in understanding chronic otitis media and suggests that Eustachian tube angle measurements may serve as a useful marker in predicting dysfunction and guiding surgical planning.*

Keywords: Chronic otitis media, Eustachian tube angle, HRCT temporal bone, Tubotympanic angle, Middle ear ventilation

1. Introduction

- Chronic otitis media (COM) is characterized by hearing loss, chronic infection, and inflammation of the middle ear and mastoid air space.
- The detection time of COM is important because medical and surgical treatment can prevent intracranial and extracranial complications of this disease.
- Middle ear cholesteatomas consist of ectopic keratinized epithelial tissue that grows inside the mucosa-lined middle ear cavity and desquamates, accumulating keratin and epithelial debris leads to bone erosion.
- Bony erosion can result in destruction of the ossicles, creating conductive hearing loss, labyrinthine fistulas with sensorineural hearing loss and vertigo, facial nerve canal erosion and facial paralysis, and rare intracranial complications, such as meningitis and abscess formation.

Aim

To evaluate the Eustachian tube angles in patients with chronic otitis media.

Measurement planes

- Reid horizontal plane is the line joining bilateral inferior orbital wall and superior walls of the bilateral external ear canal. This plane is considered to be the position at which the head in a neutral anatomical position.
- Reid plane-eustachian tube angle is defined as the angle between tympanic pharyngeal orifice and Reid plane.
- Tubotympanic angle is defined as the angle of the longitudinal axis of the eustachian tube along the tympanic orifice and the longitudinal axis of the center the bony external ear canal in the axial plane.

2. Materials and methods

- A retrospective study was carried in the Department of Radio-diagnosis.
- Scans were performed on GE ACT REVOLUTION 16 slice scanner.
- Sample size-50 patients
- Written informed consent was taken
- Statistical significance between the diseased and healthy ear was calculated. P- value <0.05 was considered to be statistically significant.

Inclusion criteria:

- Patients above 15 years of age with clinical suspicion of unilateral chronic otitis media

Exclusion criteria:

- Patients who underwent HRCT temporal bone for other causes eg. Trauma
- Bilateral chronic otitis media
- Patients with previous ear surgery.
- Pregnant females.

3. Techniques

- The horizontal plane, crossing bilateral inferior orbital wall and the bilateral upper wall of the external ear canal bilateral plane known as 'Reid horizontal plane' was selected. The orifices of eustachian tubes were identified in the same section by using multiplanar reconstruction technique in the coronal images.
- Pharyngeal and tympanic orifices of the eustachian tubes were demonstrated exactly at the same section. This

Volume 15 Issue 4, April 2026

Fully Refereed | Open Access | Double Blind Peer Reviewed Journal

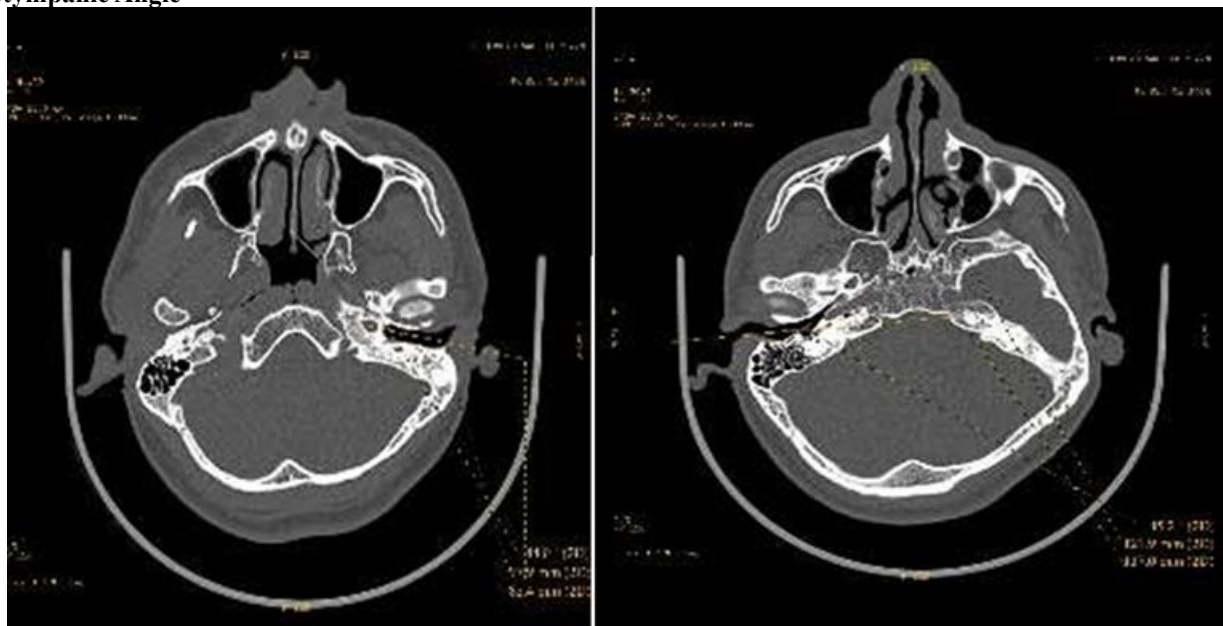
www.ijsr.net

direction was determined as the line of the eustachian tube.

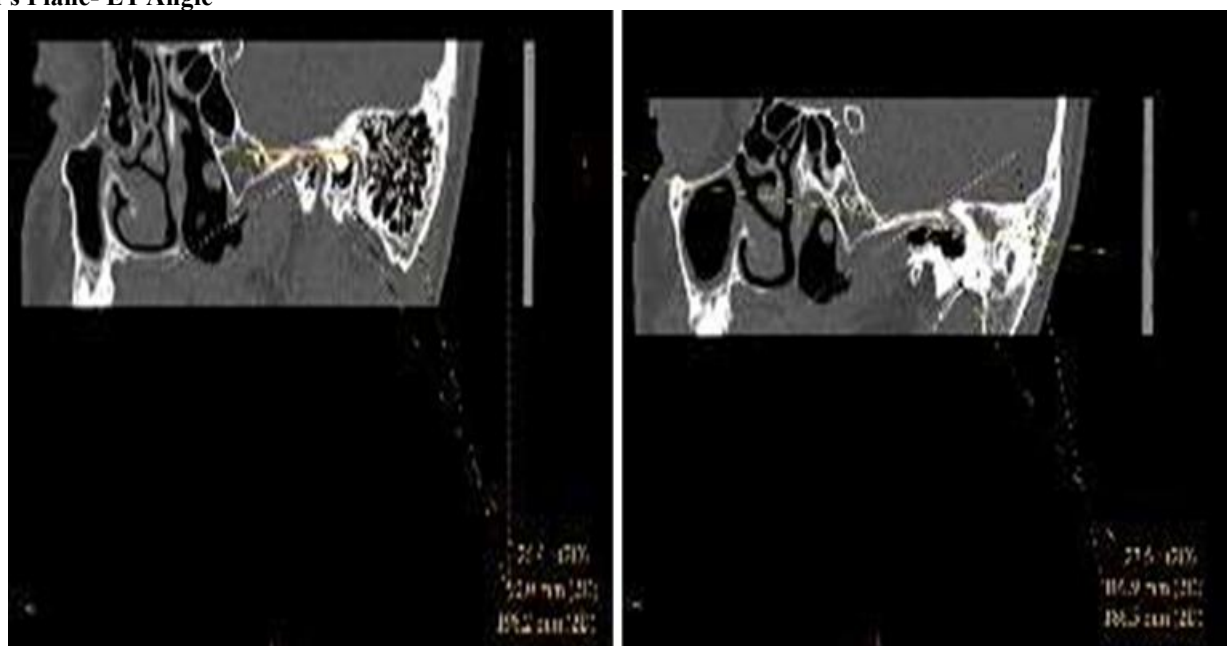
- The angle was measured between the horizontal plane and this line

- Tubotympanic angle was considered the angle between the line extending through the tympanic orifice of the eustachian tube and the center of the longitudinal axis drawn from the bony external ear canal at the center.

Tubotympanic Angle



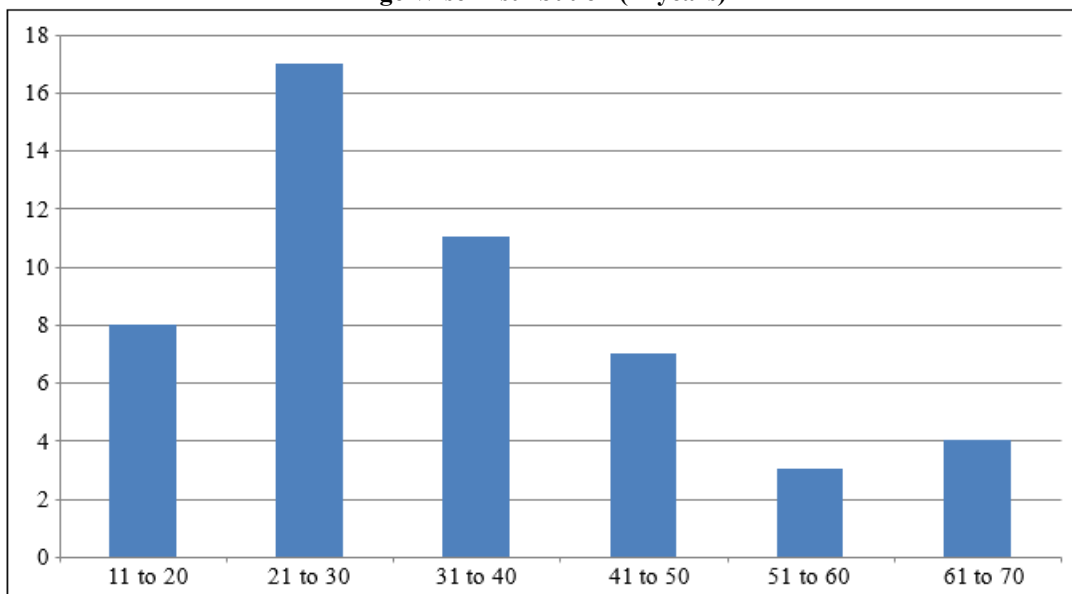
Reid's Plane- ET Angle



Age Wise Distribution

Age (In Yrs)	Number	Percentage (%)
11-20	8	16
21-30	17	34
31-40	11	22
41-50	7	14
51-60	3	6
61-70	4	8

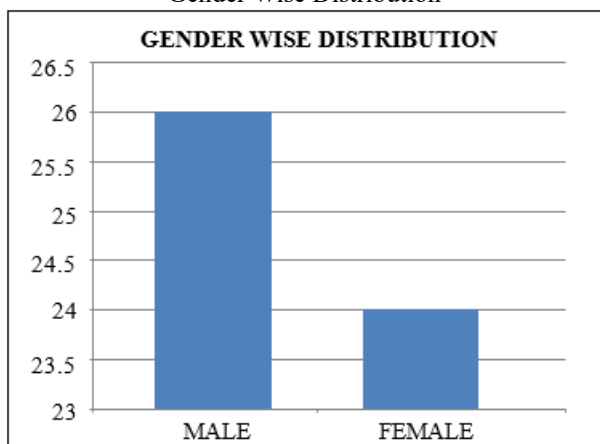
Age Wise Distribution (in years)



Gender Wise Distribution

Gender	Number	Percentage (%)
Male	26	52
Female	24	48

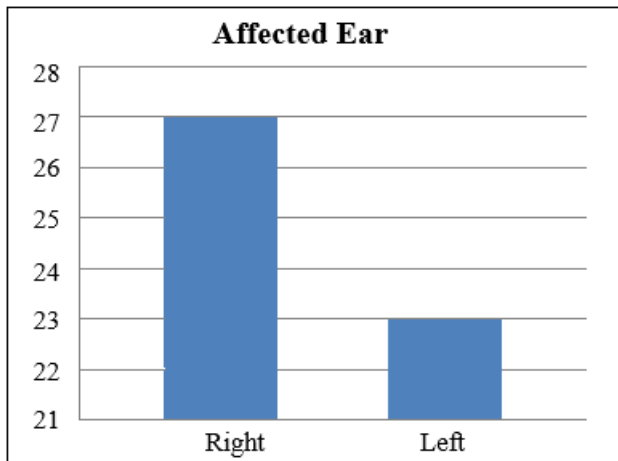
Gender Wise Distribution



Affected Ear

Affected Ear	Number	Percentage (%)
Right	27	54
Left	23	46

Affected Ear



4. Results

- The Reid-Eustachian tube angle varied between 25.9+/- 2.5 degrees in diseased ear.
- The Reid-Eustachian tube angle varied between 28+/- 1.5 degrees in healthy ear.
- The tubotympanic angle varied between 148+/- 4 degrees in diseased ear.
- The tubotympanic angle varied between 145+/- 4.2 degrees in healthy ear.
- Reid-Eustachian tube angle of diseased ears were statistically significantly lower than the healthy ear (p value 0.02, <0.05).
- Tubotympanic angles of diseased ears were statistically significantly higher than the healthy ear (p value <0.001, <0.05).

5. Discussion

- Genetic and environmental factors are thought to increase the progression of chronic conditions.
- According to the genetic theory of the temporal bone pneumatization, the pneumatization is genetically determined and bad pneumatized ears are candidates for COM.
- The environmental theory supporters claim that environmental factors such as frequent upper respiratory tract infections, poor living conditions and smoking that causes chronic otitis media make reduced temporal air pneumatization.
- In one study, the angle of infants according to the horizontal plane of the eustachian tube is approximately 10° and in adults it is reported to reach up to about 45°.
- In another study in adults in the sagittal plane, the angle is 45 degrees.
- Graves and Edward found the angle between 30 and 40° in adults with the horizontal plane.
- These differences between children and adults are not limited to angles.

- Other differences compared adults to children and infants are -the eustachian tube is shorter and looser in the children
- Takasaki et al. detected the eustachian tube angles in Reid plane $27.3^{\circ} \pm 2^{\circ}$ for the right ear, $27.3^{\circ} \pm 2.8^{\circ}$ for the left ear in the normal adult population.
- In a study by Aksoy S et al., they found the Reid plane-ET angle as 26.85 ± 4.04 degrees and tubotympanic angle as 146.29 ± 5.82 degrees.
- In another study, Reid plane- ET angle was 25.41 ± 2.57 degrees and tubotympanic angle was 148.12 ± 3.43 degrees.
- These values are similar to those in this study.
- Reduced Reid plane-ET angle may affect pneumatization of mastoid due to inadequate ventilation of middle ear and mastoid through ET, thus contributing to development of COM.
- Increased tubotympanic angle increases the chances of upper respiratory infections spreading to middle ear and contributing to development of COM.

6. Limitations

- Smaller sample size
- Limited amount of research available

7. Conclusions

- Eustachian tube angles in adults play a significant role in etiology of chronic otitis media.
- Decrease in Reid plane-ET angle can be used to predict ET dysfunction and helps in surgical planning.

References

- [1] Aksoy S, Sayin I, Yazici Z M, Kayhan F T, Karahasanoglu A, Hocaoglu E, Inci E. The evaluation of the angles of Eustachian tubes in the patients with chronic otitis media on the temporal computerized tomography. Niger J Clin Pract 2016; 19: 318-22
- [2] Tumarkın A. On the nature and vicissitudes of the accessory air spaces of the middle ear. J Laryngol Otol 1957; 71:65-99.
- [3] Yoshida H, Kobayashi T et al. Imaging of the patulous eustachian tube: HRCT evaluation with MPR. Acta Otolaryngol 2004; 124: 918-923.
- [4] Cho ZH. 7.0 Tesla MRI Brain Atlas: *In Vivo* Atlas with Cryomacrotome Correlation. Introduction 2; 2010.
- [5] Fujii N, Inui Y, Katada K. Temporal bone anatomy: Correlation of multiplanar reconstruction sections and three-dimensional computed tomography images. Jpn J Radiol 2010; 28: 637-48.
- [6] Nemade S, Shinde K, Rangankar V et al. Evaluation and significance of Eustachian tube angles and pretympnic diameter in HRCT temporal bone of patients with chronic otitis media. World Journal of Otorhinolaryngology. Head and neck surgery (2018); 4: 240-245