

Amyand Hernia: A Rare Case Report

Dr. Jainam Mehta¹, Dr. Jignesh Dave²

¹2nd Year Resident Doctor General Surgery, PDU Civil Hospital, Rajkot

²Associate Professor, General Surgery Department, PDU Civil Hospital, Rajkot

Abstract: *Introduction and importance:* Amyand's hernia (AH) is a form of inguinal hernia which is considered as very rare and this type of hernia occurred up to 1% of all inguinal hernia cases. In this type of inguinal hernia, the content of hernia sac is appendix. Most patient with Amyand hernia often remains asymptomatic and diagnosed intraoperatively. The diagnosis is challenging, since needs a high index of suspicion and imaging is key. Surgery is the mainstay management.

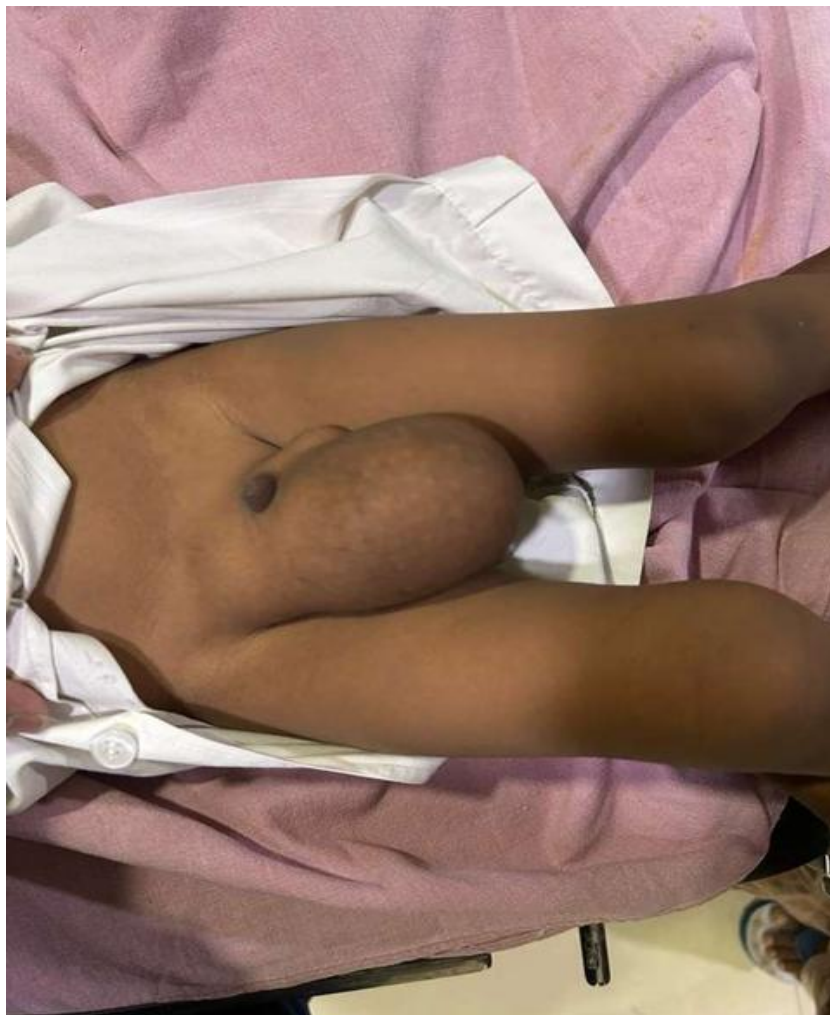Keywords: Amyand's hernia, (AH) vermiform appendix, , Inguinal hernia, Congenital Hydrocoele

Abbreviations: AH: Amyand's hernia

1. Case Presentation

A 2 year old child who had a history of right-side reducible inguino-scrotal swelling since birth, was admitted for elective right inguinal hernia repair. Swelling is associated with fever but not Associated with pain and Tenderness. Ultrasound of the abdomen reported 4-5 mm gap defect suggestive of right inguinal hernia likely. There was no history of abdominal pain and vomiting. Laboratory parameters suggestive of high wbc

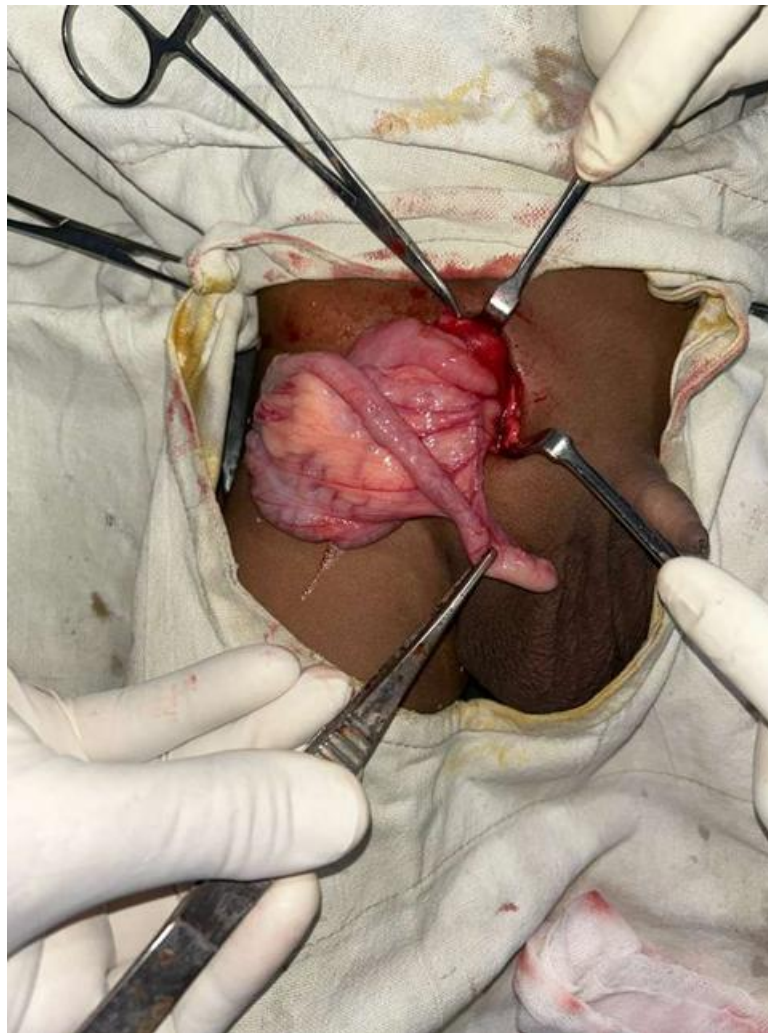
count. So, with a diagnosis of right sided congenital hernia made, patient was operated for open hernia repair surgery, intra operatively we found dense adhesions within the sac with right congenital hydrocele, adhesions were released which revealed herniation of appendix into the inguinal canal. Appendix was found normal. Hence, in view of noninflamed appendix, right side high ligation of sac done with right side jabouleys eversion of sac without appendectomy. Postoperative period was uneventful, patient discharged at second day.



Volume 15 Issue 1, January 2026

Fully Refereed | Open Access | Double Blind Peer Reviewed Journal

www.ijsr.net



2. Clinical Discussion

Amyand's hernia is very uncommon and characterized by the presence of the appendix in the hernia sac and it is 0.4–1% of all inguinal hernia cases, literature review also showed that incidence of Amyand's hernia is very rare, whereas only 0.1% of cases complicate into acute appendicitis due to late presentation and missed diagnosis.

3. Conclusion

Amyand's hernia (AH) makes up only a small proportion of most inguinal hernia cases, and its diagnosis is usually based on incidental finding intra-operatively. This condition may remain asymptomatic and behave like a normal inguinal hernia. Management of this type of hernia should be individualized according to appendix's inflammation stage, presence of abdominal sepsis and co-morbidity. With this approach it enables surgeons to manage more variations of Amyand's hernia. Laparoscopy for dealing Amyand's hernia is frequently diagnostic as well as therapeutic.

4. Background

An inguinal hernia is a protrusion of abdominal-cavity contents through the inguinal canal. Inguinal hernia sac contains any abdominal organ including small or large bowel. Amyand's hernia is a very rare and uncommon form of

inguinal hernia where the vermiform appendix is present in hernia sac. The incidence of having abnormal appendix within the hernia sac varies from 0.5% to 1% [1], [2], [3], [4].

The entity of Amyand's hernia has an incidence of 1% and is complicated by acute appendicitis in 0.8 to 0.13% of case, whereas only 0.1% of cases complicate into acute appendicitis [1], [2], [3], [8], [12].

Incarcerated bowel containing hernias are the leading cause of mechanical bowel obstruction. Prompt surgical intervention is indicated due to increased changes of strangulation [2], [4].

It affects both adults and kids along with also the contents of the gut sac might change from Cecum, liver, uterus, fallopian tube, omentum, or some Meckel's diverticulum along with an appendix. It received its name since the first man to report that the existence of perforated appendix was Claudius Amyand in 1735 [1], [2], [3], [4], [6].

The surgeon might encounter unusual signs, like a Vermiform appendix partially or fully found in the hernia sac, inflamed or non-inflamed or adherent into the sac walls. An inguinal hernia does not specific for age sex or group; as reported in literature, cases of Amyand's hernia found in the neonatal period, although left-sided Amyand's hernia is reported as well [1], [2], [3].

Losanoff along with the Bass-on classification System which clarifies the advocated surgical treatment selections for different kinds of Amyand's hernia. This approach will enable surgeons to recognize and manage more variations of Amyand's hernia [3] Types of Amyand's hernias and their Management [11] (Table 1).

5. Case Presentation

5.1 Patient information

A 2 year old male child presented to a surgical department clinic with complaint of a swelling in the right inguinal region since birth with fever since 7 day initially it was small and gradually increase in size and not associated with pain. This swelling causing no symptoms, so the patient did not seek any medical advice for it. There was no history of abdominal pain and vomiting.

5.2 Physical examination

On examination, there was an indirect right inguinal hernia incomplete, and reducible type with positive cough impulse.

5.3 Diagnostic assessment

Patient was diagnosed clinically as right congenital indirect inguinal hernia. Hematological workup was suggestive of increase WBC count.

5.4 Intervention

A Preoperative diagnosis of right congenital inguinal hernia was made and was planned for high ligation of sac, during surgery under general anesthesia, the hernia sac was found to contain an appendix. The appendix was found normal, not inflamed but there were hydrocoele sac also present so right side high ligation sac with right Jabouley's eversion of sac done postoperative period was uneventful. The patient postoperatively received fluid therapy, Oral fluids were administered after 6 h along with soft diet and was discharged on postoperative day 2.

5.5 Follow-up and outcome

The patient was discharged on second post-operative day without any complications on oral anti-biotics and followed up after one week of surgery

6. Discussion

Amyand's hernia (AH), the disease has been originally clarified and handled in 1735 in Claudius [1], [2], [3]. Amyand Losanoff and Basson indicate Amyand's hernia may be dealt with reduction or appendectomy, based on comorbidities, Amyand's hernia accounts for 0.1 percentage of instances of all appendicitis [1], [3], [4], [5], [6]. Appendectomy with simultaneous hernioplasty was completed prophylactically for potential future complication that may lead to appendicitis [11].

The Choice to keep or remove the appendix relies upon the individual's era, endurance, and hazards of expanding acute

appendicitis. The young people include a much greater chance of afflicted by acute appendicitis in contrast for this middle era or elderly men and women [12]. Amyand's hernia is also a rare and hard to diagnose disease, being often occasionally discovered intraoperatively [2], [3], [4].

In terms of inguinal hernia detection, the initial use of ultrasound possibly followed by CT, represents a sensitive and cost-effective progression for the evaluation of the patient with a clinical history suggestive of a hernia, enables the possibility of differentiating affiliated intra-abdominal organs [4], [6].

Therefore, an appendectomy had to be performed to enable structural reduction of the hernia despite the absence of visible signs of acute appendicitis [4].

Considering ultrasound imaging in a large-sized inguinal hernia even if it is reducible may be beneficial in reducing the complications. Early analytical imaging use may confound an instant pre-operative identification of AH. Right-sided Amyand's hernias occur more often than left due to the anatomical location of the appendix on the right. Left-sided Amyand's hernias are very rare [3]. Laparoscopic repair has also been described in pediatric age group [7].

The mainstay management is the open surgery, but in recent years the laparoscopy approach is summing cases; giving benefits of shorter hospital stay, faster recovery, less postoperative pain, among others [12]. While CT scan may help in making a preoperative diagnosis in those cases presented with an acute abdomen the diagnosis of Amyand hernia is usually made intraoperatively [11].

The underlying mechanisms that cause acute appendicitis within an Amyand's hernia include decrease blood supply of the appendix due to adhesions that may cause non-reducibility of the hernia and compression in the external ring originating from increases in intra-abdominal pressure [10]. These factors lead to recurrent inflammation and bacterial overgrowth. The intraoperative manipulations that can by themselves trigger an inflammatory process.

The Losanoff and Basson's classification presented above offer satisfactory guidance system for management of Amyand's hernia [9]. A normal looking appendix in the hernial sac does not always require appendectomy. Appendectomy adds the risk of infection to an otherwise clean procedure. Whether to remove or leave behind a normal appendix is a clinical dilemma because no evidence-based information exists. The decision should be based on common sense, taking into account the patient's age, life expectancy, life-long risk of developing acute appendicitis, and the size and overall anatomy of the appendix.

Definitive preoperative diagnosis poses a challenge due to indistinct clinical signs and symptoms. We report a case that was managed by open surgery in our medium complex public institution with review of the literature. This case report is in line with SCARE 2021 guidelines.

7. Conclusion

Amyand's hernia is a rare presentation of inguinal hernias. In the clinical setting of an incarcerated complicated or strangulated inguinal hernia, the initial approach should consider imaging studies; USG or CT can guide the surgical plan, and enables the possibility of identifying involved intra-abdominal organs. Literature review recommends reducing the hernia content and perform no tension hernia repair, In the cases where an inflamed, suppurative or perforated appendicitis were encountered, no prosthetics material should be used because of the increased risk of surgical site infection. In case of clinical suspicion of Amyand hernia is diagnostic laparoscopy which is useful approach in all forms of incarcerated hernias to assess contents and avoid unnecessary laparotomy. We are still conservative about the application of mesh in hernia sac with acute appendicitis, which requires additional large-scale study to determine whether mesh repair will increase the risk of infection or not.

References

- [1] Faiz N., Ahmad N., Singh R. Case series on different presentations of Amyand's hernia. *Arch. Int. Surg.* 2016; 6: 176–179. [Google Scholar]
- [2] Mishra V.K., Joshi P., Shah J.V. Amyand's hernia: a case of an unusual inguinal hernias. *Indian J. Surg.* 2013 Jun;75(Suppl 1):469–471. doi: 10.1007/s12262-013-0834-3. [DOI] [PMC free article] [PubMed] [Google Scholar]
- [3] Kakodkar P., Neo W., Khan M. An incidental discovery of Amyand's Hernia: a case study and literature review on its intraoperative management. *Cureus.* December 02, 2020;(12) doi: 10.7759/cureus.11858. [DOI] [PMC free article] [PubMed] [Google Scholar]
- [4] Shekhani H.N., Rohatgi S., Hanna T.N., Johnson J. Amyand's hernia: a case report. *Radiol. Case.* 2016 Dec;10(12):7–11. doi: 10.3941/jrcr.v10i12.2833. [DOI] [PMC free article] [PubMed] [Google Scholar]
- [5] Michalinos A., Moris D., Vernadakis S. Amyand's hernia: a review. *Am. J. Surg.* 2014;207(6):989–995. doi: 10.1016/j.amjsurg.2013.07.043. [DOI] [PubMed] [Google Scholar]
- [6] Gao Y., Zhang T., Zhang M., Hu Z., Li Q., Zhang X. Amyand's hernia: a 10-year experience with 6 cases. *BMC Surg.* 2021;21(1):315. doi: 10.1186/s12893-021-01306-z. [DOI] [PMC free article] [PubMed] [Google Scholar]
- [7] Ceulemans L.J., Deferm N.P., Splessens T., Vanhoecker F.M. Amyand's hernia. *J. Belg. Radiol.* 2014;97(3):146–147. [PubMed] [Google Scholar]
- [8] Vehbi H., Agirgun C., Agirgun F., Dogan Y. Preoperative diagnosis of Amyand's hernia by ultrasound and computed tomography. *Turk. J. Emerg. Med.* 2016; 16: 72–74. doi: 10.1016/j.tjem.2015.11.014. [DOI] [PMC free article] [PubMed] [Google Scholar]
- [9] Shaban Y., Elkbuli A., McKenney M., Boneva D. Amyand's hernia: a case report and review of the literature. *Int. J. Surg. Case Rep.* 2018; 47: 92–96. doi: 10.1016/j.ijscr.2018.04.034. [DOI] [PMC free article] [PubMed] [Google Scholar]
- [10] Anagnostopoulou S., Dimitroulis D., Troupis T.G. Amyand's hernia: a case report. *World J. Gastroenterol.* 2006;12:4761–4763. doi: 10.3748/wjg.v12.i29.4761. [DOI] [PMC free article] [PubMed] [Google Scholar]
- [11] Kimberly A.S., Eric M.M., Ross D.E. Two rare cases of appendicitis: Amyand's hernia and de garengot's hernia. *Case Rep. Emerg. Med.* 2019;2019 doi: 10.1155/2019/6759206. [DOI] [PMC free article] [PubMed] [Google Scholar]
- [12] Amyand C. Of an inguinal rupture, with a pin in the appendix caeci incrusted with stone, and some observations on wound in the guts. *Phil. Trans. R. Soc. London.* 1736;39:329–342. [Google Scholar]