

Periurethral Abscess on MRI: A Rare Case Presentation

Dr. Snehali Khilari¹, Dr. Sarfaraz Shaikh²

Department of Radio-diagnosis, DY Patil Hospital, Navi Mumbai

Abstract: *Periurethral abscess is a rare but clinically significant complication of urethral infections, trauma, or obstructive uropathy. Prompt and accurate diagnosis is critical to prevent complications. While ultrasound and computed tomography (CT) are often used initially, magnetic resonance imaging (MRI) offers superior soft-tissue resolution and multiplanar capabilities, making it particularly valuable in delineating abscess extent and adjacent anatomical involvement. In the present study, MRI effectively identifies periurethral abscesses with corpus spongiosum involvement, showing T2 hyperintense, rim-enhancing collections with diffusion restriction. Precise delineation of abscess extent and urethral communication aids surgical planning. MRI's superior soft-tissue resolution is crucial for early diagnosis, preventing complications like fistula formation, sepsis, or chronic urethral damage and guiding targeted management in complex urogenital infections.*

Keywords: Peri-urethral abscess, peri-urethral collection

1. Introduction

Periurethral abscess is an uncommon but clinically significant urological condition resulting from infection or obstruction of periurethral glands, frequently secondary to urethral stricture, trauma, or instrumentation. When untreated or inadequately diagnosed, these abscesses may extend into surrounding structures, including the corpus spongiosum, leading to severe complications such as fistula formation, sepsis, and urethral damage. Clinical symptoms are often nonspecific, including perineal pain, fever, dysuria, and urinary retention, which may delay diagnosis. While ultrasound and computed tomography (CT) can provide initial assessment, magnetic resonance imaging (MRI) offers superior soft tissue contrast and multiplanar imaging capabilities, making it the modality of choice for evaluating the extent of abscess formation and its anatomical relationships. MRI is particularly valuable for identifying involvement of the soft tissue and assessing for communication with the urethra. Early, accurate radiological diagnosis is essential to guide prompt intervention, minimize complications, and improve patient outcomes in these complex presentations.

2. Materials and Methods

This case report describes the clinical and radiological evaluation of a male patient who presented with symptoms suggestive of a periurethral abscess. The patient was referred to the radiology department for advanced imaging to determine the extent of infection and its anatomical relationships.

Patient Background and Clinical Presentation

A 63-year-old male presented with 2 months of history of dysuria, perineal pain, low-grade fever, and a palpable tender swelling in the perineal region. There was no history of trauma, instrumentation, or prior urethral surgery. Laboratory investigations revealed leukocytosis and elevated inflammatory markers. Based on clinical suspicion of a deep-seated urogenital infection, MRI was requested to assess for abscess formation and possible urethral involvement.

MRI Protocol

MRI was performed using a GE signa 3.0 T MRI machine. The patient was scanned in the supine position, and the imaging field of view included the pelvis and perineum. The following sequences were acquired: T1-weighted spin echo sequences in axial and sagittal planes, T2-weighted fast spin echo sequences in axial, coronal, and sagittal planes, Short tau inversion recovery (STIR) axial sequence for fat suppression and Diffusion-weighted imaging (DWI) with corresponding ADC maps.

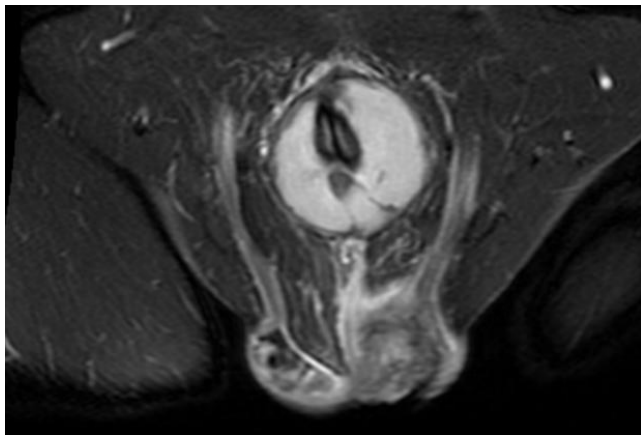
Image Analysis

MRI images were reviewed and the analysis focused on location and extent of the abscess relative to the urethra; Signal intensity on T1, T2, and DWI sequences; Involvement of the corpus spongiosum; Evidence of urethral communication or fistula formation; Presence of adjacent soft tissue inflammation, edema, or lymphadenopathy

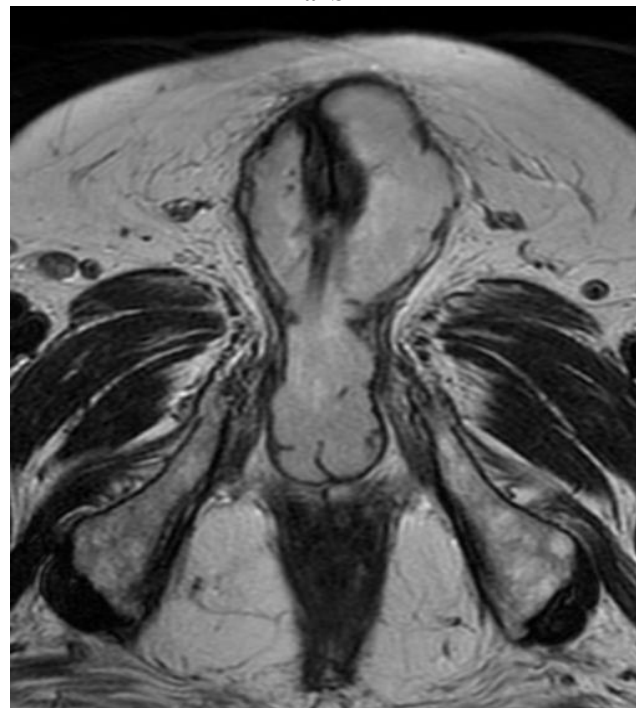
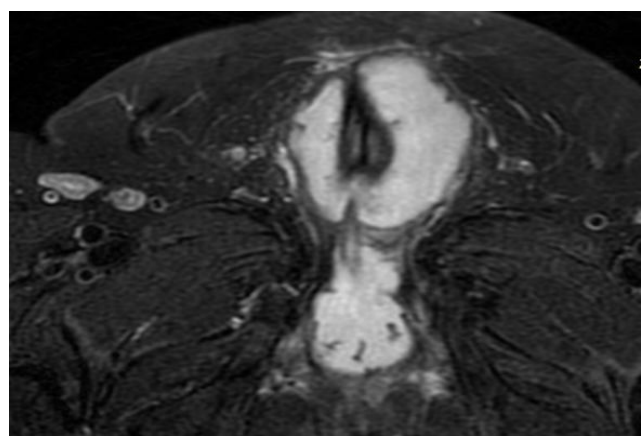
3. Results

A well-defined circumferential area/collection was seen involving the penile body and root with relative sparing of the glans penis. It was seen involving the corpora spongiosum and completely encasing the penile urethra. Antero-superiorly displacing bilateral corpora cavernosa, superiorly it was seen reaching upto inferior margin of the urogenital diaphragm. Inferiorly, almost reaching upto the glans penis. It was seen distending the superficial and deep penile fascia however, no evidence of any significant extension beyond the margins of the fascia was noted. It appears relatively hyperintense on T2W and STIR images and hypointense on T1W image with mild peripheral hyperintensity. It measures approximately 11.3 x 6.4 x 6.0 cm (225 cc) (AP x TR x CC). It showed restricted diffusion on Diffusion weighted images and corresponding drop on ADC images. No evidence of blooming on gradient images was seen. The penile urethra appeared normal in morphology. Similar signal intensity was noted involving a short segment of the distal left corpora cavernosa for a length of 2.9 cm. Few small bilateral inguinal lymph nodes were also seen. No significant collection or altered signal intensity was noted involving the pelvis.

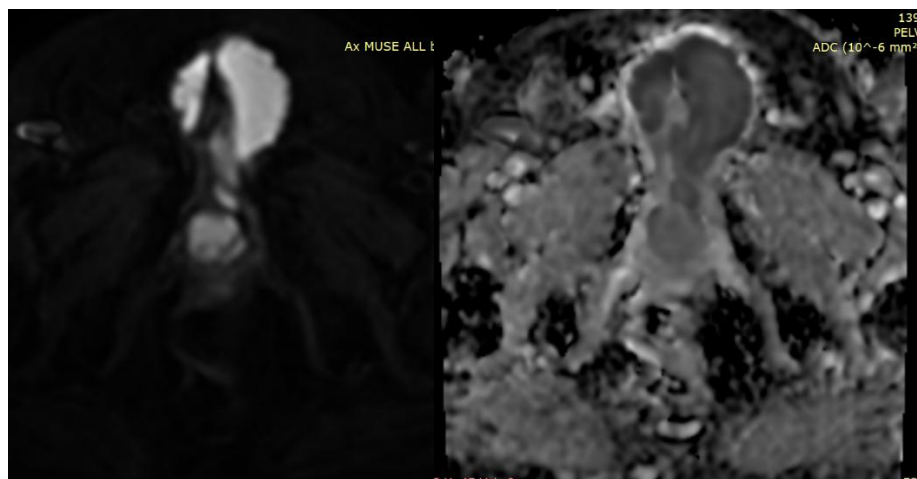
Findings were suggestive of peri-urethral abscess/ collection involving corpora spongiosum.



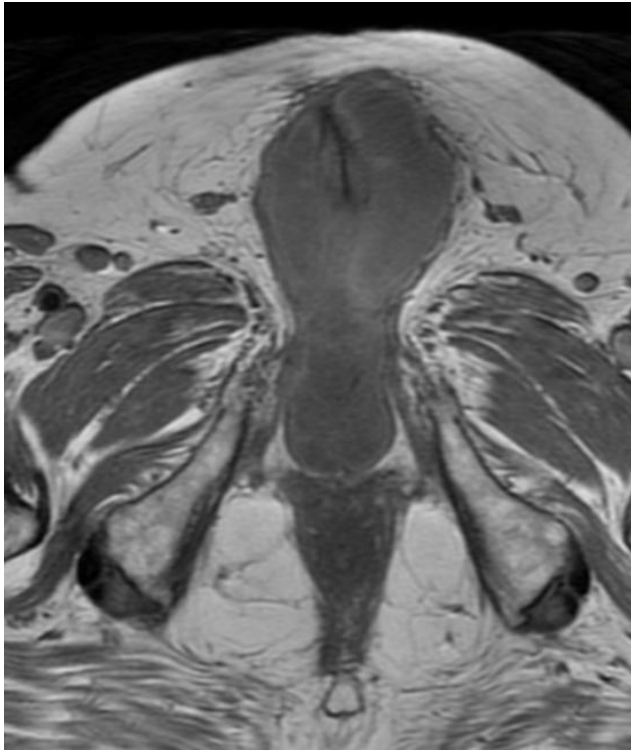Coronal T2W STIR



Axial T2W



Restricted diffusion



Axial T1W

4. Discussion

Periurethral abscesses are relatively uncommon infections that may arise secondary to urethral trauma, stricture disease, instrumentation, or infections of periurethral glands. When the abscess involves the corpus spongiosum, it signifies a deeper and potentially more complicated infection, which can result in severe morbidity if not promptly diagnosed and treated.

This case highlights the pivotal role of MRI in the accurate diagnosis and assessment of periurethral abscesses involving the corpus spongiosum. Compared to other imaging modalities such as ultrasound or computed tomography, MRI offers superior soft tissue contrast resolution, multiplanar imaging capabilities, and the ability to characterize lesion content without ionizing radiation. These features are particularly valuable in the complex anatomy of the perineal region.

In this patient, the abscess demonstrated classic MRI features: T2 hyperintensity reflecting fluid and restricted diffusion on DWI, which is highly sensitive and specific for purulent collections. These findings were essential not only for confirming the diagnosis but also for delineating the abscess extent, particularly its involvement of the corpus spongiosum, which carries important therapeutic implications.

Involvement of the corpus spongiosum suggests a more invasive infection that could predispose to urethral wall damage, fistula formation, or necrosis if left untreated. Early identification of corpus spongiosum involvement enables targeted surgical or percutaneous drainage and appropriate antibiotic therapy, potentially preventing long-term complications such as urethral stricture or erectile dysfunction.

While ultrasound is often the first-line imaging modality for superficial soft tissue infections, it has limitations in evaluating deep periurethral collections and adjacent anatomical structures. CT may provide useful information about the presence of gas or bone involvement but lacks the soft tissue contrast necessary to fully assess the corpus spongiosum and urethral integrity. MRI, therefore, remains the gold standard for detailed assessment of these infections.

This case underscores the necessity of incorporating MRI early in the diagnostic workup when clinical suspicion for periurethral abscess is high, especially in cases with atypical presentations or failed initial management. Furthermore, MRI findings guided clinical decision-making in this patient, enabling minimally invasive drainage and targeted antimicrobial therapy, which led to a favorable outcome.

Limitations of MRI include cost, availability, and the need for patient cooperation. However, the diagnostic benefits often outweigh these concerns, particularly in complex cases.

In conclusion, this case demonstrates that MRI is indispensable in diagnosing periurethral abscesses, providing critical information that influences therapeutic strategy and improves patient prognosis.

References

- [1] Kessler TM, Markwalder R, Hauri D, et al. MRI of the male urethra: anatomy and pathology. *Eur Radiol.* 2004;14(6):1076-1083. doi:10.1007/s00330-003-2178-x
- [2] Lawrentschuk N, Tiong HY, Manoharan M. Periurethral abscess: a rare but important cause of acute scrotum. *Urology.* 2005;65(1):187.e1-3. doi:10.1016/j.urology.2004.08.034
- [3] Oto A, Turkbey B, Kamel IR, et al. MRI of the penis: normal anatomy and evaluation of disease. *Radiographics.* 2007;27(3):831-845. doi:10.1148/rg.273065104
- [4] Sobel JD, Kaye D. Periurethral abscess: clinical presentation, diagnosis, and management. *Urology.* 1987;29(2):161-164. doi:10.1016/0090-4295(87)90073-1
- [5] Semins MJ, Matlaga BR. Periurethral abscess: an unusual complication of urethral stricture disease. *Urology.* 2009;74(1):213-214. doi:10.1016/j.urology.2009.01.002
- [6] Nielsen ME, Maturu P, Pate KA, et al. Utility of MRI in evaluation of periurethral and penile infections and inflammatory conditions. *AJR Am J Roentgenol.* 2013;201(4): W637-W646. doi:10.2214/AJR.12.9825
- [7] Aslam M, Thwaini A, Al-Zahrani M, et al. Periurethral abscess presenting as acute scrotal swelling: a rare urological emergency. *Case Rep Urol.* 2011; 2011:178468. doi:10.1155/2011/178468
- [8] Grossfeld GD, Litwiller SE, Daignault S, et al. Diagnosis and management of periurethral abscesses: case series and literature review. *Urol Int.* 2003;71(2):197-202. doi:10.1159/000069929