International Journal of Science and Research (IJSR)
ISSN: 2319-7064
Impact Factor 2024: 7.101

Homoeopathic Approach in the Treatment of Heloma Durum: A Case Study

Dr. N. Arun[1], Dr. G. Bhuvaneswari[2]

PG Scholar, Department of Homoeopathic Repertory and Case Taking.
White Memorial Homoeo Medical College & Hospital, Attoor, Kanniyakumari District

[2]Associate Professor, PG Guide, Department of homoeopathic repertory and case taking. White Memorial Homoeo Medical College & Hospital, Attoor, Kanniyakumari District

Abstract: ***Heloma Durum or A Corn is a localized form of callosity that develops as a result of repeated friction, pressure, or irritation of the skin, most commonly seen on the soles of the feet and toes. It often presents with hard, thickened skin and is typically accompanied by pain, especially while walking or standing for prolonged periods. In this case, a 56 - year - old female presented with a painful corn on the right sole of her foot, which significantly affected her daily activities. A detailed case - taking was conducted to understand her physical, mental, and emotional state, along with her lifestyle and medical history. Repertorization was carried out using the Complete Repertory, focusing on characteristic symptoms related to her complaint. Based on the totality of symptoms, Antimonium crudum was selected as the individualized homeopathic remedy. This case highlights the importance of individualized treatment in homeopathy, where the remedy is tailored to the patient's overall constitution, resulting in effective and holistic healing.***

Keywords: Homoeopathy, Heloma Durum, Corns, complete Repertory, Antimonium crudum

1. Introduction

Heloma durum, commonly known as a corn (clavus), refers to an acquired area of thickened skin (keratosis) that develops in response to repeated or prolonged trauma to the epithelium. These lesions form due to pressure, friction, and shearing forces exerted by underlying bony structures against adjacent toes, metatarsal heads, or footwear. [9] Corns refers to a localized thickening of the skin, commonly seen in pressure - bearing areas like the soles and toes. The condition presents as a horny, hardened area of the outer skin with a dense central core. Corns may cause pain, particularly when exposed to friction or pressure. Even after surgical removal, they tend to recur.

The central core of a corns extends deeply into the lower layers of the dermis. [1] Friction causes the epidermis to separate and grow excessively, leading to an abnormal thickening of the skin. [2] It most commonly appears on the tops and sides of the toes and is classified into two types: hard and soft corns. Hard corns have a thickened outer layer with a dense central core, while soft corns have a thinner, more pliable surface. [3] In the case of corns, external mechanical stress is concentrated on a specific area of the skin, causing the stratum corneum to compact and form a hard keratin plug. This plug, known as a radix or nucleus, presses into the papillary, dermis, often resulting in pain. [4]

The occurrence of corns on the feet has been reported to range between 14% and 48%. [5] Individuals with darker skin tones are more likely to develop corns. These lesions are more commonly seen in older adults, with a slight predominance in females, often attributed to the use of narrow footwear. [6] Corns commonly develop due to repeated mechanical trauma, compounded by factors such as poorly fitting footwear, bony prominences associated with foot deformities, and specific physical activities. [7] Continuous friction and pressure on the skin covering bony prominences lead to the development of hyperkeratotic thickening, resulting in corn formation. This is a protective response by the body, where excess keratin is produced in the outer epithelial layer to guard against skin ulceration. This mechanism accounts for the common appearance of corns near the condyles of the metatarsals and phalanges, as well as their prevalence in individuals with foot deformities. [8]

2. Case Study

Mrs. XY, 56 year, Female, slightly fatty, short with fair complexion, Hindu, married, Vegetarian, working as teacher, attended the out - patient department of the white memorial homoeo medical college, Kanyakumari (tamilnadu). presenting herself with the known case of corn on 06/11/2024, on further enquiry she said that complaint had started since 6 months. Her complaints started gradually 2 months after death of her husband. Complaining of pain and burning in sole of right foot. Pain aggravated during walking. she took alternative medicines orally and as an external application applies many ointments on corn but no relief. Regarding her past history the patient never had any major illness. Her father died 20 years ago and mother still alive. Her husband is dead due to heart attack. The mental general reflected with she is sad, weeps of thing about her husband. Physical generals:
Appetite: Good.
Hunger: Increased.
Desire: sour food.
Aversion: Bread.
Perspiration: scanty in armpit. Urine: Normal.
Stool: Normal.
Sleep: sound sleep. Dreams: of daily routine. Thirst: 2 - 3 lit/day.
Thermal state: Can't tolerate extremes of heat and cold.

2.1. Totality of symptoms

1) Sadness
2) Weeps
3) Desire for sour food

4) Aversion to bread
5) Corns on soles
6) Corns painful, especially on walking.
7) Corns burning

2.2. Rubrics

1) [Complete] [Mind]Sadness:
2) [Complete] [Mind]Weeping, tearful mood:
3) [Complete] [Stomach]Sour, acid food agg.:
4) [Complete] [Stomach]Bread: Agg.:
5) [Complete] [Extremities]Corns:
6) [Complete] [Extremities]Corns: Painful: Walking, while:
7) [Complete] [Extremities]Corns: Burning, smarting:

2.3. Repertorial Sheet [10]

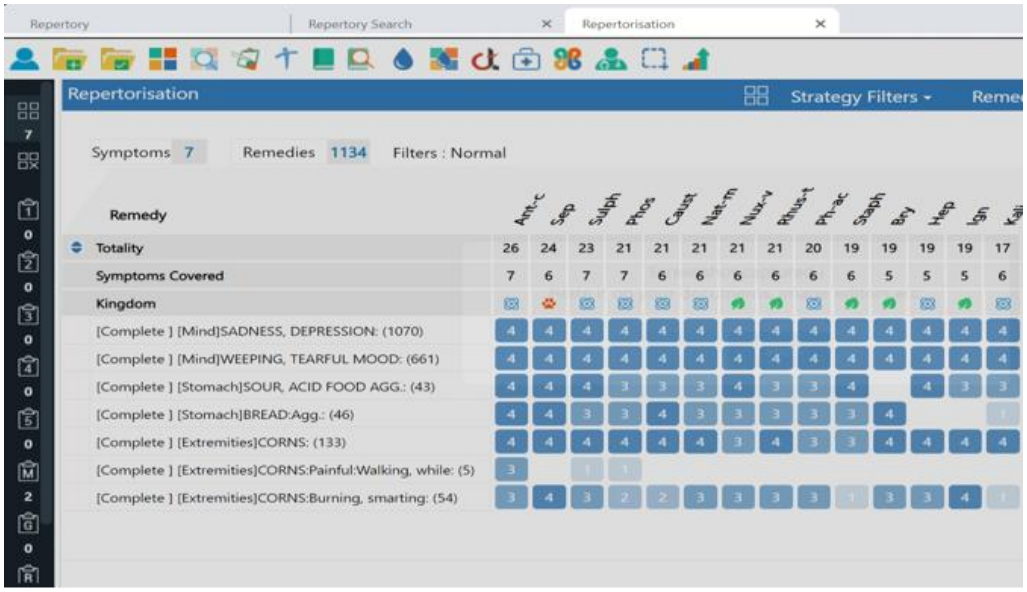

Figure 1: Showing repertorization of case from Complete Repertory

2.4. Analysis of Repertorial Result

Table 1: Repertorial Result

S. No.	Medicine	Mark Obtain
1.	Antimonium crudum	26/7
2.	Sepia Officinalis	24/6
3.	Sulphur	23/7
4.	Phosphorus	21/7
5.	Causticum	21/6

2.5. Selection of medicine

Antimonium crudum seems to suit the case not only because it gets highest marks during repertorization but also cover most of the symptoms of the case. Patient has marked mental symptoms like sadness, weeping and Classic for corns**,** sad mood**,** desire sour**,** bread aversion.

2.6. Prescription

Table 2: Prescription

Date	Prescription
06/11/2024	Rx Antimonium crudum 200/1 Dose Stat S. L.4 Globules B. D. for 15days.

2.7. Follow- up Sheet

Table 3: Followup Sheet

Date	Symptoms	Prescription
20/11/2024	Pain and inflammation reduced 60%	SL 4 x BD 15 days.
4/12/2024	The pain and inflammation reduces 60%	Antimonium Crudum 200/1 Dose Stat. S L - 4 B. D. for 15 days.
19/12/2024	The pain and inflammation reduces 80%.	S L–4 B. D. For 15 days.
04/1/2025	Corns is completely get cured	S L–4 B. D. For 15 days.

2.8. Picture

2.8.1. Before Treatment

Figure 2: Before Treatment

2.8.2. After Treatment

Figure 3: After Treatment

3. Conclusion

Homeopathy has consistently demonstrated its remarkable ability to improve the quality of life for individuals suffering from corns, or heloma durum. Unlike conventional treatments that often rely on temporary measures such as surgical removal or topical applications, homeopathy addresses the root cause of the condition, offering a holistic and long - lasting solution. The effectiveness of homeopathic remedies in managing corns is well - documented through numerous clinical experiences and case studies. These remedies not only alleviate pain and discomfort but also help prevent recurrence by considering the individual's constitution, lifestyle, and emotional well - being. This case report further supports the therapeutic value of homeopathy, showcasing its powerful healing potential in restoring skin health and promoting natural recovery. The gentle, non - invasive nature of homeopathic treatment makes it particularly appealing for chronic conditions like corns, where repeated trauma and underlying systemic factors are involved.

Overall, homeopathy offers a safe, effective, and individualized approach to managing and curing corns.

References

[1] Das, S. (2010). A Concise Textbook of Surgery (6th ed.). Kolkata: Dr. S. Das Publishers. p.151.
[2] InformedHealth. org. Cologne, Germany: Institute for Quality and Efficiency in Health Care (IQWiG) 2006. Corns: Overview 2019, 11.
[3] Gardner SS, Corns and calluses. WebMD.2019, 26.
[4] Gawali C. Role Of Homoeopathic Medicine in the case of corn, The Case Report. Mater Novum J Homoeopathy.2018; 2: 41 - .
[5] Farndon L, Barnes A, Littlewood K, Harle J, Beecroft C, Burnside J, Wheeler T, Morris S, Walters SJ. Clinical audit of core podiatry treatment in the NHS. J Foot Ankle Res.2009 Mar 13; 2: 7.
[6] Elwell R. The management and treatment of hyperkeratosis. Br J Nurs.2017 Apr 27; 26 (8): 468 - 470.
[7] Singh D, Bentley G, Trevino SG. Callosities, corns, and calluses. BMJ.1996 Jun 01; 312 (7043): 1403 - 6.
[8] Bonavilla EJ. Histopathology of the heloma durum: some significant features and their implications. J Am Podiatry Assoc.1968 Oct; 58 (10): 423 - 7.
[9] Arndt KA, Hsu JT. Manual of Dermatologic Therapeutics.7th ed. Philadelphia; Lippincott Williams and Wilkins; 2007. p.47.
[10] Scholten, J. (Ed.). (2020). Complete Repertory 2020 [Software]. Retrieved from Hompath WildFire, Mind Technologies Pvt. Ltd.
[11] Farrington EA, MD. Comparative Materia Medica 1986, Pub.: B. Jain Publishers Pvt. Ltd., New Delhi - 110 055.
[12] Clark JH. A Dictionary of Practical Materia Medica. Delhi. B Jain. Publications 1, 2, 3, 2003.
[13] Dr. Samuel Hahnemann (B. K. Sarkar): Organon of Medicine, 5th& 6th Edition, 1984, 8th Indian Edition, Pub.: M. Bhattacharya & Co. (p) Ltd., Calcutta - 1.