

A Case Series on Amniotic Band Syndrome Presenting as Congenital Anomaly

Dr Bismayee Sahoo¹, Dr Santosh Kumar Behera²

¹PG Resident, Department of OBS and Gynae, HI- Tech Medical College and Hospital, BBSR

²Professor, HOD, Department of OBS and Gynae HI- Tech Medical College and Hospital, BBSR

Abstract: Introduction: Amniotic band sequence (ABS) is a constellation of complex fetal morphological abnormalities associated with intrauterine amniotic bands. 1 It is a rare disorder and with varied degrees of abnormalities. 2 The clinical aspects of the limbs are varied with presence of cutaneous grooves of amputation, pseudo-syndactyly and club feet. 3 The incidence varies from 1 in 1,200 to 1 in 15,000 live births. 4 Both sexes are equally impacted. 5 Anomalies can range in severity from simple craniofacial clefts that are ultimately life-incompatible to single-digit amputations. Materials and Methods: Case Series: Our case series depicts four deliveries at HI Tech Medical College and Hospital, BBSR. Each of our patient case demonstrates the spectrum of ABS and supports the extrinsic theory as the primary mechanism. Results: The first case resulting in lateral encephalocele with a complex facial cleft and subsequent intrauterine fetal demise. The second patient case resulting in fetal unilateral lower extremity limb reduction. The third patient case resulting in premature prelabor rupture of membranes and delivery at 29 weeks with pedal amputation. The fourth and final patient case resulted in a lethal limb-body-wall defect with extravasation of visceral organs and a sacral myelomeningocele. Conclusion: All four of our cases lend support to the extrinsic theory as the primary pathological mechanism. Each of our patients had risk factors for potential hypoxic injury and subsequent amniotic band formation.

Keywords: Amniotic band sequence, fetal abnormalities, limb deformities, congenital disorder, pregnancy complications

1. Introduction

Amniotic band sequence (ABS) is a constellation of complex congenital anomalies that can be seen in infants without any known genetic mutations. It is said to be responsible for 1/70 stillbirths [1] and its estimated prevalence varies widely from 1/1200 to 1/15000 live births [2]. It affects both sexes equally. The extent of anomalies can range from single digit amputations to complex craniofacial clefts that are ultimately incompatible with life [3]. There are two leading theories for the proposed pathogenesis of ABS, commonly referred to as the “extrinsic” and “intrinsic” models. The first proposed theory is the Intrinsic theory, described by Streeter in 1930 [4], which suggested that the anomalies were caused by an intrinsic defect in the embryo during early development and partial perturbation of the germ disc. This process can lead to early development of amniotic bands.

The extrinsic model as described by Torpin in 1965 [5] suggested that birth defects are caused by a disruption in the amnion-chorion interface, leading to the formation of multiple loose bands. These bands are comprised of extraembryonic celom between the amnion in the chorion. The bands then adhere to and entangle the embryo leading to constriction rings that result in vascular compromise leading to hypoxic tissue damage [6]. The following four cases presented support the extrinsic theory as the likely mechanism.

2. Case Report

Case 1

A 19-year-old gravida 1 para 0 diagnosed and treated for positive chlamydia at her new obstetric visit at 9w6d but had an otherwise uncomplicated medical and surgical history. The patient's family history was negative for any congenital

anomalies, paternal consanguinity, and previous uterine procedures.

A routine fetal ultrasound assessment performed at 19 weeks' gestation revealed right lateral encephalocele (Figure 1), large right cleft lip and palate with the defect expanding to the right eye socket, left lower extremity edema, and bilateral rocker-bottom feet (Figure 2, Figure 3, Figure 4). Repeat ultrasound at 23 weeks gestation showed previous anomalies with appearance of a thick right lateral amniotic band spanning the full length of the skull and facial defects as well as bilateral clenched fists (Figure 5). She underwent extensive consultation in regard to ABS and outcomes, with plans for close follow-up. She presented at 26 weeks gestation for her scheduled growth scan reporting decreased fetal movement. She was diagnosed with intrauterine fetal demise measuring in the 9th percentile with an estimated fetal weight of 768 grams. She was admitted for induction of labor and went on to have an uncomplicated vaginal delivery. After delivery, fetal examination revealed profound midfacial deformities, brachydactyly, and placental adhesions. Placental pathology significant for a 20.7 cm long three vessel, peripherally inserted, umbilical cord with amnion constriction near placental insertion. Fetal membranes displayed features of amnion/chorion disruption as well as thickened bands of chorionic connective tissue and extraembryonic celom between the amnion and the chorion.

Case 2

A 21-year-old gravida 2 para 1 with uncomplicated pregnancy presented for anatomical survey at 19 weeks 2 days based on last menstrual period. The patient had no family history of congenital defects, uterine procedures, or paternal consanguinity. The patient's anatomy scan was significant for a swollen right foot wrapped by thin “wispy” amniotic bands other fetal anomalies were noted on the ultrasound. The patient continued to have an otherwise uncomplicated

pregnancy until premature prelabor rupture of membranes at 23 weeks 1 day. She was expectantly managed inpatient until 29 weeks at which time she had a primary low transverse cesarean section for breech presentation in the setting of chorioamnionitis. Pathology evaluation of the placenta revealed acute funisitis and acute chorioamnionitis. Further evaluation of the amputated left foot revealed extensively autolyzed skin, soft tissue, bone, and cartilage. Neonatal exam revealed a left lower extremity below the knee limb reduction defect as well as evidence of amniotic banding to various digits on both hands. Infant was discharged home at a corrected gestational age of 35 weeks and three days at 2215 grams with pediatric orthopedics follow-up.

Case 3

A 34-year-old gravida 1 para 0 with uncomplicated pregnancy presented for routine anatomical survey at 21 weeks 5 days based on last menstrual period. This patient also had no history of uterine procedures, familial birth defects, or paternal consanguinity.

The patient's anatomy scan was significant for complete absence of the left foot and ankle, without any identifiable amniotic band, however with slight swelling and shortening of the tibia and fibula. The patient had serial ultrasounds throughout her pregnancy, which progressed to term without complication. The patient ultimately delivered via primary cesarean for suspected fetal macrosomia. Her surgical operative report was significant for macrosomic infant as well as an arcuate shaped uterus. Radiology imaging at newborn visit is significant for absent left foot as well as an absent left distal tibia and fibula.

Case 4

The fourth and final patient case was noted in a 21-year-old G3P1L1 during a routine anomaly scan at 21 weeks 4 days. The patient had an antepartum course complicated by anemia with otherwise uncomplicated history. The fetal anomaly scan was significant for a complex limb body wall defect. Specific defects included ectopia cordia, open abdominal wall defect with bowel stomach, and liver extraperitoneally. Spinal anatomy was significant for type 1 sacrococcygeal teratoma and myelomeningocele with associated dandy walker malformation. The patient underwent an emergency cesarean section for placental abruption at 31 weeks. The infant received comfort care and ultimately succumbed to multiple anomalies shortly after delivery.

3. Discussion

Amniotic band sequence (ABS) deformities are likely caused by early rupture of the amnion leading to the formation of mesodermic strands. These strands form both tight

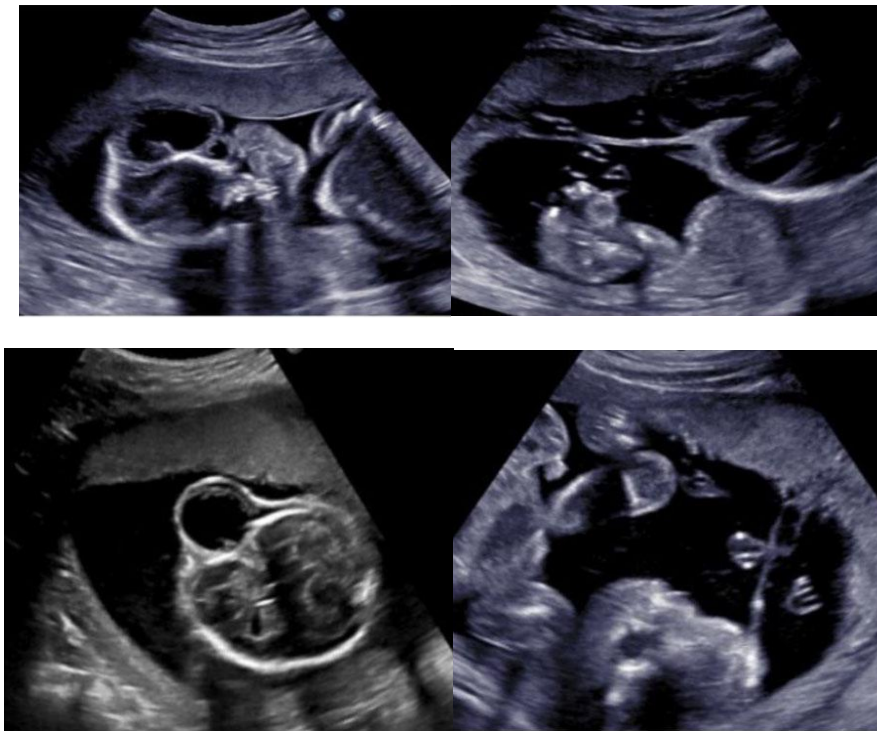
constrictive tissue bands as well as wispy amniotic adhesions. Initially the bands adhere and entangle loosely to the fetus, however over time the bands become constrictive rings and lead to an acute and later chronic hypoxic state. The presence of hypoxia and the constrictive bands result in complex anomaly patterns leading to an array of fetal malformations [5],[7]. Clinical manifestations can range from minor digit amputations to fatal complex anomalies. There are numerous risk factors that predispose a pregnancy to the development of ABS.

These risk factors include obesity, nulliparity, nicotine usage, history of uterine procedures, intrauterine infections, Mullerian anomalies, residing in high altitudes and pre-existing maternal diabetes [3].

The cases presented in this case series all exhibit some of the risk factors stated above. Each case demonstrates the wide spectrum of severity seen in patients affected by amniotic band sequence.

Case 1 had a known diagnosis of chlamydial infection in early pregnancy. Chlamydial infections are known to lead to the formation of intrauterine and extrauterine adhesive disease as well as early rupture of membranes. This likely accounts for the early rupture of the amnion and formation of the amniotic bands. In case 2 the findings of amniotic band syndrome were seen during her fetal anomaly scan with unclear etiology; however, she ruptured less than two weeks later and was subsequently diagnosed with an intra-amniotic infection.

Finally, the patient in case 3 was noted to have an arcuate shaped uterus intraoperatively. The presence of an arcuate uterus as well as other uterine Mullerian anomalies increases the risk for earlier rupture of membranes, abnormal placentation, and placental mal-perfusion [8]. In addition, all these patients were nulliparous, differences in vascularity in nulliparous women versus multiparous women have been noted. The mechanism through which amniotic band sequence occurs is related to the level of vascular compromise seen in the tissues affected. The early separation of the amnion from the chorionic membrane creates remnants of fibrous bands that constrict the fetus's ability to grow. The constrictive bands can be superficial resulting in skin indentations or can be deep leading to severe vascular compromise. The severity of vascular compromise can result in simple digit amputation or complex fetal anomalies such as encephaloceles and large facial clefts [10]. In the four cases presented above the complexity of fetal injury was directly related to the level of vascular injury with case 1 and case 4 having the most severe vascular insults. Currently there are few options for treatment, however, some literature cites the potential for intrauterine lysis of adhesions via fetoscopic surgery



4. Conclusion

Further investigations are needed to understand the formation of amniotic bands and for the potential for intrauterine treatments. For now serial ultrasound examination, artery Doppler assessment of affected fetal parts, and mode and place of delivery should be based on obstetrical indications as well as severity of the fetal abnormalities.

References

- [1] Kalousek DK, Bamforth S. Amnion rupture sequence in previable fetuses. *Am J Med Genet* 1988;31(1):63–73. [CrossRef] [PubMed]
- [2] Hunter AGW, Seaver LH, Stevenson RE. Limb-body wall defect. Is there a defensible hypothesis and can it explain all the associated anomalies? *Am J Med Genet A* 2011;155A (9):2045–59. [CrossRef] [PubMed]
- [3] Ossipoff V, Hall BD. Etiologic factors in the amniotic band syndrome: A study of 24 patients. *Birth Defects Orig Artic Ser* 1977;13(13D):117–32. [PubMed]
- [4] Streeter GI. Focal deficiencies in fetal tissues and their relation to intrauterine amputations. *Contrib Embryol Carnegie Inst* 1930; 22:1–44.
- [5] Torpin R. Amniochorionic mesoblastic fibrous strings and amniotic bands: Associated coconstricting fetal malformations or fetal death. *Am J Obstet Gynecol* 1965; 91:65–75. [CrossRef] [PubMed]
- [6] Merrimen JLO, McNeely PD, Bendor-Samuel RL, Schmidt MH, Fraser RB. Congenital placental–cerebral adhesion: An unusual case of amniotic band sequence. Case report. *J Neurosurg* 2006;104(5 Suppl):352–5. [CrossRef] [PubMed]
- [7] Kahramaner Z, Cosar H, Turkoglu E, et al. Amniotic band sequence: An extreme case. *Congenit Anom (Kyoto)* 2012;52(1):59–61. [CrossRef] [PubMed]
- [8] Cignini P, Giorlandino C, Padula F, Dugo N, Cafà EV, Spata A. Epidemiology and risk factors of amniotic band syndrome, or ADAM sequence. *J Prenat Med* 2012;6(4):59–63. [PubMed]
- [9] Garite TJ, Freeman RK. Chorioamnionitis in the preterm gestation. *Obstet Gynecol* 1982;59(5):539–45. [PubMed]
- [10] Lekovich J, Stewart J, Anderson S, Niemasik E, Pereira N, Chasen S. Placental malperfusion as a possible mechanism of preterm birth in patients with Müllerian anomalies. *J Perinat Med* 2017;45(1):45–9. [CrossRef] [PubMed]