

# The Role of Interval Appendicectomy in Follow Up Cases of Appendicular Mass and Abscess in a Tertiary Care Centre in Odisha

Dr. Durga Prasad Sahu<sup>1</sup>, Dr. Pravat Kumar Majumdaar<sup>2</sup>

<sup>1</sup>Post Graduate Resident Department of General Surgery, Hi-Tech Medical College and Hospital, Bhubaneswar, India  
Corresponding Author Email: [sahu.durga1920\[at\]gmail.com](mailto:sahu.durga1920[at]gmail.com)

<sup>2</sup>Assistant Professor, Department of Surgery, Hi-Tech Medical College and Hospital, Bhubaneswar, India

**Abstract:** ***Background:** An appendicular mass is one of the most common complications seen in patients presenting a few days later after the onset of acute appendicitis. The ideal treatment of acute appendicitis is considered to be appendectomy failing which a number of complications, including an appendicular mass, usually result. Traditionally acute appendicitis was principally diagnosed on repeated physical examinations after active observation, without much reliance on laboratory investigations. Greater reliance on putatively objective tools for the diagnosis can delay the diagnosis and has changed the outlook for some patients. Delayed diagnosis changes the uncomplicated simple acute appendicitis into complicated appendicitis. Reluctance for surgery is common in the world where most of the population lives below the poverty line and a single member may generate the income for the whole family. For this reason, time off work can be difficult for some. Another important factor is a general fear of surgery amongst much of the population. Additional factors that contribute to the development of an appendicular mass include lack of health facilities in remote under resourced areas. In some rural areas general practitioners often keep the patient on symptomatic therapy rather than referring to a higher-level hospital. **Aim of the study:** 1) The purpose of this dissertation is to analyse the follow up cases of treated cases of appendicular mass and abscess and ascertaining the role of interval appendicectomy. 2) To analyse and compare the clinical response of appendicular mass and abscess treated conservatively and surgically. 3) To assess the role of interval appendicectomy and its benefit during the follow up of these cases. **Results:** Interval appendicectomy is considered to be beneficial in a conservatively treated case of complicated appendicitis because of less recurrence, Low conversion rate, less complication rate and less hospital stay.*

**Keywords:** Appendicular mass management, interval appendectomy, complicated appendicitis care, conservative versus surgical treatment, recurrence prevention.

## 1. Introduction

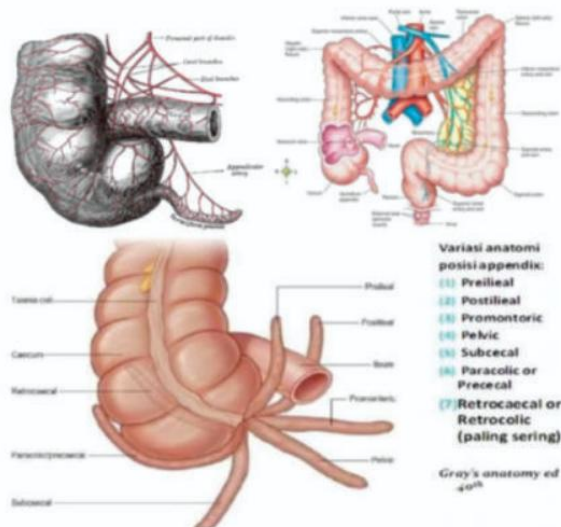
Acute appendicitis is one of the most frequent acute surgical pathologies. The inflammation in acute appendicitis may sometimes be fixed by the patient's own defense mechanisms, by the formation of an inflammatory mass or a circumscribed abscess, often presenting as a palpable mass days following the onset of symptoms. Appendicular mass occurs in 2 to 7% of all cases of appendicitis with higher risk in children and the elderly whose diagnosis or therapy of acute appendicitis are missed or delayed. The mass usually forms in the right iliac fossa after 48-72 hours after the first symptoms of acute appendicitis. The mass develops when appendicitis is caused by obstruction of the lumen and there is an ensuing danger of perforation of the appendix following ischemic necrosis and gangrene of the appendicular wall.

As a natural protective mechanism, the omentum and small bowel wrap up the inflamed appendix in an attempt to prevent infection from spreading by isolating the inflamed organ from rest of the abdominal cavity. There may have been an evolutionary advantage that selected this kind of defensive mechanism. The patient usually presents with a tender mass in the right iliac fossa associated with fever, malaise and anorexia. This walling off mechanism may fail and generalized peritonitis may ensue. This is more often seen when there is obstruction of the appendicular lumen by a faecolith, an immunocompromised patient, the extremes of age, Diabetes Mellitus and when the inflamed appendix is

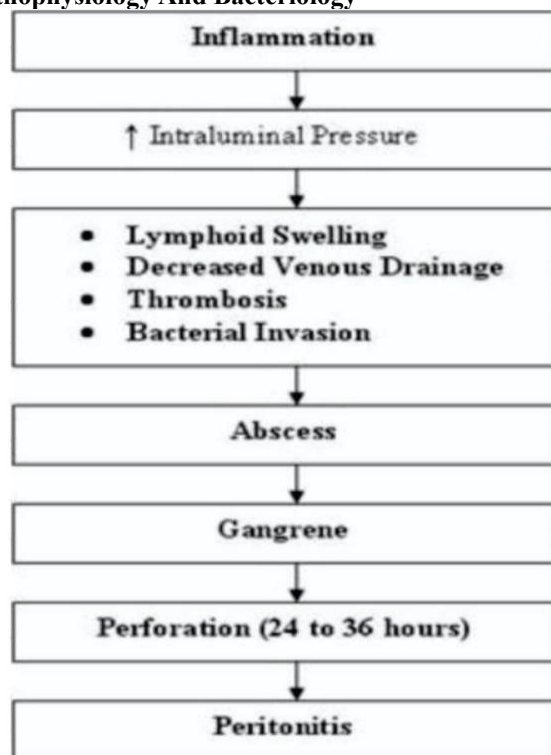
lying freely in the pelvis beyond the ability of the omentum to wrap the inflamed organ.

## Anatomy And Embryology

The appendix, a midgut organ, is first recognised as a little pouching of the cecum at 8 weeks of pregnancy. The appendix lengthens and becomes more tubular as the pregnancy progresses as the cecum rotates medially and establishes itself in the right lower quadrant of the abdomen. The appendiceal mucosa has a colonic look due to the columnar epithelium, neuroendocrine cells, and mucin-producing goblet cells that line the tubular structure. The superior mesenteric artery supplies the appendix's blood supply as a midgut organ. The appendiceal artery, which runs through the mesoappendix, originates from the ileocolic artery, one of the major named branches of the superior mesenteric artery. Additionally, the mesoappendix houses the appendix's lymphatics, which travel with the superior mesenteric artery's blood supply to the ileocecal nodes. The appendix can range in length from 5 to 35 cm, however adults typically have an appendix that is 9 cm long.



### Pathophysiology And Bacteriology



Appendicitis-related infections should be regarded as polymicrobial, and treatment with antibiotics should include medications that address both the presence of gram-negative bacteria and anaerobes. *Escherichia coli*, *Bacteroides fragilis*, enterococci, *Pseudomonas aeruginosa*, and others are common isolates. The luminal blockage has a wide range of reasons. Fecal stasis and fecoliths are among the most frequent of these, although other possible causes include lymphoid hyperplasia, neoplasms, fruit and vegetable matter, swallowed barium, and parasites such as *ascaris*.

### Pathogenesis Of the Appendicular Mass

The appendicular mass, which can range in size from a phlegmon to an abscess, typically appears as a sore lump in the right iliac fossa after an acute appendicitis attack (Brown CV et al 2003). Since the omentum and small bowel coils in the area of the appendix naturally wall off the inflamed

appendix, it typically manifests in individuals who present later in the course of acute appendicitis. This mass initially consists of a muddled combination of inflamed appendix these organs and granulation tissue (Brian W.Ellis and Simon –Paterson- Brown 2000). A clinically palpable painful mass appears in the right iliac fossa within 48 hours if the barriers are effective and the inflamed appendix does not perforate. An appendicular abscess may form if the defences are unable to contain the inflammation or the appendix ruptures.

### Physical Examination

#### Clinical Presentation Symptoms

- Peri umbilical pain
- Pain shift to right iliac fossa
- Anorexia
- Nausea and vomiting

#### Murphys Triad

- Pain
- Vomiting
- Temperature
- SIGNS OF APPENDICITIS
- Pyrexia
- Localized tenderness in right iliac fossa
- Muscle guarding
- Rebound tenderness

#### Signs to Elicit Appendicitis

#### COPES PSOAS TEST

Right thigh pain on extension: –retroperitoneal retrocaecal appendix.

#### OBTURATOR TEST

Right thigh pain on internal rotation: pelvic appendix.

#### ROVSING SIGN

Pain in the right iliac fossa on pressing the left iliac fossa, due to shifting of intestinal loops causing irritation of the parietal peritoneum.

#### DUNPHYS SIGN

Increased right iliac fossa pain on coughing.

#### AARON SIGN

A sensation of epigastric pain and distress on pressure over Mcburney s point.

#### BLUMBERG SIGN

Release sign, due to the presence of an inflamed organ underneath it.

#### ALDER'S SIGN (DIAGNOSE APPENDICITIS IN PREGNANCY)

First mark the most tender point, then on turning the patient to left side, tenderness of uterine origin will shift, while appendix pain remains in the same point.

#### Differential Diagnosis

Gastro-intestinal Cholecystitis Diverticulitis Meckel s diverticulitis Enteritis. Duodenal ulcer Intussusception Mesenteric lymphadenitis. Necrotizing entero colitis Torsion

of the Omentum Acute Pancreatitis Perforated bowel volvulus Neoplasm (carcinoid, carcinoma, lymphoma GYNECOLOGICAL Ectopic pregnancy Endometriosis Ovarian torsion inflammatory disease ovarian cyst is ruptured Tubo ovarian abscess.

### Systemic Cause

Diabetic keto acidosis Porphyria Sick cell anaemia Pleurisy. GENITO - URINARY Kidneys to ne Prostatitis and Pyelonephritis Urinary tract infection Parasitic infestation. Psoas abscess Hematoma Testicular torsion.

### Investigations

#### Lab Investigations

Total count markedly increased around 10,000/ mm<sup>3</sup> (range from 8000 to 14000/mm<sup>3</sup>). Increase in count of neutrophils (Shift to left) CRP- Elevated implies inflammation. Urine analysis to rule out genito urinary cause.

### Radiographic Studies

#### Plain X-ray Flim

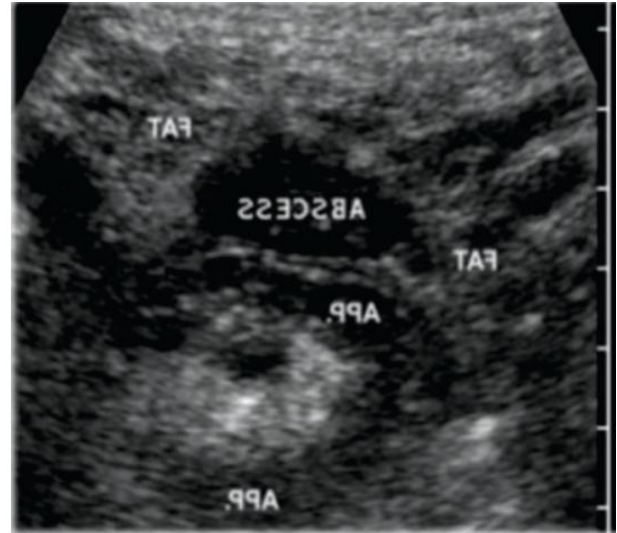
- To find the cause of abdominal pain
- Sentinel loop – A fluid level in ileum with dilated atonic ileum
- Caecum is dilated and Appendix calculus about 0.5 – 6 cm
- Right lower quadrant haze due to fluid and the edema
- Scoliosis present and concave to right
- Widening of the pre peritoneal fat
- Right lower quadrant mass indenting the caecum
- Right psoas outline is blurring
- Gas in the appendix

### Ultrasound

Ultrasonography offers a sensitivity of about 85% and a specificity of more than 90% for the diagnosis of acute appendicitis in individuals with abdominal pain. Ultrasound Findings

- Blind –ending tubular structure at the point of tenderness
- Non-compressible
- Diameter 7mm or greater
- No peristalsis
- Appendicolith casting acoustic shadow
- High echogenicity non-compressible surrounding fat
- Surrounding fluid or abscess

- Oedema of caecal pole A sensitivity of around 90% has been claimed. It should be remembered that there are pitfalls in the ultrasound diagnosis of appendicitis. Scenarios leading to false-negative examinations include appendicitis of the appendiceal tip, retrocaecal appendicitis, gangrenous or perforated appendicitis, organs filled appendix.



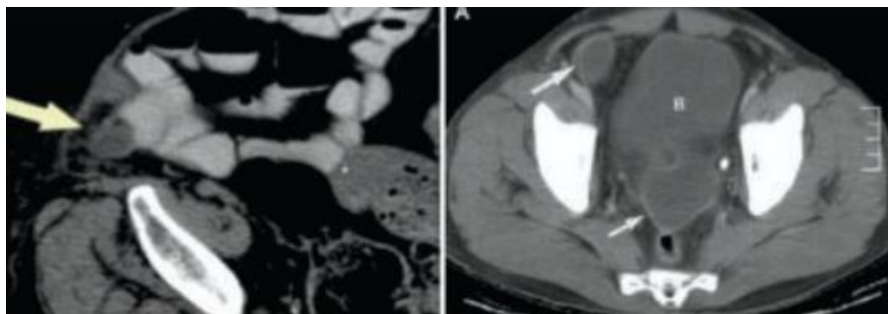
### Computed Tomography (C.T)

IN APPENDICITIS The spiral CT is more accurate than axial CT scan. Scanning with oral and I.V contrast is more accurate than non-contrast CT scan.

### C.T Findings in Appendicitis

- Appendicolith is present
- Diameter of appendix is more than 6mm
- The oral contrast or air fails to fill the appendix
- The wall of the appendix is enhanced with IV contrast
- Fluid, appendicular mass, thick caecum, attenuation of fat, gas in the extra luminal space, lymph nodes enlarged.


**Sign:** Caecal lumen pointing towards the opening to the appendix which is obstructed 100% Specificity and sensitivity.



### Diagnostic Laparoscopy

It is useful in equivocal cases. Avoid unwanted appendectomy Useful in young females along with gynaecological conditions.

**ALVARADO SCORE:** A number of clinical and laboratory-based scoring systems have been devised to assist diagnosis. The most widely used is the Alvarado score.



## Medical Management

### Ochsner Sherren Regime

Historically, it was thought that appendicular mass surgery was risky and would result in life-threatening complications due to edema and the brittleness of the structures.

The essential components include

- Patient position to improve gravitational flow of exudates towards pelvis
- Nil per oral for first 48hrs
- Intravenous fluids
- Intravenous antibiotics
- Measurement of size of mass If patient improves, then orals started and advised for interval appendicectomy after 6 weeks If treatment fails, surgery is done

The treatment for appendicitis is appendicectomy Proper preoperative work up should done:

- 1) Intravenous fluid should begin.
- 2) Monitoring of urine output, blood pressure, pulse. Electrolyte abnormalities should be corrected.
- 3) Antibiotics should be given before 30 minutes of induction of anesthesia. Antibiotic should cover both gram-negative bacteria and anaerobes.
- 4) There should not be any delay in surgery to minimize the chances of perforation.

Several studies have been conducted around the world; some have supported and favoured laparoscopy and some others are not. Most cases of acute appendicitis can be treated by laparoscopy. Laparoscopic appendicectomy is equally safe and less postoperative pain and morbidity as compared to open appendicectomy. Laparoscopic appendicectomy is a useful procedure for reducing the hospital stay, return to work early, less complications encountered. Laparoscopic procedures decrease the loss of earning days by an early return to work and shorter hospital stay. Hence, it's useful in India where most of them are daily wages workers.

## 2. Discussion

The most frequent cause of severe abdominal pain is acute appendicitis, which can be either complicated or uncomplicated.

- An inflammatory phlegmon or a confined abscess may occasionally occur around an appendix inflammation. It is debatable how these patients should be treated. These individuals either receive conservative or surgical treatment.
- This study seeks to evaluate the effect of interval appendicectomy and its requirement by monitoring individuals who have been diagnosed with appendicular mass or appendicular abscess and treated surgically or conservatively (drainage).
- All patients diagnosed with appendicular abscess or mass who are admitted to surgical wards are included in the study.
- Patients in this group are managed conservatively or through surgical drainage without undergoing appendicectomy.
- In this study, about 50 patients with complicated appendicitis were recommended for conservative treatment or surgical drainage. For around three months, these individuals were monitored. Some of the patients got interval appendicectomy during the procedure, while others underwent conservative line of treatment.
- Out of the 50 patients included in the study, 29 patients were male and 21 patients were female. Most of the patients admitted in the hospital diagnosed with appendicitis belonged to the age group 20 – 30 (approximately 54%), followed by 30-40yrs (28%) and then above 40yrs and below 20 yrs. Of the 50 patients admitted, 28 patients were clinically or radiologically diagnosed as having an appendicular mass, and approximately 22 patients had this diagnosis. All patients with appendicular abscesses had surgical drainage, and they were all monitored for three months.

The distribution of procedures among the approximately 42 patients who underwent interval appendicectomy is as follows. The remaining 8 patients remained with a conservative course of treatment.

- 1) Laparoscopic – 33 patients
- 2) Open – 2 patients
- 3) Lap converted to open – 7 patients
- 4) When compared to patients with acute appendicitis, the conversion rate from laparoscopic appendicectomy to open technique was a little higher. The length of the hospital stay ranged from three to seven days.
- 5) According to the length of their stay, the patients are distributed as follows.
  - a) 7 days - 3
  - b) 6 days - 6
  - c) 5 days - 16
  - d) 4 days - 7
  - e) 3 days – 8

Six interval appendicectomy patients—out of the 4 cases—experienced postoperative problems such fever, wound infection, and wound gaping. Additionally, 5 patients were discovered to have normal histological reports showing complete remission of infection, proving the effectiveness of



cautious antibiotic treatment. The complication incidence was slightly greater than in conventional appendectomy cases. No recurrence was documented in any of the eight subjects that did not receive interval appendectomy. Considering all of these data, interval appendectomy may not be necessary in a severe appendicitis case that is managed conservatively.

### 3. Conclusion

In our study for appendiceal mass/abcess management, conservative management with interval appendectomy showed the incidence of recurrence is less and the complications are not much appreciable. Based on all these findings, interval appendectomy is considered to be beneficial in a conservatively treated case of complicated appendicitis because of Low conversion rate, less complication rate and less hospital stay.

### References

- [1] Margaret Farquharson (Author), Brendan Moran (Author). Operations on appendix. In Farquharson's Textbook of Operative General Surgery, 9<sup>th</sup> Edition A Hodder Arnold Publication.
- [2] Muhammad Shoib Hanif, Tufail Hussain Tahir, Irfan Ali sheikh, Muhammad Zaman Ranjha. Acute appendicitis: gaining time in mass casualty scenario. Pak Armed Forces J Med 2010; 3 23-25.
- [3] Chan L, Shin LK, Pai RK, Jeffery RB. Pathologic continuum of acute appendicitis: Sonographic findings and clinical management implications. Ultrasound Q 2011;27(2):71-9.
- [4] Tannoury J, Abboud B. Treatment options of inflammatory appendiceal masses in adults. World J Gastroenterol. 2013;19(25):3942–3950.
- [5] Cueto J, D'Allemagne B, Vázquez-Frias JA, Gomez S, Delgado F, Trullenque L, et al. Morbidity of laparoscopic surgery for complicated appendicitis: an international study. Surgical Endoscopy 2006;20(5):717–20.
- [6] Norman S. William, Christopher J. K. Bulstrode, P Ronan O' Connel in Vermiform appendix in Short practice Of surgery, 25th ed, 2008, Edward Arnold publisher Ltd 1205-1217.
- [7] Deelder JD, Richir MC, Schoorl T, Schreurs WH. Journal of Gastrointestinal Surgery 2014;18(4):641–5.
- [8] Kirkwood KS, Maa J. The appendix. In: Sabiston DC, Townsend CM, editors. Sabiston textbook of surgery: the biological basis of modern surgical practice. 18th ed. Philadelphia: Saunders/Elsevier; 2008. pp. 1333–1347.
- [9] Cheng Y, Xiong X, Lu J, Wu S, Zhou R, Lin Y, et al. Early versus delayed appendectomy for appendiceal phlegmon or abscess. Cochrane Database of Systematic Reviews 2015, Issue 4. [DOI: 10.1002/14651858.CD011670].
- [10] Buckius MT, McGrath B, Monk J, Grim R, Bell T, Ahuja V. Changing epidemiology of acute appendicitis in the United States: study period 1993–2008. Journal of Surgical Research 2012;175(2):185–90.
- [11] Anderson JE, Bickler SW, Chang DC, Talamini MA. Examining a common disease with unknown etiology: trends in epidemiology and surgical management of appendicitis in California, 1995–2009. World Journal of Surgery 2012;36(12):2787–94.
- [12] Willemsen PJ, Hoorntje LE, Eddes EH, Ploeg RJ. The need for interval appendectomy after resolution of an appendiceal mass questioned. Dig Surg. 2002; 19: 216–220].
- [13] Wright GP. Is there truly an oncologic indication for interval appendectomy? Am J Surg. 2015; 209: 442–6].
- [14] Andersson RE. Meta-analysis of the clinical and laboratory diagnosis of appendicitis. Br J Surg. 2004 Jan. 91(1):28-37.
- [15] Salminen P, Paajanen H, Rautio T, Nordström P, Aarnio M, Rantanen T, et al. Antibiotic Therapy vs Appendectomy for Treatment of Uncomplicated Acute Appendicitis: The APPAC Randomized Clinical Trial. JAMA. 2015 Jun 16. 313 (23):2340-8. [Medline].
- [16] Cariati A, Brignole E, Tonelli E, Filippi M, Guasone F, De Negri A. [Laparoscopic or open appendectomy. Critical review of the literature and personal experience]. G Chir. 2001 Oct.
- [17] Esposito C, Borzi P, Valla JS, Mekki M, Nouri A, Becmeur F. Laparoscopic versus open appendectomy in children: a retrospective comparative study of 2,332 cases. World J Surg. 2007 Apr. 31(4):750- 5. [Medline].
- [18] Sauerland S, Lefering R, Neugebauer EA. Laparoscopic versus open surgery for suspected appendicitis. Cochrane Database Syst Rev. 2004 Oct 18. CD001546. [Medline].
- [19] McBurney C. II. The Indications for Early Laparotomy in Appendicitis. Ann Surg. 1891 Apr. 13(4):233-54. [Medline].
- [20] Semm K. Endoscopic appendectomy. Endoscopy. 1983 Mar. 15(2):59-64. [Medline].