

A Retrospective Study of Functional Outcome of Close Bimalliolar Fracture Treated by Open Reduction and Internal Fixation by Various Methods at Tertiary Centre

Dr. Narendra Singh¹, Dr. Abhinav Bhardwaj², Dr. Arun Vaishy³, Dr. Kalika Vaish⁴

¹Department of Orthopaedic and Research and Rehabilitation Centre Dr. S. N. Medical College Jodhpur (Rajasthan)
Corresponding Author Email: [dr.narendranu\[at\]gmail.com](mailto:dr.narendranu[at]gmail.com)

^{2,3}Department of Orthopaedic and Research and Rehabilitation Centre Dr. S. N. Medical College Jodhpur (Rajasthan)

⁴Professor, Department of Orthopaedic and Research and Rehabilitation Centre Dr. S. N. Medical College Jodhpur (Rajasthan)

Abstract: ***Background:** Ankle injuries gain importance because body weight is transmitted through it and locomotion depends upon the stability of this joint. Unstable displaced and open fractures require open reduction internal fixation. Objectives were retrospective study of functional out come and results of surgical treatment of bi-malleolar fractures and to know the complications of open reduction and internal fixation in bi- malleolar fractures. **Methods:** Total 125 patients were studied from January 2019 to December 2022. They were classified according to Lauge Hansens classification and treated according to the Arbeitsgemeinschaft für Osteosynthesefragen (AO) system. Assessment of the outcome was done using the scoring system of Baird and Jackson which is based on subjective, objective and radiological criteria. **Results:** Mean follow up was 3.5yr in between January 2019-December 2022. Out of 125 patients evaluated, overall good to excellent results were obtained in 95 (76%) patients. The results were fair in 15 (12%) and poor in 15 (12%) patients. There were no intraoperative complications. The post-operative complication we came across is superficial skin infection in 20 (16%) patients. **Conclusion:** Anatomical reduction is essential in all intra articular fractures, more so if a weight bearing joint like ankle is involved open reduction and internal fixation guarantee high standard of reduction besides eliminating chances of loss of reduction. The fibular length has to be maintained for lateral stability of the ankle. Chances of non-union of medial malleolus interposition of the periosteum and deltoid ligament are avoided. Poor clinical results are found to be associated with unsatisfactory surgical reduction.*

Keywords: Ankle injuries; Ankle surgery; Bone screws; Fractures; Complications, Fracture fixation; Treatment outcome

1. Introduction

Sir Robert Jones said “Ankle is the most injured joint of the body but the least well treated¹. Malleolar fractures are one of the most common fractures in orthopedic traumatology. As with all intra articular fractures, malleolar fractures necessitate accurate reduction and stable internal fixation. If malleolar fractures are not reduced accurately they may lead to post traumatic painful restriction of motion or osteoarthritis or both [1]. Many of the fractures which are stable are reduced by conservative treatment and have given good result. The other unstable displaced and open fractures require open reduction and internal fixation (ORIF). The superiority of ORIF over closed treatment have been thoroughly demonstrated in literature [2]. However, results were not impressive in cases of bimalleolar fractures. The purpose of this study is to assess the functional outcome using Baird and Jackson system and results of surgical treatment of bi-malleolar fractures.

2. Methodology

Patients with fresh close bimalleolar fractures were admitted in department of orthopedics, hospital attached to GOVERNMENT MEDICAL COLLEGE SIROHI between January 2019 and January 2022 and total 125 patients were studied. After admission to ward a complete survey was carried and detailed history was taken regarding

demographic data, mode of injury past and associated medical illness. Clinical examination done to rule out other injuries then the patient's radiographs were taken, anteroposterior, lateral and mortise views of the ankle joints.

Operative Technique: Under appropriate anesthesia the patient was put in supine position on table with folded towel underneath the affected side buttock. Pneumatic tourniquet was applied to the proximal thigh after noting the time. ORIF of the malleolar fractures were performed by tension band wiring, malleolar screw, K- wire fixation or semi-tubular plating with screws.

Exposure and Fixation of Medial Malleolus: A medial longitudinal incision of 8cm was put over the medial malleolus between its anterior and posterior borders with the lower end curving anteriorly at the tip of medial malleolus. The fracture site was exposed and cleared of blood clots and intervening periosteum with a curet exposing small serrations of the fracture. The distal fragment was held with a towel clip and pulled proximally, reducing the small serrations of the fracture. Two K- wires of 2mm diameter and 8cm long were passed one anterior and one posterior from the tip of the malleoli to the proximal tibia transfixing the malleoli to the tibia without entering the joint. The towel clip was removed and a drill hole was made, 5cm proximal to the fracture, on the tibia from anteromedial aspect to anterior aspect with 3.5mm drill bit protecting the soft

tissues anteriorly with a right-angled retractor. An AO wire of 20 gauge is passed through the predrilled hole on the tibia from anteromedial to anterior aspect and was made in the figure of eight passing behind the two K-wires and tensioned with an AO tensioner and the tips of wire was cut with a cutter. The two K-wires were bent with bender and punched into bone engaging the wire, protecting the tibialis posterior tendon and neurovascular bundle.

For Malliolar Screw Fixation: Similarly, reduction of fracture was done with a towel clip and a drill hole was made perpendicular to the fracture line with 3.2mm drill bit and then tapped with 4.5mm tap securing the reduction. A 4.5mm malleolar screw was used. The screws were tightened to provide compression at the fracture site.

Exposure and Fixation of Lateral Malleolus:

Nailing: Fixed with intramedullary implants by making small incision over tip of lateral malleolus for closed reduction and internal fixation (CRIF).

Plating: An anterolateral approach through a J-shaped incision is used more frequently than any other incision on the lateral side. The most common fracture for which surgery is undertaken is the Weber type B or the supination-external rotation fracture stage 3 and 4. The fibular fracture is oblique or spiral, begins at the level of the syndesmosis, and extends proximally from the anterior cortex in a posterosuperior direction to the posterior cortex. This fracture is best exposed by this "curved hockey stick" incision. The incision begins at the anterior border of the distal end of the fibula and extends distally to arch around the anterior and inferior margin of the malleolus. The proximal part of the incision runs even closer and almost parallel to the superficial peroneal nerve. It is therefore identified to avoid injury to it. Another incision is the mid-lateral incision placed midway between the anterior and posterior borders of the distal end of the fibula and lateral malleolus. The incision is carried down to bone, and only then is dissection extended anteriorly and posteriorly immediately superficial to bone to expose the fracture. In this manner, full thickness skin flaps are obtained with their blood supply adequately protected to prevent any subsequent skin necrosis.

Follow Up: Patients were followed weekly for 6 weeks then monthly for 6 months. Slab was removed at 2 weeks and non-weight bearing exercise were started. Weight bearing was restricted for 6 weeks. Final score was taken at 1 year.

Functional and Radiological Evaluation: Functional and radiological results were analyzed using the ankle scoring system of Baird and Jackson³¹. The evaluation was based on physical and radiological examination. Physical examination included the measurement of active dorsiflexion and plantar flexion of injured ankle compared with the uninjured ankle, with forepart of foot in neutral position. Radiologically the medial clear space superior joint space and talar tilt was measured. The seven categories in the scoring system were given alphabetical grades each being assigned a point score.

Excellent = 96 to 100 points, Good = 91 to 95 points, Fair = 81 to 90 points, and Poor = zero to 80 points.

Grade A was considered to the normal pre-injury condition. The alphabetical grades were assigned to point score that was weighted to emphasize pain, walking stability motion and radiographic findings.

Final scores were based on the combined point scores from 7 categories of subjective objective and radiographic evaluation. Results were designated as excellent good fair and poor.

3. Results

The mean age of this study was 42.65 years. In our study majority were (61.6%) male patients. Right side (63.2%) was common side. Road traffic accident was major cause of injury constituting 52% of patients. Most fractures (34.4%) occurred in 51-60 years of age group. In our study majority 48 (38.4%) patients had supination and external rotation injuries followed by 33 (26.4%) patients having pronation external rotation and 24 (9.2%) patients had supination adduction injuries and 20 (16%) patients having pronation abduction. All the fractures were followed until fracture union occurred. Results were analyzed both clinically and radio graphically. Almost all fractures united at around the end of 10 weeks.

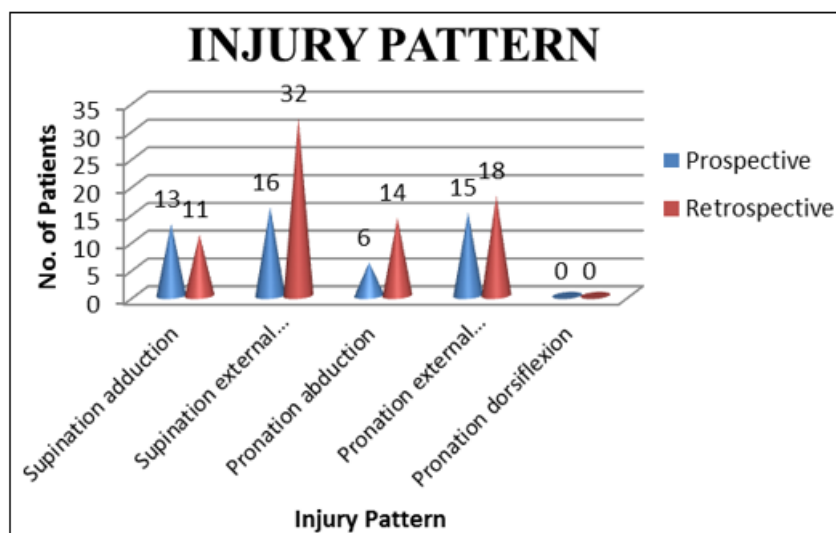


Figure 1: Distribution of injuries among study subjects

Table 1: Distribution of Baird and Jackson score among patients.

Type of Injury		Total				
Excellent (96-100 points)		75 (60%)				
Good (91-95 points)		20 (16 %)				
Fair (81-90 points)		15 (12 %)				
Poor (0-80 points)		15 (12 %)				
Total		125 (100 %)				
Category	A	B	C	D	E	Total
Pain	65	56	4	0	0	125
Stability	125	0	0	0	0	125
Walking	105	12	8	0	0	125
Running	31	62	32	0	0	125
Work	94	29	2	0	0	125
Motion	98	21	6	0	0	125
Radiographs	95	20	6	2	2	125

4. Discussion

Increased knowledge about the normal and post traumatic anatomy and function of the ankle joint has led to demands for exact reduction and rigid fixation of the ankle fractures. Prompt operative treatment of displaced ankle fractures decreases morbidity and improves functional outcome [3][4][5]. The treatment of malleolar fractures with accurate open reduction and stable internal fixation using AO method and principles was found to give a high percentage of excellent and good results. This study supports these conclusions. Although the scoring of Baird and Jackson has proven to be strict allowing only very small fluctuation from normal about 75 (60%) patients in this series achieved excellent results by that scoring system and 20 (16%) patients achieved good results and also had anatomical reduction of the lateral malleolus as well as anatomical reduction of talus radiologically.

Table 2: Comparison with other studies.

Category	Roberts SR.	Baird and Jackson	Beris, et al.	Lee et al	Our Study
no. of patients	25	24	144	168	125
mean age (years)	40	30	43	44	42.65
sex male %	44%	70%	38.88%	42.90%	61.10%
Rt side % involvement	56%	45.80%	73%	not given	63.20%
mode of injury most common	Not mention	fall from height	Not mention	RTA	RTA
type of injury most common SER	34%	44%	Not mention	Not mention	38.40%

Table 3: The results in our study were compared with that of Burnwell and Charnley³³, Colton³⁶, DeSouza et al³⁵, Beris et al²

Authors	Good to Excellent	Fair	Poor
Burnwell & Charnley ³³	102 (77.3%)	22 (16.7%)	8 (6%)
Colton ³⁶	18 (70.0%)	4 (15.0%)	4 (15.0%)
Beris et al., ²	105 (74.3%)	21 (14.6%)	16 (11.1%)
Desouza ³⁵	135 (90.0%)	9 (6%)	6 (4%)
Our Study	95 (76.0%)	15 (12%)	15 (12%)

Observation in this study support the contention of Yablon et al [6] that lateral malleolus is the key to the anatomical reduction of bimalleolar fractures, because the displacement of the talus faithfully followed that of the lateral malleolus. Poor reduction of distal part of fibula would result in

persistent lateral displacement or residual shortening. This does not necessarily lessen the importance of the medial malleolus in contributing to the congruity of medial aspect of ankle, but it does serve to emphasize that the lateral malleolus should no longer be ignored in the treatment of ankle injuries. The patient who had poor result did not have anatomical reduction of lateral malleolus and medial malleolus as well.

Although early mobilization was advocated by AO immobilization also has been supported. Others have found no significant difference in the results produced after early motion or immediate plaster splintage. In our study immobilization in a plaster slab for 2 weeks followed by mobilization and partial weight bearing was used successfully. The range of motion was reduced initially but

after the slab removal the ankle movement rapidly improved. A number of different treatment regimens have been suggested. Burwell and Charnley³³ advocated postoperative joint mobility exercises in bed until motion was restored followed by full weight bearing in a cast. Lund-Kristensen et al [7] either used no cast or applied one for a few days postoperatively and then allowed full joint mobilization out of the cast. They advocated the use of crutches to maintain a non-weight bearing status. Meyer and Kumler used a post operative cast but only for an average of 3.8 weeks followed by non-weight bearing mobilization until fracture union.

Early mobilization of ankle joint (post-operative) in our study (from 2019 to 2022) was keystone for excellent results 60 %. Mobilization of ankle joint mainly depends on bone quality and stable fracture fixation if there is present we can mobilize as early as possible.

In our study the decisive factors that influence the results are

- 1) Type of fracture, severity of injury is inversely proportional to the final results obtained.
- 2) Plaster slab immobilization for 6 weeks did diminish the ankle motion. The rapid gaining of motion from 2 to 3 weeks may be due to the positive attitude to exercise and resumption of weight bearing at 6 weeks.
- 3) Proper and stable fixation of fracture site by AO guide line.
- 4) Proper reduction of fracture site to avoid mal-union and arthritic changes like maintaining length of fibula and ankle mortise also.
- 5) Proper use of instrument and soft tissue handling.

Malleolar fractures of the ankle have a varied presentation. They can range from isolated fibular fractures with no displacement to a trimalleolar injury with dislocation and vascular compromise. A broad understanding of all aspects of mechanism of injury, path-anatomy and treatment options coupled with training experience is required before

any attempt should be made to treat these injuries with thorough understanding of injury patterns repair of the damaged ankle joint can lead to rewarding outcomes for the patient and physician.

5. Conclusion

In this review of 125 patients with ankle fractures that were unstable displaced or both treated surgically by Open reduction and internal fixation in accordance with AO principles:

- 1) Majority of them were caused by supination external rotation injuries. The most common etiology being Road traffic accident.
- 2) Males more affected and more affected age incidence group of 51-60 years.
- 3) Understanding the mechanism of injury is essential for good reduction and internal fixation.
- 4) The bend of the lateral malleolus should be reproduced when the plate is being used.
- 5) The fibular length has to be maintained for lateral stability of the ankle.
- 6) Anatomical reduction is essential in all intra articular fractures more so if a weight bearing joint like ankle is involved. Open reduction and internal fixation guarantee high standard of reduction besides eliminating the chances of loss of reduction.
- 7) The operative results were eminently satisfactory in 76% of patients
- 8) More severe injuries were followed by least satisfactory results.
- 9) Most of the complications faced were minor which resolved by 2 weeks.
- 10) Tension band wiring is the method preferred for small fragments and osteoporotic bones of both medial and lateral malleolus.

Result – Excellent

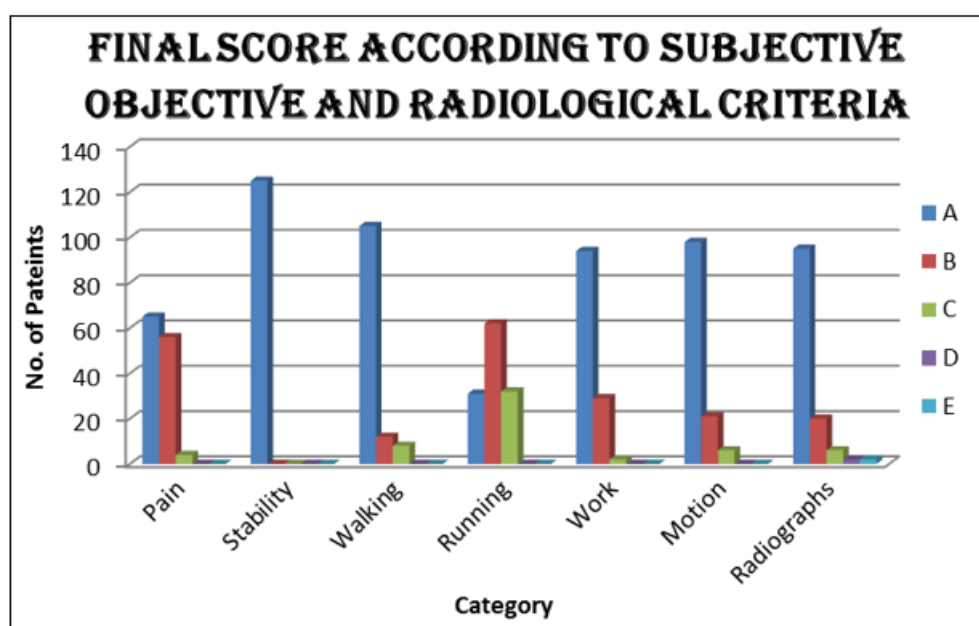


Figure 2: Distribution of final score (Baird and Jackson) among study subjects.

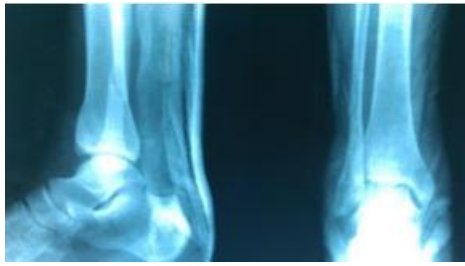

Figure 3: Preop X-ray

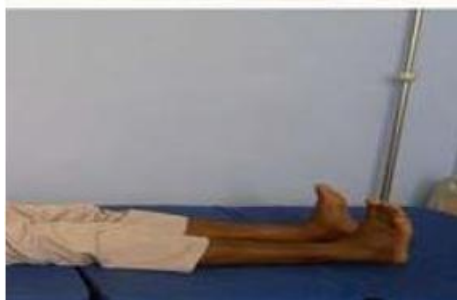
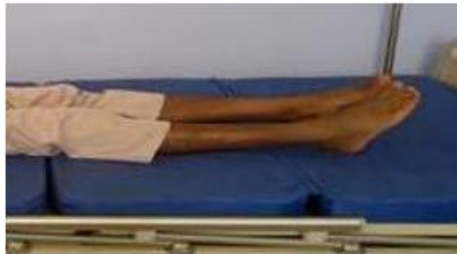
Figure 4: Dorsiflexion and plantar flexion of the Ankle

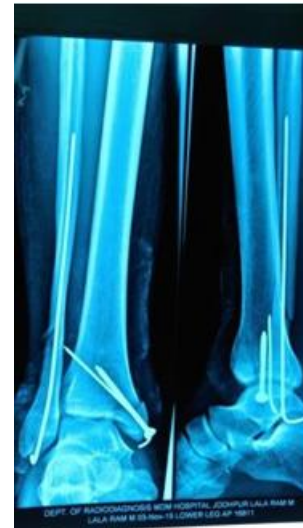

Figure 5: Postop X-ray

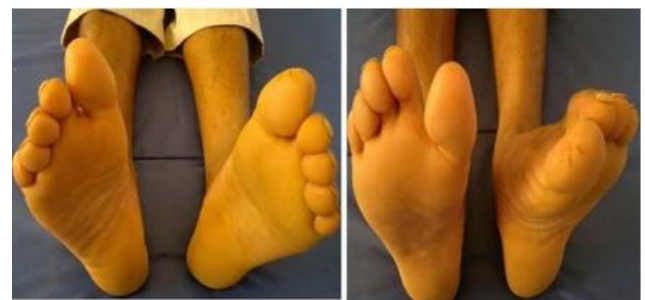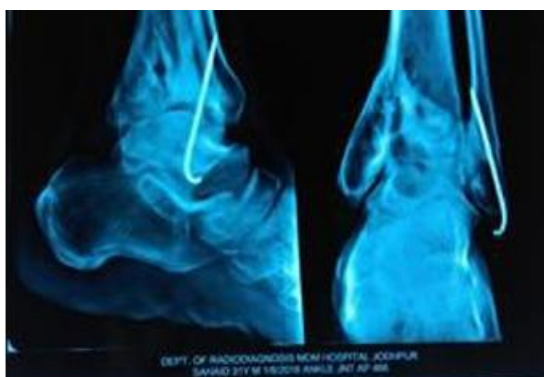


Figure 6: Inversion and Eversion

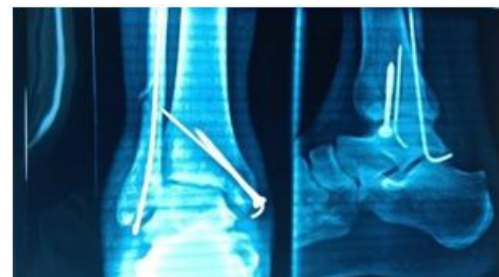
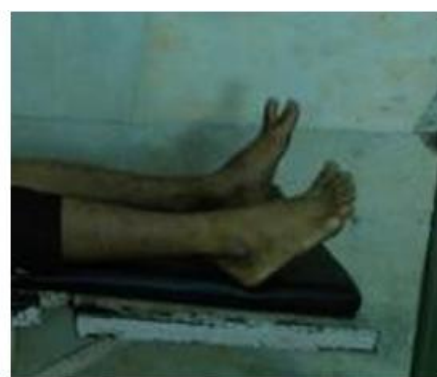
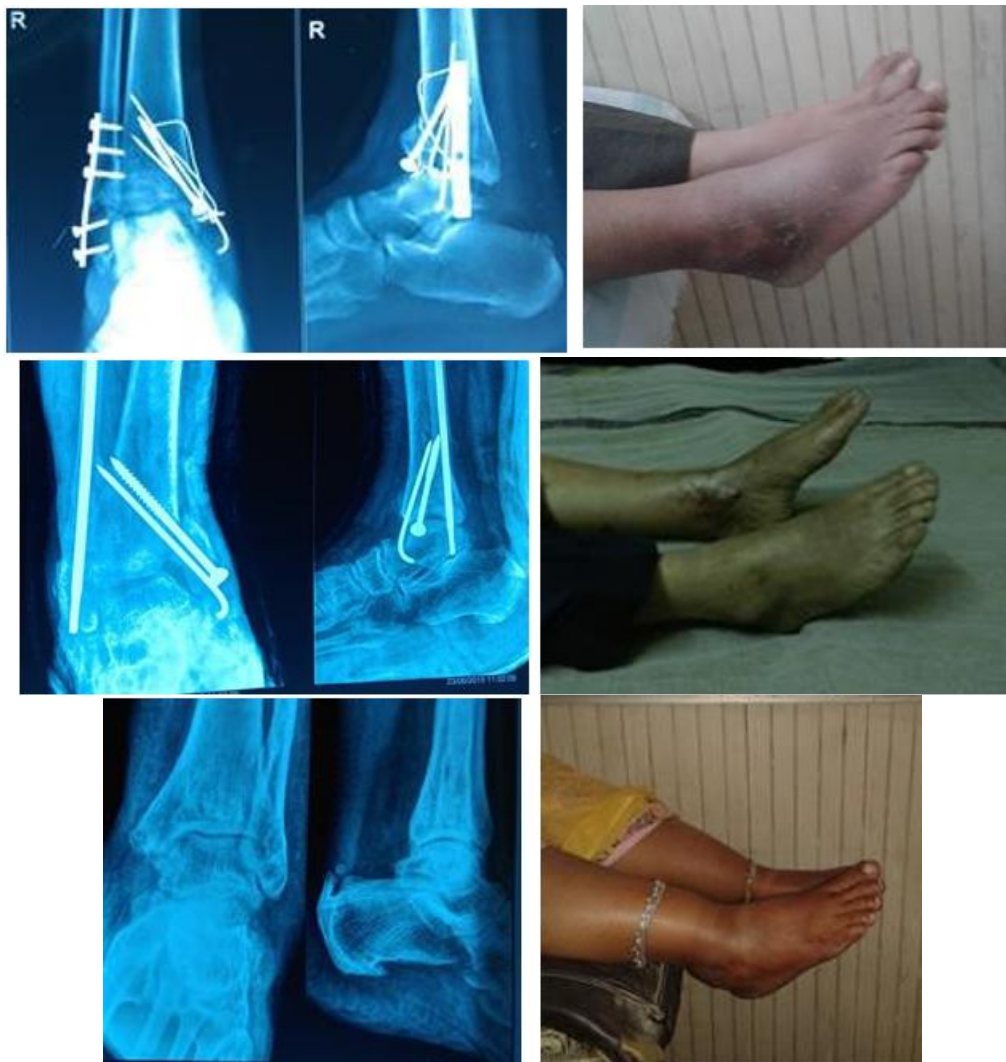Figure 7: Follow up at 10 weeks

6. Complications





References

- [1] Beris AE, Kabbani KT, Xenakis TA, Mitsionis G, Soucacos PK, Soucacos PN. Surgical treatment of malleolar fractures – a review of 144 patients. Clin Orthop Related Research, 1997 Aug; 341: 90- 98.
- [2] Weber MJ. Ankle fractures and dislocations. In: Operative orthopaedics, Chapter-50, 2nd edn., Vol.3, Ed. Chapman MW, Madison M. Philadelphia: J.B. Lippincott Company, 1993; 731- 748pp.
- [3] Lindsojo U. Operative treatment of ankle fracture – dislocations. Clin Orthop, 1985; 199: 28- 38.
- [4] Burwell HN and Charnley AD. The treatment of displaced fractures at the ankle by rigid internal fixation and early joint movement. J Bone Joint Surg, 1965; 47B: 634- 660.
- [5] Roberts RS. Surgical treatment of displaced ankle fractures. Clin Orthop, 1983; 172: 164- 170.
- [6] Yablon IG, Heller FG, Shouse L. The key role of the lateral malleolus in displaced fractures of the ankle. J Bone Joint Surg, 1977; 57A: 169-173.
- [7] Geissler WB, Tsao AK, Hughes JL. Fractures and injuries of ankle. In: Rockwood and Greens fractures in adults. Chapter- 31, 4th edn., Vol.2, edt. Rockwood CA, Green DP, bucholz RW, Heckman JD. Philadelphia: Lippincott Raven, 1996; 2201- 2266pp.