

# Laparoscopic Surgical Management of Ovarian Fibroma with Torsion in Young Female: A Case Report

Dr. Neeta Meena

Senior Resident, Vardhman Mahavir Medical College & Safdarjung Hospital, New Delhi, India

**Abstract:** Ovarian fibroma with torsion is a rare but serious condition, especially in young females. Ovarian fibromas are benign, slow-growing tumors composed mainly of fibrous tissue. When torsion occurs, the ovary twists around its supporting ligaments, cutting off blood supply to the ovary. This case report presents a case of a 31-year-old who presented with features suggestive of ovarian torsion. Diagnostic difficulty was faced due to the complex appearance of the mass and presenting age of the patient. However, the diagnosis was confirmed by histopathology reported a large 14cm multiloculated cystic lesion likely ovarian fibroma. This can lead to acute abdominal pain, nausea, and vomiting, often mimicking other gynecological or gastrointestinal emergencies. Diagnosis is typically made via imaging such as ultrasound or MRI, but definitive diagnosis requires surgical exploration. Early intervention is crucial to prevent ovarian necrosis, with laparoscopic detorsion or removal of the mass being the preferred treatment.

**Keywords:** Ovarian fibroma, Sex cord tumor, Torsion, Iliac fossa tenderness, Adnexal mass

## 1. Introduction

Ovarian fibromas are sex cord solid tumors of the ovary that account for 1 - 4% of all benign tumors. [1] The diagnosis is often difficult because the absence of the specific symptoms and a delay of surgical treatment can lead to adnexectomy. Therefore, the ovarian torsion should be suspected in a girl who presents an abdominal pain in iliac or hypogastric region. Also, the presence of a cystic tumor in the ovary on ultrasound should lead to surgical exploration in emergency, usually by laparoscopy. The sensitivity of ultrasound in diagnostic of ovarian torsion is from 40% to 75% [2]

This ovarian torsion is a gynecological emergency that requires prompt surgical intervention to prevent necrosis of the ovarian tissue. Surgical management, often involving detorsion, tumor removal, or oophorectomy depending on the severity, aims to alleviate symptoms, preserve ovarian function when possible, and prevent further complications. We report a case of ovarian fibroma in a young woman who presented with symptoms of ovarian torsion and had laparoscopic surgical intervention with histopathology report for confirming final diagnosis.

## 2. Case Report

A 31-year-old, Para 0 with one miscarriage at 2 months spontaneously. She had come in emergency department with severe lower abdominal pain and vomiting for 1 day. She was absolutely symptomless 1 day back. Pain was described as continuous, sharp and located in the lower abdomen, no other previous medical, surgical or gynecological history of note reported. On examination revealed left iliac fossa tenderness with guarding and felt a suprapubic mass on palpation. On per vaginal examination revealed a normal sized uterus left side adnexal fullness was noted on bimanual examination. CT abdomen and pelvis MRI showed a large 12.6×10×14.3 cm multiloculated cystic lesion occupying the Centre of the pelvis, likely ovarian in origin with multiple loop of torsion

but could not rule out ovarian malignancy and minimal ascitic fluid notes (CT scan Figure 1).

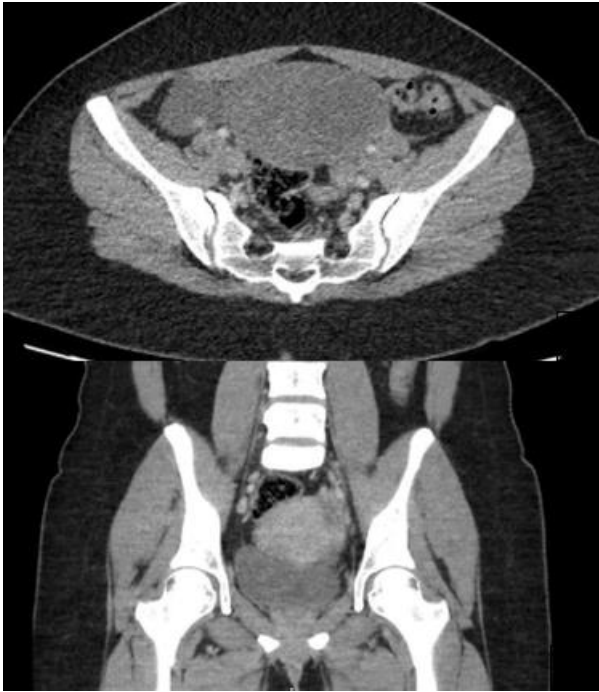All blood investigation and tumor marker sent all investigations are within normal limits.

Blood serum CA 125 level was normal 35 nearly borderline (normal range 0-35 U/ml). pregnancy test was negative.

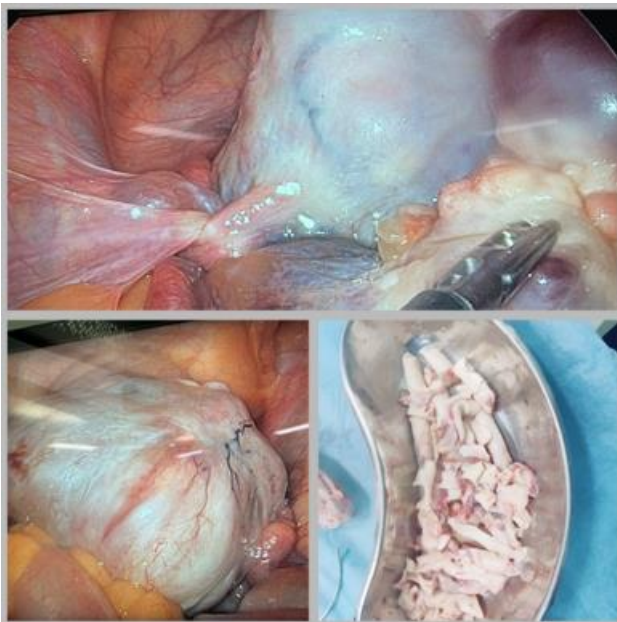
Patient was prepared for emergency laparoscopic surgery and proceed in view of her ongoing pain. Intraoperative, a solid adnexal mass around 14 cm size was found in the left side with no cystic area noted, and left side fallopian tube and ovary couldn't visualization done clearly and there was two and half twist present and followed by untwisting done and plicated and tube and ovary of left side completely engulf by Tubo ovarian mass and left side salpingo - oophorectomy done. In left side port opening extended around 2.5 cm was made and tissue removed by morcellation.

(As shown in figure 2)

The tissue was fibrotic and solid with necrotic content noted and removed and sent for histopathology, ovarian specimen was obtained for histopathology and also, peritoneal washout for cytology. She had an uneventful recovery and was sent home with plan for follow up scan and review in hospital.



**Figure 1:** CT scan of this case showing around 12 - 14 cm size central pelvis mass arising from left side



**Figure 2:** Laparoscopic surgery finding of left side ovarian fibroma with torsion with 2 and half loop, removal with morecellation

Histological examination of the specimen (shown in figure 2) confirmed the diagnosis of ovarian fibroma with densely cellular lesion containing bland spindle cells. Cytology analysis for peritoneal washing was negative for malignancy. The patient is currently having regular interval follow up in the outpatient clinic.

### 3. Discussion

Ovarian fibroma, a mesenchymal neoplasm, is the most common benign solid tumour of the ovary, generally diagnosed in perimenopause and postmenopausal females. [2] It frequently presents as a large mass undergoing torsion

causing acute abdominal pain. It can be associated with ascites and pleural effusion as in Meigs syndrome. It can also be seen with uterine fibroids suggesting hormonal stimulation as common etiology. Infertility and hirsutism can be rarely associated with ovarian fibromas. [3]

Diagnosis of ovarian fibroma involves the use of imaging studies ultrasound (USS) and magnetic resonance imaging (MRI) as well as tissue histopathology for confirmation. [4]

Transvaginal ultrasound and Doppler ultrasound imaging of the pelvis are important tools in the preoperative diagnosis with features such as solid hypoechoic masses with acoustic attenuation as well as minimal doppler flow.

Treatment of ovarian fibromas is surgery. Despite their benign status, most operations involve open surgical access with resection of the ipsilateral adnexa [5]. Resection of the fibroma with laparotomy or laparoscopy seems to be the appropriate treatment choice in women who wish to preserve fertility. The recurrence rate is estimated to be about 2% of cases [6]

Laparoscopic access of ovarian fibromas should be severely considered in cases of exophytic ovarian tumors in women of reproductive age [7]

### 4. Conclusion

Ovarian fibromas with torsion is unusual finding, preoperative diagnosis is highly difficult, surgery with histopathological finding is used to establish the exact diagnosis. In this case clearly demonstrates the limitation of pre - operative assessment of benign adnexal masses. In this case there is ovarian fibroma torsion with two and half loop and whole ovary of that side convert into solid tumor -like structure. The key to salvaging ovarian function includes high clinical suspicion and prompt timely investigations with emergency surgical intervention.

### References

- [1] R. Mashiach, N. Melamed, N. Gilad, G. Ben - Shitrit, I. Meizner Sonographic diagnosis of ovarian torsion: accuracy and predictive factors J Ultrasound Med, 30 (9) (2011), pp.1205 - 1210
- [2] P, Khong K, Lamba R, Corwin MT, Gerscovich EO. Ovarian fibromas and fibrothecomas: Sonographic correlation with computed tomography and magnetic resonance imaging: A 5 - year single - institution experience. J Ultrasound Med.2013; 32: 13–8. [PubMed] [Google Scholar]
- [3] Macciò A, Madeddu C, Kotsonis P, Pietrangeli M, Paoletti AM. Large twisted ovarian fibroma associated with Meigs' syndrome, abdominal pain and severe anemia treated by laparoscopic surgery. BMC Surg.2014; 14: 38. [PMC free article]
- [4] Montoriol PF, Mons A, Da Ines D, Bourdel N, Tixier L, Garcier JM. Fibrous tumours of the ovary: aetiologies and MRI features. Clin Radiol.2013; 68 (12): 1276 - 83.
- [5] Laparoscopic ovarian - sparing surgery for a young woman with an exophytic ovarian fibroma. Hasegawa A, Koga K, Asada K, Wada - Hiraike O, Osuga Y,

Kozuma S. J Obstet Gynaecol Res.2013; 39: 1610–1613. [PubMed] [Google Scholar]

- [6] Ovarian - sparing local mass excision for ovarian fibroma/fibrothecoma in premenopausal women. Cho YJ, Lee HS, Kim JM, Lee SY, Song T, Seong SJ, Kim ML. Eur J Obstet Gynecol Reprod Biol.2015; 185: 78–82. [PubMed] [Google Scholar]
- [7] Laparoscopic ovarian - sparing surgery for a young woman with an exophytic ovarian fibroma. Hasegawa A, Koga K, Asada K, Wada - Hiraike O, Osuga Y, Kozuma S. J Obstet Gynaecol Res.2013; 39: 1610–1613. [PubMed] [Google Scholar]