

Histopathological Spectrum of Skin Lesions in a Tertiary Care Centre

Deepa J.^{1*}, Prathima S.²

¹Postgraduate, Department of Pathology, Vydehi Institute of Medical Science and Research Center, Bangalore (Corresponding Author)

²Professor and Head of the Department of Pathology, Vydehi Institute of Medical Science and Research Centre, Bangalore

Abstract: ***Introduction:** Skin is the largest organ of the body. And is also the most exposed part to harmful UV rays of sun giving rise to various neoplastic and non - neoplastic conditions. The spectrum varies according to geographic distribution, age, gender and coexisting disorder. Aim: To determine the histopathological spectrum of skin lesions at our tertiary care center and to evaluate their frequency, age and sex distribution. Methods and materials: A retrospective study was done in the Department Of Pathology, Vydehi Medical College and Hospital, Bangalore, India. All skin biopsies received in one year between January 2022 to December 2022 were included. Results: Among 227 skin biopsies examined, inflammatory lesions were the most common 149 cases (65%) followed by infectious diseases 47cases (20.7%) in which bacterial 29 cases (57%) were most common and least being neoplastic category with 9.2% of malignant tumors and 4 % of benign tumors. Most of the skin lesions found were in age group between 20 - 30 years with male preponderance (M: F 1.76: 1). Papulosquamous lesions 60 cases (26%) were the most common lesions overall. Conclusions: Papulosquamous lesions are the predominating non - neoplastic and overall skin lesions, which was similar to the other studies done. Many skin diseases present with similar clinical lesions. Hence, skin biopsy and Histopathological examination becomes inevitable in various skin disorders to confirm diagnosis and initiate treatment*

Keywords: Papulosquamous lesions, Histopathology, SCC

1. Introduction

Skin is the largest organ of the body. Skin is the most sun exposed organ and it is susceptible to wide spectrum of disorders ranging from inflammatory to neoplastic lesions. The spectrum varies according to geographic distribution, age, gender and coexisting disorder [1, 2].

Clinical presentation vary from macules, papules, nodules, hypo and hyper - pigmented lesions [3]. However, most of these presentations are common in multiple diseases. Hence, histopathological examination becomes necessary to arrive at a specific diagnosis which becomes important for specific treatment [4].

Aims and Objectives

Our study was conducted to determine the histopathological spectrum of skin lesions and to evaluate their frequency, age and sex distribution of skin lesions at our tertiary care center.

2. Methods and Materials

The present study is a retrospective study done in the Department of Pathology, Vydehi Medical College and Hospital, Bangalore, India includes all skin biopsies received in one year between January 2022 to December 2022. Ethical clearance was obtained from the Institutional Ethics Committee. A total of 227 cases were selected as sample size on the basis of inclusion and exclusion criteria. From the records of department relevant clinical details were obtained. H & E-stained histopathology slides were examined. All skin biopsies that showed definite signs of any specific pathology received in histopathology laboratory of the Department of Pathology during the study period were included. Inadequate, inconclusive skin biopsies that did not show definite signs of any specific pathology were excluded from this study. The

results were evaluated according to types of lesions, frequency of lesions, demographic distribution.

3. Results

Among 227 skin biopsies examined, inflammatory lesions were the most common 149 cases (65%) followed by infectious diseases 47cases (20.7%) in which bacterial lesions 29 cases (57%) were most common and least being neoplastic 31cases category with 9.2% of malignant tumors and 4 % of benign tumors. (Table 1 and 2)

Table 1: Distribution of Various Disease Types

1	Infective Lesion	47
2	Inflammatory Lesion	149
3	Neoplastic Lesion	31

Table 2A, 2B: Disease wise distribution of all cases

TABLE 2A		
S/No	CATEGORY	Number
1	INFECTIVE LESIONS	47
	Bacterial	29
	Viral	10
	Fungal	8
2	INFLAMMATORY LESIONS	149
	Papulosquamous	60
	Vesiculobulous	4
	Dermatitis	26
	Hair follicular disorders	3
	Lupus lesions	4
	Pigmentary disorders	4
Miscellaneous	48	

Table 2B

MALIGNANT LESIONS	21
1. SQUAMOUS CELL CARCINOMA	14
2. BSASAL CELL CARCINOMA	4
3. BASOSQUAMOUS CARCINOMA	2
4. MALIGNANT MELANOMA	1
BENIGN LESIONS	10
1. NEUROFIBROMA	4
2. DERMATOFIBROMA	1
3. SEBORRHEIC KERATOSIS	3
4. ANGIOKERATOMA	1
5. TRICHOFOLLICULOMA	1

Most of the skin lesions found were in age group between 20 - 30 years with male preponderance (M: F 1.76: 1). (Table 3)

Table 3: Distribution of Skin Lesions According to Age and Sex

Age Groups	Total	Male	Female
0 - 19	27 (12%)	15	12
20 - 30	57 (25%)	41	16
31 - 40	53 (23%)	32	21
41 - 50	41 (18%)	27	14
51 - 60	22 (9.7%)	10	12
61 - 70	20 (8.8%)	16	4
>70	7 (3%)	4	3
TOTAL	227	145 (63.9%)	82 (36.1%)

Papulosquamous lesions 60 cases (26%) were the most common lesions overall. Histopathology slides from the sample showing various lesions. (Figure 1 - 6)

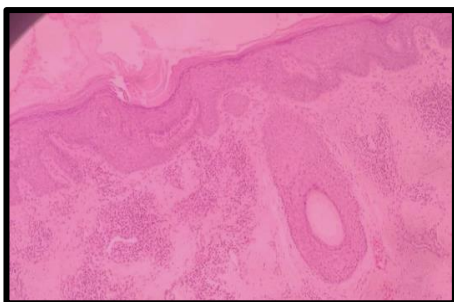


Figure 1: Photomicrograph showing epidermis with hyperkeratosis and parakeratosis; Psoriasis vulgaris (H&E, 40x)

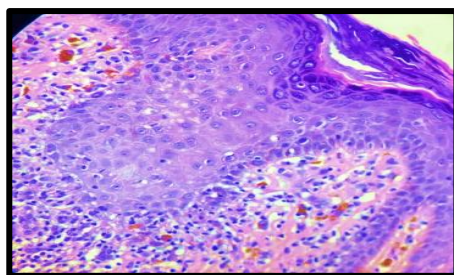


Figure : Photomicrograph showing wedge shaped hypergranulosis, pigment incontinence, lymphocytic infiltrate; Lichen planus (H&E, 40x)

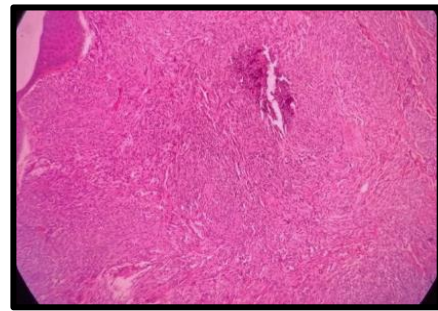


Figure 3: Photomicrograph showing spindle shaped histiocytes, Histoid leprosy (H&E, 10x)

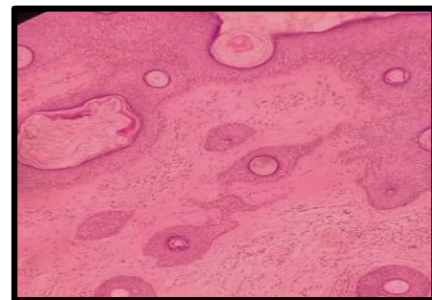


Figure 4: Photograph of Trichofolliculoma (H&E, 10x)

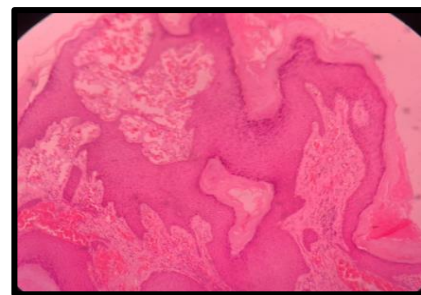


Figure 5: Photograph of Angiokeratoma (H&E, 10x)

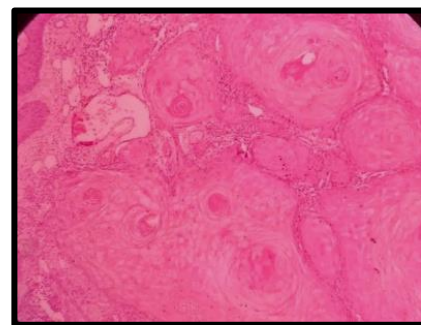


Figure 6: Photomicrograph showing neoplastic squamous cells with keratin pearls; Squamous cell carcinoma (H&E, 40X)

4. Discussion

Skin lesions are heterogeneous with a wide clinical and histopathological spectrum. [5]. The pattern of skin diseases are variable depending on economy, education level, variation in climate, primary healthcare facilities, industrialization and variation in religious and cultural factors. [6] Its very challenging to diagnose a skin lesion just on the basis of clinical findings. Many studies have shown histopathological examination as a gold standard for diagnosing skin lesions [7, 8].

Skin biopsy is simple and cost effective procedure. Present study includes 227 cases, maximum cases belonged to age group 20 - 30 years (23%) followed by 31 - 40 years (21%). This is in concordance with Indian studies, one of which has 23.75% patients and other has 24% patients in the same age group. [9, 10].

Our study showed male predominance with male to female ratio of 1.76: 1, which was in concordance with other studies [11 - 12]. Most common age group affected by infectious diseases was 21 - 30 years. Most common age group affected by neoplastic diseases was 51 - 60 years.

Inflammatory skin lesions were the most common 149 cases (65%) followed by infectious skin diseases 47 cases (20.7%) and least being neoplastic category with 9.2% of malignant tumors and 4 % of benign tumors.

Squamous cell carcinoma is the most common malignant skin lesion (14 out of 21) noted in our study which is in concordance with few other studies [13, 14, 15] which also showed squamous cell carcinoma as the most common malignant skin lesion

Histopathological figures (fig 1 - 6) have been described. Similar results depicted in a study of 258 skin biopsies from South India [16] which showed 91.08% nonneoplastic cases and 8.91% neoplastic cases, but 34.79% of the cases were malignant and 65.21% were benign.

Inflammatory lesions are the most common skin lesion with 149 cases. Miscellaneous cases included sweet syndrome, morphea, ashy dermatosis, calcinosis cutis, blaschkitis, keratoderma.

On review of literature from all over India, few similar studies were reported in the last decade. (Table 4)

Table 4: Review of Literature

Author Name/ Year	Place	Most Common Diagnosis	Most Common Disease Group	NEOPLASTIC	
				Benign	Malignant
Mamatha K et al 2018 [2]	Karnataka	Leprosy (31%)	Granulomatous lesions (54%)		
Bezbaruah R 2018 [16]	Assam	Epidermal cyst (26%)	Neoplastic lesions (81%)	61%	20%
Yalla ASD 2019 [3]	Vijayawada	Leprosy (33%)	Infectious (33%)	0	0
Kafle et al 2020 [17]	Birat, Nepal		Infectious (24%)	10%	5%
George et al 2020 [18]	Pondicherry	Leprosy (10%)	Inflammatory (59%)	63%	37%
Deepthi et al 2020 [12]	Telangana	Epidermal cyst (41%)	Cutaneous cysts (41%)	22%	16%
Chandrakanta et al 2022 [5]	Agra	Psoriasis (10%)	Noninfectious papulo squamous (24%)	77%	23%
Our study 2023	Bangalore	Papulo squamous (27%)	Inflammatory lesions (65%)	4%	9%

5. Conclusion

- The present study has shown the histopathological spectrum of various skin lesions in our tertiary care center. The major cases of skin lesions requiring biopsy in developing countries is still psoriasis in noninfectious papulosquamous diseases group.
- A massive percentage still belongs to inflammatory lesions followed by infective lesions. Neoplastic lesions still comprises a very low percentage in India. Psoriasis was the most common skin lesion followed by Leprosy.

References

[1] Singh, Madhurima & Jalaly, Farah & Ashraf, Manal & Ali, Manal; Spectrum of Lesions in Skin Biopsy in a Tertiary Care Hospital. International Journal of Health and Clinical Research, 2021; 4 (11): 151 - 155.

[2] Mamatha K, Susmitha S, Vijayalaxmi SP, Sathyashree KV, Disha BS. Histopathological spectrum of dermatological lesions –An experience at tertiary care centre. IP Archives of Cytology and Histopathology Research.2018; 3 (2): 83 - 88.

[3] Yalla ASD, Kambala GM, Natta BR. Histopathological study of skin lesions by punch biopsy. IOSR Journal of Dental and Medical Sciences (IOSR - JDMS).2019; 18 (6): 25 - 30.

[4] Patel A and Raval N. Histopathological spectrum of skin lesion - 100 cases study report. Inter Journal of Clinical and Diagnostic Pathology.2020; 3 (4): 36 - 38.

[5] Chandrakanta, Pooja N, Lalit Kumar, et al., Evaluation of Histomorphological Spectrum of Skin Lesions at a Teaching Institute in Agra: A Cross - sectional Study. Journal of Clinical and Diagnostic Research.2022 Sep, Vol - 16 (9): EC10 - EC15

[6] Bharadwaj V, Sudhakar R, Srikanth Reddy K, Naidu SR. Histopathological spectrum of dermatological lesions - A retrospective study. J Evid Based Med Health.2020; 7 (25): 1198 - 02.

[7] Ahnlide and M. Bjellerup, “Accuracy of clinical skin tumor diagnosis in a dermatological setting, ” ActaDermatoVenereologica.2013; 93 (3): 305 - 308.

[8] FB Yap. “Dermatopathology of 400 skin biopsies from Sarawak, ” Indian Journal of Dermatology, Venereology and Leprology.2009; 75 (5): 518 - 519

[9] Reddy R, Krishna N. Histopathological spectrum of noninfectious erythematous, papulosquamous lesions. Asian Pac J Health Sci.2014; 1 (4S): 28–34.10. Yalla ASD, Kambala GM, Natta BR.

[10] Histopathological Study of Skin Lesions by Punch Biopsy. IOSR Journal of Dental and Medical Sciences (IOSR - JDMS) 2019; 18 (6): Ser.14: 25 - 3

[11] Azad S, Acharya S, Kudesia S et al. Spectrum of skin tumors in a tertiary care centre in Northern India. J Evol Med Dent Sci.2014; 3 (64): 14044 - 14050.

[12] Deepthi KN, Karamchedu S, Saritha G. Spectrum of neoplastic and nonneoplastic skin lesions: A histopathological institutional study. IP J Diagn Pathol Oncol.2020; 5 (1): 25 - 29

[13] Bansal M, Sharma HB, Kumar N et al. Spectrum of skin lesions including skin adnexal tumors in a North Indian

tertiary care hospital. IP Journal of Diagnostic Pathology and Oncology.2019; 4 (1): 67 - 71.

- [14] Azad S, Acharya S, Kudesia S et al. Spectrum of skin tumors in a tertiary care centre in Northern India. J Evol Med Dent Sci.2014; 3 (64): 14044 - 14050.
- [15] Gundall S, Kolekar R, Pai K et al. Histopathological study of skin tumors. Int J Healthcare Sci.2015; 2 (2): 155 - 163.
- [16] Bezbaruah R, Baruah M. Histopathological spectrum of skin lesions - A hospital based study. Indian Journal of Applied Research.2018; 8 (7): 51 - 52.
- [17] Kafle SU, Chaudhary D, Yamu S, Jha K. Diagnose significance of clinicopathological concordance in various spectrums of skin disorders. BJHS.2020; 5 (1) 11: 955 - 59
- [18] George VP, Sowmya S, Krishnan S. A histopathological study of skin biopsy specimens in a tertiary care hospital with a keynote on clinicopathological correlation. Annals Patho Lab Medicine.2020; 7 (1): A39 - 45.