

# Rare Case of Lymphoma Presenting as Axillary Swelling

Dr. A. K. Kalpana Devi<sup>1</sup>, Dr. Vimala Gopalan<sup>2</sup>, Dr. Vijeyachandhar<sup>3</sup>

<sup>1</sup>Associate Professor, Institute of General Surgery, Madras Medical College, Chennai, Tamil Nadu, India  
Email: mithresh1999[at]gmail.com

<sup>2</sup>Assistant Professor, Institute of General Surgery, Madras Medical College, Chennai, Tamil Nadu, India

<sup>3</sup>Resident, Institute of General Surgery, Madras Medical College, Chennai, Tamil Nadu, India  
Email: drvijeypsg[at]gmail.com

**Abstract:** *The clinical presentation of Hodgkins Lymphoma as unilateral painless with no other swelling elsewhere in the body is rare. Most common presentations of hodgekins lymphoma are weight loss , neck swelling and night sweats. But in this scenario patient presented with painless unilateral axillary swelling. This study aims to present a detailed case report on the infrequent occurrence of Hodgkins Lymphoma presenting as axillary swelling. The objectives are to describe the clinical presentation, diagnostic challenges, surgical intervention, postoperative management, and to review relevant literature to highlight the complexity and rarity of this case.*

**Keywords:** Hodgkins Lymphoma, axillary swelling

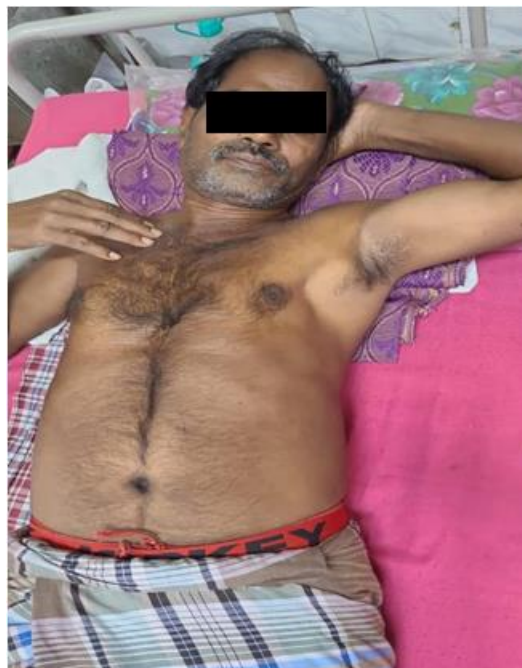## 1. Introduction

Hodgkins lymphoma (HL) is a unique hematopoietic neoplasm characterized by cancerous Reed-Sternberg cells in an inflammatory background. Patients are commonly diagnosed with HL in their 20s and 30s, and they present with supradiaphragmatic lymphadenopathy, often with systemic B symptoms. Even in advanced-stage disease, HL is highly curable with combination chemotherapy, radiation, or combined-modality treatment.

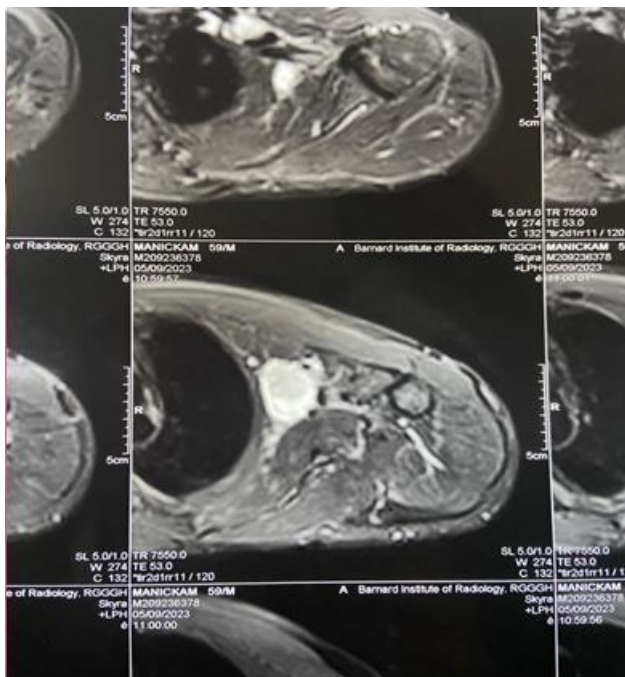
## 2. Case Report

A 58-year-old male patient came with the complaint of swelling in left axilla for 6 months, which increased in size in the past 6 months associated with 2 episodes of fever, chills 1 month ago. No pain or reduced range of motion of shoulder joint. No other aggravating or relieving factors. No history of trauma / pulmonary tuberculosis / and other malignancy / family history

Examination : single matted swelling of size 5\*4\*4cms, no skin changes, no dilated veins, smooth surface & with soft to firm in consistency noted with moderate mobility and non tender, no warmth. His vitals were within normal limits.



**Figure 1:** Showing left axillary swelling



**Figure 2:** MRI shows lymphoma / spindle cell tumor.

### Procedure

Patient was operated under general anesthesia and the swelling removed, intraoperatively the swelling was matted, tan color, not very vascular, adherent to surrounding soft tissues, solid.

### Histopathological Examination

Revealed Hodgkins Lymphoma with CD3, CD30, CD 20 Positive, PANCK & ALK- Negative.

### 3. Discussion

Hodgkin lymphoma encompasses a distinctive group of neoplasms that are characterized by the presence of a *tumor giant cell, the RS cell*. Unlike most NHLs, Hodgkin lymphomas arise in a single lymph node or chain of lymph nodes and typically spread in a stepwise fashion to anatomically contiguous nodes. Although the Hodgkin lymphomas are now understood to be unusual tumors of B cell origin, they are distinguished from the NHLs by their unusual pathologic and clinical features. Five subtypes of Hodgkin lymphoma are recognized: (1) nodular sclerosis, (2) mixed cellularity, (3) lymphocyte rich, (4) lymphocyte depletion, and (5) lymphocyte predominant. In the first four subtypes the RS cells share certain morphologic and immunophenotypic features.

In this case the patient presented in late 40's which is not in the epidemiological distribution age group presenting with complaint of painless swelling with one or 2 episodes fever and no other significant complaint history is masquerading radiologically as spindle cell tumor / lymphoma and clinically as infectious lymphadenopathy is a rare presentation of Hodgkins lymphoma